



Complications in orofacial harmonization procedures: a systematic review

Complicações em procedimentos de harmonização orofacial: uma revisão sistemática

NATHALIA LOPES MANGANARO¹
JULIA GABRIELA DIETRICHKEIT PEREIRA¹
RICARDO HENRIQUE ALVES DA SILVA^{1*}

■ ABSTRACT

Currently, facial aesthetic changes and dissatisfaction with self-image are influences that motivate the search for quick, non-surgical and less invasive cosmetic procedures. For this reason, the demand for patients looking for orofacial aesthetic procedures is increasing. The objective of this study was List the complications resulting from orofacial harmonization procedures through a systematic literature review, identifying which types of complications and areas are most affected. The following databases were searched: Medline (PubMed), SciELO, Scopus, Cochrane, Lilacs and Web of Science, from March to September 2020, selecting the studies that presented the following inclusion criteria: original studies in humans, about complications after orofacial harmonization procedures. Thirty-three studies from the literature were selected that presented reports of complications in patients after the orofacial harmonization procedure in the forehead, nose, eyes, periocular region and lips. Even the execution of less invasive facial cosmetic procedures can cause possible immediate or late complications after the procedure, especially in the periocular region and eyes. It is important to make professionals aware of this possibility beforehand.

Keywords: Esthetics; Rejuvenation; Face; Cosmetics/adverse effects; Hyaluronic acid; Skin aging.

■ RESUMO

Atualmente, as alterações estéticas faciais e a insatisfação com a autoimagem são influências que motivam a busca por procedimentos estéticos rápidos, não cirúrgicos e menos invasivos. Por esse motivo, a procura de pacientes que procuram por procedimentos estéticos orofaciais é crescente. O objetivo deste estudo foi elencar as complicações decorrentes dos procedimentos de harmonização orofacial por meio de uma revisão sistemática da literatura, identificando quais tipos de complicações e áreas são mais acometidas. As seguintes bases de dados foram pesquisadas: Medline (PubMed), SciELO, Scopus, Cochrane, Lilacs e Web of Science, de março a setembro de 2020, selecionando os estudos que apresentavam os seguintes critérios de inclusão: estudos originais em humanos sobre complicações após procedimentos de harmonização orofacial. Foram selecionados 33 estudos da literatura que apresentavam relatos de complicações em pacientes após o procedimento de harmonização orofacial na testa, nariz, olhos, região periocular e lábios. Mesmo a execução de procedimentos estéticos faciais menos invasivos pode acarretar possíveis complicações imediatas ou tardias após o procedimento, principalmente na região periocular e nos olhos. É importante alertar previamente os profissionais para essa possibilidade.

Descritores: Estética; Rejuvenescimento; Face; Cosméticos/efeitos adversos; Ácido hialurônico; Envelhecimento da pele.

Institution: Universidade de São Paulo, Faculdade de Odontologia de Ribeirão Preto, Departamento de Estomatologia, Saúde Coletiva e Odontologia Legal, Ribeirão Preto, SP, Brazil.

Article received: May 5, 2021.
Article accepted: July 14, 2021.

Conflicts of interest: none.

DOI: 10.5935/2177-1235.2022RBCP0034-en

INTRODUCTION

Facial aesthetic changes and dissatisfaction with self-image are increasingly present in today's society¹⁻³ and facial beauty parameters have a considerable

influence on the population^{2,4}. The appearance, especially of the female figure, is mentioned beauty and youth' imposing a cosmetic standard that fights fatigue and aging⁵. Patients have been looking for quick, non-surgical and less invasive procedures' where we can

¹ Universidade de São Paulo, Ribeirão Preto, SP, Brazil.



find some substances that can modify facial aesthetics through the rejuvenation of signs of aging⁶. Thus, there is an increase in the demand for patients looking for orofacial aesthetic procedures performed by doctors and dentists^{7,8}.

Facial applicators and fillers are the most widely used non-surgical resources for cosmetic procedures that seek to prevent or adjust the signs of aging⁹ through substances injected under the skin, which, although are effective and have favorable safety margins, early and late complications with various levels of severity can occur⁹. The increase in the performance of these dermal aesthetic procedures may be accompanied by factors that compromise patient safety and the reputation of professionals¹⁰.

In view of the consolidated medical practice in the cosmetic area and with the possibility of clinical practice by dentists on certain cosmetic factors¹¹, the popularity and demand for patients by these professionals increases with the main objective of aesthetic facial procedures¹². Although non-surgical, and with a safety margin, they can result in a strange or artificial appearance¹³, in addition to leading to complications and adverse effects after treatment¹⁴, causing damage to the patient¹⁵. It is of outmost importance that the professional is safe in making decisions when performing such procedures and attention to the limit of his attributions as a dentist¹⁶.

As a result of the increase in non-surgical aesthetic procedures, and aiming to alert professionals about possible damages and risks inherent to the technique, the objective of this systematic literature review was to list the complications resulting from orofacial harmonization procedures, identifying the most affected areas, contributing to conscious decision making and safer facial aesthetic procedures for the quality of life of the patient.

METHODS

Systematic review of the literature

Search strategy

This systematic review was conducted in accordance with the guidelines of the PRISMA protocol¹⁷, with the focus question: "What are the complications resulting from orofacial harmonization procedures?". The articles were selected based on the inclusion criteria: population, intervention, comparison and outcomes (PICO) which are shown in Chart 1.

The bibliographic search was carried out by two reviewers from March to September 2020, without

Chart 1. Criteria for the research focus question.

Description	Abbreviation	Components
Population	P	Humans
Intervention	I	Orofacial harmonization
Comparison	C	Aesthetic procedures
Outcomes	O	Complications

the use of filters, and the search was performed in all fields of the six selected databases: Medline (PubMed), SciELO, Scopus, Cochrane, Lilacs and Web of Science, in Portuguese, English and Spanish, using the following keywords.

English

- 1) "Botulinum toxin" and face and complications and "adverse effects"
- 2) "Hyaluronic acid" and face and complications and "adverse effects"
- 3) "Mesotherapy" and face and complications and "adverse effects"
- 4) "Collagen" and face and complications and "adverse effects"
- 5) "Lip" and face and complications and "adverse effects"
- 6) "Adipose tissue" and face and complications and "adverse effects"
- 7) "Laser" and face and complications and "adverse effects"
- 8) "Platelet-Rich Plasma" and face and complications and "adverse effects"

Portuguese

- 1) "Toxina botulínica" and face and complicações and "efeitos adversos"
- 2) "Ácido hialurônico" and face and complicações and "efeitos adversos"
- 3) "Mesoterapia" and face and complicações and "efeitos adversos"
- 4) "Colágeno" and face and complicações and "efeitos adversos"
- 5) "Lábio" and face and complicações and "efeitos adversos"
- 6) "Lipectomia" and face and complicações and "efeitos adversos"
- 7) "Laser" and face and complicações and "efeitos adversos"
- 8) "Plasma rico em plaquetas" and face and complicações and "efeitos adversos"

Spanish

- 1) "Toxinas Botulínicas" and cara and complicaciones and "efectos adversos"
- 2) "Ácido Hialurónico" and cara and complicaciones and "efectos adversos"

- 3) “Mesoterapia” and cara and complicaciones and “efectos adversos”
- 4) “Colágeno” and cara and complicaciones and “efectos adversos”
- 5) “Labio” and cara and complicaciones and “efectos adversos”
- 6) Lipectomia and cara and complicaciones and “efectos adversos”
- 7) “Rayos láser” and cara and complicaciones and “efectos adversos”
- 8) “Plasma rico en plaquetas” and cara and complicaciones and “efectos adversos”

Eligibility criteria

The articles were initially separated by titles, where those that did not have the topic were initially excluded. The articles selected by titles were evaluated by the reviewers through their abstracts and papers that did not meet the inclusion criteria and the repetitions found were discarded. Subsequently, a full article evaluation was carried out, where the methodological quality of each study was independently assessed by the two reviewers and the systematic selection of the studies was carried out, only those that presented the parameters of the inclusion criteria were selected for the discussion of the work.

Inclusion criteria were studies that presented complications in facial harmonization after orofacial harmonization procedures, in vivo work in humans. Exclusion criteria were literature reviews; research carried out on animals or that did not present complications resulting from orofacial harmonization procedures in the medical and dental areas.

Assessment the study quality

The bias classification of each selected study was performed using the scale: Joanna Briggs Institute 2017- Critical Appraisal Checklist for Case Reports¹⁸, with a maximum score of 8 points, counting only the positive ones, showing the limitations of the studies.

RESULTS

Literature search

Initially 3,535 references were chosen, applying the inclusion and exclusion criteria and removing as duplicates, a final sample of 33 studies was obtained in Chart 2. A detailed description of the stages of article selection is shown in Figure 1.

Chart 2. General data of the articles used in the systematic review containing the name of the article, authors, year of publication and journal.

ARTICLES	TITLE	AUTHORS	YEAR	MAGAZINE
1	Complications with the Use of Botulinum Toxin Type A in Facial Rejuvenation: Report of 8 Cases ¹⁹	Ferreira MC, Salles AG, Gimenez R, Soares MFD	2004	Aesthetic Plastic Surgery
2	Retinal branch artery occlusion following injection of hyaluronic acid (Restylane) ²⁰	Pedro S, Mennel S	2006	Clinical and Experimental Ophthalmology
3	Surgery for foreign body reactions due to injectable fillers ²¹	Wolfram D, Tzankov A, Piza-Katzer H	2006	Dermatology (Basel, Switzerland)
4	Effect of botulinum toxin type a on tear production after treatment of lateral canthal rhytids ²²	Arat YO, Yen MT	2007	Ophthalmic Plastic and Reconstructive Surgery
5	Delayed immune-mediated adverse effects related to hyaluronic acid and acrylic hydrogel dermal fillers: Clinical findings, long-term follow-up and review of the literature ²³	Alijotas-Reig J, Garcia GV	2008	Journal of the European Academy of Dermatology and Venereology
6	The risk of alar necrosis associated with dermal filler injection ²⁴	Grunebaum LD et.al.	2009	Dermatologic surgery
7	Ocular damage secondary to intense pulse light therapy to the face ²⁵	Lee WW et al.	2011	Ophthalmic plastic and reconstructive surgery

continue...

...continuation

Chart 2. General data of the articles used in the systematic review containing the name of the article, authors, year of publication and journal.

ARTICLES	TITLE	AUTHORS	YEAR	MAGAZINE
8	Exaggeration of wrinkles after botulinum toxin injection for forehead horizontal lines ²⁶	Kang SM et al.	2011	Annals of Dermatology
9	Uncommon Foreign Body Reaction Caused by Botulinum Toxin ²⁷	Pontes HAR et al.	2012	The Journal of Craniofacial Surgery
10	Facial blanching due to neurotoxins: proposed mechanisms ²⁸	Khan TT, Herne K, Dayan SH, Woodward JA	2013	Dermatologic surgery
11	The use of hyaluronidase in complications caused by hyaluronic acid for volumization of the face: a case report ²⁹	Neri SRNG, Addor FAZ, Parada MB, Schalka S	2013	Surgery cosmetic dermatology
12	Fundus artery occlusion caused by cosmetic facial injections ³⁰	Chen Y et al.	2014	Chinese medical journal
13	Periorbital lipogranuloma related to filler migration: A rare complication of facial filler ³¹	Eun YS, Cho SH, Lee JD, Kim HS	2014	Journal of Cosmetic and Laser Therapy
14	Diagnosis and management of dermal filler complications in the perioral region ³²	Grippaudo FR et al.	2014	Journal of cosmetic and laser therapy
15	Cosmetic facial fillers and severe vision loss ³³	Carle MV, Roe R, Novack R, Boyer DS	2014	JAMA ophthalmology
16	Clinical Outcomes of Impending Nasal Skin Necrosis Related to Nose and Nasolabial Fold Augmentation with Hyaluronic Acid Fillers ³⁴	Sun ZS et al.	2015	Plastic and reconstructive surgery
17	Late-onset adverse reactions related to hyaluronic acid dermal filler for aesthetic soft tissue augmentation ³⁵	Curi MM et al.	2015	The Journal of craniofacial surgery
18	Cerebral angiographic findings of cosmetic facial filler-related ophthalmic and retinal artery occlusion ³⁶	Kim YK, Jung C, Woo SJ, Park KH	2015	Journal of Korean Medical Science
19	Treatment of glabella skin necrosis following injection of hyaluronic acid filler using platelet-rich plasma ³⁷	Kang BK, Kang IJ, Jeong KH, Shin MK.	2016	Journal of cosmetic and laser therapy
20	Retinal Branch Artery Embolization Following Hyaluronic Acid Injection: A Case Report ³⁸	Chen W et al.	2016	Aesthetic surgery journal
21	Therapeutic Plasma Exchange in a rare case myasthenic crisis after Botox injection ³⁹	Chegini A	2017	Atherosclerosis Supplements
22	Filler migration to the forehead due to multiple filler injections in a patient addicted to cosmetic fillers ⁴⁰	Lin CH, Chiang CP, Wu BY, Gao HW	2017	Journal of cosmetic and laser therapy
23	Xanthelasma-Like Reaction to Filler Injection ⁴¹	Or L et al.	2017	Ophthalmic plastic and reconstructive surgery
24	Chronic Eyelid Edema Following Periocular Hyaluronic Acid Filler Treatment ⁴²	Yu JTS, Peng L, Atallah S	2017	Ophthalmic plastic and reconstructive surgery
25	[Clinical analysis of visual loss caused by facial cosmetic fillers injection] ⁴³	Hu XZ et al.	2017	Zhonghua yan ke za zhi Chinese journal of ophthalmology

continue...

...continuation

Chart 2. General data of the articles used in the systematic review containing the name of the article, authors, year of publication and journal.

ARTICLES	TITLE	AUTHORS	YEAR	MAGAZINE
26	A Histopathologic Diagnosis of Vascular Occlusion after Injection of Hyaluronic Acid Filler: Findings of Intravascular Foreign Body and Skin Necrosis ⁴⁴	Maruyama S	2017	Aesthetic Surgery Journal
27	Esotropia following botulinum toxin type A injection for facial wrinkles ⁴⁵	Lee SK, Jun HJ	2018	Journal of cosmetic and laser therapy
28	Vascular Complications After Chin Augmentation Using Hyaluronic Acid ⁴⁶	Wang Q et al.	2018	Aesthetic plastic surgery
29	Complications from microfocused transcutaneous ultrasound: Case series and review of the literature ⁴⁷	Friedmann DP et. al.	2018	Lasers in surgery and medicine
30	Ischemic oculomotor nerve palsy due to hyaluronic acid filler injection ⁴⁸	Bae IH et al.	2018	Journal of cosmetic dermatology
31	Horizontal animation deformity as unusual complication of neurotoxin modulation of the gummy smile ⁴⁹	Chen G et al.	2019	Dermatology online journal
32	Visual loss following cosmetic facial filler injection ⁵⁰	Shoughy SS	2019	Arquivos brasileiros de oftalmologia
33	Vascular Compromise After Soft TissueFacial Fillers: Case Report and Reviewof Current Treatment Protocols ⁵¹	SM, Goldsmith JL, Ferneini EM	2020	Journal of Oral and Maxillofacial Surgery

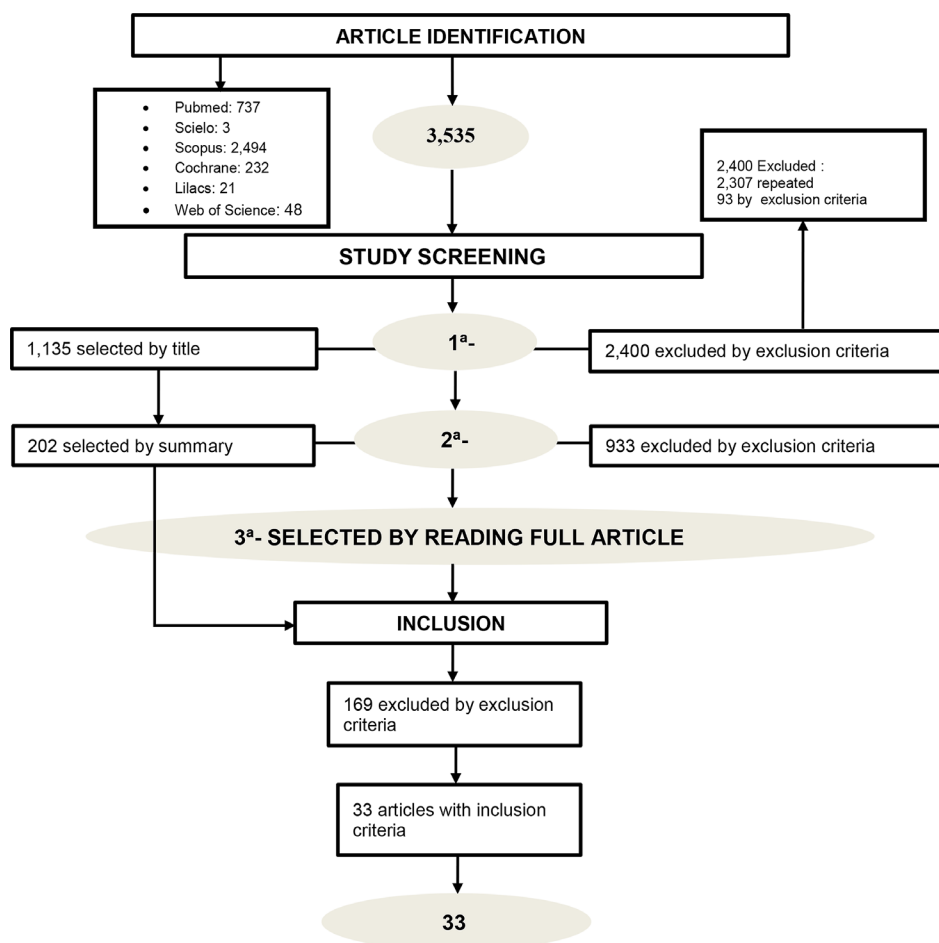


Figure 1. Flowchart of the selection process of the articles found in the databases.

The cases within each study ranged from 1 to 26, with ages ranging from 22 to 74 years. The facial aesthetic procedures performed were botulinum toxin injection procedures^{19,22,25-28,39,45,49}, filling with hyaluronic acid^{20,21,23,24,29,30,32-38,41-44,46,48,50,51} and other types of fillers^{29,41,44,48}, facial treatment with intense pulsed light (IPL)²⁵ and microneedled ultrasound⁴⁷, there were immediate and late complications resulting from the procedures, with the eyes and the periocular region being the most affected (Table 1). The methodological quality assessment score varied between 4 and 8 points, since the score counted only with the positive symbol (Table 2).

DISCUSSION

The demand for an improvement in aesthetics has increased the number of facial cosmetic procedures performed⁵². In view of this, this study carried out an extensive analysis of possible complications after orofacial harmonization procedures so that patients and professionals are aware of these events, enabling the detection and immediate treatment.

Most of the adverse effects are non-significant and temporary, but in some exceptions they can cause a worsening of the patient's aesthetic aspect and dissatisfaction⁵³, causing damage and/or psychological shock in the face of frustration with their appearance, which can lead to the repair of the damage by civil liability professional⁵⁴. However, even with a greater frequency of performing these services, there is still little scientific literary approach on the possible complications resulting from these procedures.

In this study, complications were reported in patients of both sexes, aged between 22 and 74; however, they were more frequent in women who performed most of the procedures^{22,34}. These procedures are motivated by the search for rejuvenation or prevention of facial aging¹³. For this reason, less invasive procedures have reached greater popularity and demand⁹. Of these procedures, facial applicators such as botulinum toxin^{19,22,25-28,39,45,49} and hyaluronic acid^{20,21,23,24,29,30,32-38,41-44,46,48,50,51} were the most performed, probably due to the cost benefit and durability of the effect. Lower eyelids and wrinkles "crow's feet", (popularly known expression) and nose^{28,30,32,34,36,38,39,41,44-46,49-53,55,56}. There were manifestations of complications after the procedures in the areas of the forehead, nose, eyes, periocular region and lips^{27-30,32-34,36-39,41,42,44-53,55,56}, being the eyes and periocular region the most affected mainly with dry eye, diplopia, visual loss and ptosis^{1-4,7,12,13,15,18,20,21,23-25,27,32}.

Consequences have been reported such as severe headache 45 lasting days, bilateral parietal headache

lasting fifteen days associated with dry eye, progressive forehead ptosis, diplopia and loss of muscle control²⁴. In the eyes, one of the most affected regions, it was possible to observe signs and symptoms such as dry eye^{19,22} after one month of the procedure, the symptoms remaining for four months²², eye pain with pupillary constriction and visual disturbances that resulted in permanent pupil defects even after two months after the event²⁵, vascular problems such as occlusion of the ophthalmic artery (OAO) and anterior ophthalmic optic neuropathy (AION) have also been reported³⁰. Visual loss occurred partially, with increased visual acuity after twenty-four hours²⁰ and prolonged visual loss even after one year of the complication report³³, the absence of light perception, esotropia⁴⁵, strabismus and ischemic oculomotor nerve paralysis secondary to an occlusion vascular obstruction of an arterial branch filled with hyaluronic acid also occurred³⁸.

Blepharoptosis⁴⁸, cutaneous necrosis, edema, yellow discoloration³¹, reactions similar to xanthelasma have been reported on the lower eyelids⁴¹ and a slight blue discoloration of the skin was observed even after six years of the most recent procedure⁴². In the regions of the glabella and forehead, where aging wrinkles are very evident, glabellar protrusion and the appearance of new very deep wrinkles occurred, in the glabellar protrusion there was a relapse with disappearance after four weeks²⁶, pale areas, redness, swelling, severe pain, purple and skin necrosis⁴⁴. There was a report of filling material applied to cheeks that migrated to the patient's forehead, forming a nodule that was resolved only with plastic surgery⁴⁵. Changes in the skin at the procedure site ranged from blisters, erosion and subcutaneous necrosis after treatment with microneedled ultrasound (MFUS)⁴⁷, facial edema and bruising after facial applicators⁵¹.

In the nose region, especially after filling procedure using hyaluronic acid, there were cases of nasal necrosis^{24,34,37,38}, with initial symptoms of swelling, edema, pain and erythema³⁴, dark color³⁷ and numbness. Cosmetic rhinomodulation procedures end up being a non-invasive cosmetic alternative to alter the nasal appearance. There were reports of two patients who recovered after appropriate treatments for necrosis of the nasal tissue, but in one case the patient had a permanent scar resulting from the complication²⁴. In the lower third of the face, the nasopalatine duct cyst was observed, caused by the foreign body reaction, that is, the material injected with botulinum toxin³², pain, and a 3cm nodule occurred in the region of zygomatic arch after application in the region with hyaluronic acid²⁹.

Necrosis in the chin region associated with lingual paresthesia was detected after filling with

Table 1. Methodology of studies that present complications after orofacial harmonization.

Article	n	F	M	Age	Procedure performed	Material intensity / quantity	Time elapsed from the procedure	Complications	Affected region
1	8	7	1	36-58	Injection of botulinum toxin type A in the upper and lower facial third	46 U; 10 U.	It ranged from 48 hours to 43 days.	Headache, dry eye, progressive unilateral ptosis of the forehead and eyelid associated with diplopia, loss of control of the orbicularis oris muscle, difficulty in drinking and speaking, edema, spasms of the eye and corrugator muscles and diplopia to a greater degree.	Facial muscles, eyes, eyelids, forehead and head
2	1	0	1	48	Filling hyaluronic acid in the glabellar area and eyelids for wrinkles	-	1 minute	Partial visual loss in the lower half of the visual field of the right eye and occlusion of the retinal branch artery.	Eyes
3	4	4	0	38-58	Facial fillers with polymethylmethacrylate microspheres, hyaluronic acid, hyaluronic acid plus acrylic hydrogel particles and polyactic acid	-	It ranged from 2 and 3 months to 2 years later.	Vesicular rashes on the face, granulomas, erythema, foreign body with subcutaneous and intramuscular stiffness, acute inflammation of the enlarged facial areas and also a fistula on the forehead.	Eyelids, corner of mouth, zygomatic arch, nasolabial folds, chin, neck, cheeks and upper lip.
4	13	13	0	31-58	Botulinum toxin type A in "crow's feet" region	10 U for each side	1 week	Dry eye and effects on the production of tears.	Eyes
5	25	-	-	-	Facial filling with hyaluronic acid (n=16) and hyaluronic acid plus hydrogels (n=9)	-	1-12 months	Sensitive nodules, skin tightening, systemic manifestations and other clinical signs.	Orofacial and systemic
6	3	2	1	25-42	Nose filling (rhinoplasty) with hyaluronic acid	1 ml (n=1)	Ranged from Immediate; 12 hours after and 1 day after.	Nasal necrosis, irritation of the skin of the nose with swelling and numbness.	Nose
7	2	2	0	27-36	Facial treatment with intense pulsed light (IPL)	560 nm with an unknown IPL unit was	1 hour after	Eye pain, marked pupillary constriction and anterior	Eyes
8	4	4	0	33-49	Botulinum toxin in the forehead region	Less than 20 U	1-2 weeks after	Glabellar protrusion and deep wrinkles	Forehead
9	1	1	0	32	Botulinum toxin injection to correct gingival smile	(3 BTX injections in 2 locations)	6 months later	Nasopalatine duct cyst or lateral periodontal cyst and foreign body immersed in connective tissue of the lesion compatible with botulinum toxin.	Maxilla and central incisors

continue...

...continuation

Table 1. Methodology of studies that present complications after orofacial harmonization.

Article	n	F	M	Age	Procedure performed	Material intensity / quantity	Time elapsed from the procedure	Complications	Affected region
10	1	1	0	32	Injections of botulinum toxin type A in the glabella region	-	2 weeks	Pale skin overlying the frontal and glabellar areas	Forehead
11	1	1	0	35	Hyaluronic acid in the region of the zygomatic arch	18G cannula, 70mm and volume not informed	15 days after	Pain on palpation and nodules	Zygomatic arch and infra-orbital region
12	13	13	0	38-44	Facial filling with autologous fat (n=7), hyaluronic acid (n=5) and bone collagen (n=1). Frontal (n=5), periocular (n=2), temporal (n=2) and nose (n=4)	HA (0.6; 0.9 and 2.1 ml of material. Needle 27-30 G) and autologous fat: (20.0;2.0;5.0;12.0 and 0.9ml with a needle of 0,3; 1; 1,2 and 2mm in diameter and 23 G and 12G)	-	Ophthalmic artery occlusion (OAO), central retinal artery occlusion (CRAO) and anterior ischemic optic neuropathy (AION).	Eyes
13	1	1	0	74	Dermal filling with unidentified material in the forehead region	-	-	Edema and yellow discoloration of the left upper eyelid	Eyelids
14	26	26	0	28-74	Lip filling	-	-	lip volume, asymmetry, lip edema, infections, fibrosis, lumps, labial hardening, granulomatous inflammation and product migration.	Lips
15	3	2	1	30-60	Hyaluronic acid, autologous fat and microspheres of bovine collagen and polymethyl methyl acrylate on the forehead	-	Ranged from immediately to 3 weeks after	Visual Loss	Eyes
16	20	19	1	22-52	Hyaluronic acid in the Nose	-	1 day after	Cutaneous necrosis (pain, erythema and edema)	Nose
17	2	2	0	58-65	Hyaluronic acid	-	4 e 12 years later (late reaction)	Painful inflamed nodular lesions on the lip mucosa and sudden symmetrical bilateral swelling in the masseter region	Lips and masseter
18	7	7	0	24-40	Hyaluronic acid (n=4) and autologous fat (n=3) in nose and glabella	AH 0.2; 0.4 and 0.7 ml for autologous fat was not identified	4 hours	Ophthalmic artery occlusion (OAO) and skin necrosis	Eyes

continue...

...continuation

Table 1. Methodology of studies that present complications after orofacial harmonization.

Article	n	F	M	Age	Procedure performed	Material intensity / quantity	Time elapsed from the procedure	Complications	Affected region
19	1	1	0	46	Hyaluronic acid in the forehead and nose	-	2 days after	Redness, swelling, numerous pustules and dark regional necrosis.	Glabella, forehead and back of nose
20	1	1	0	22	Hyaluronic acid injection in the nasal dorsus	-	10 minutes after	Nasal back and erythematous glabella accompanied by diplopia, violet discoloration, orbital pain and extrabismus in the eyes.	Glabella, nose and eyes
21	1	1	0	30	A botulinum toxin injections	3 injections without volume indication	-	Ptosis, diplopia, dysarthria, dysphagia, muscle weakness, progressive breathing difficulty and dyspnea	Eyes and pharynx
22	1	1	0	50	Poly-lactic acid injection (PLLA) in the cheeks	-	1 month after	Fill migration in the cheeks forming a growing nodule on the forehead	Forehead
23	7	7	0	46-57	Hyaluronic acid (n=2), synthetic calcium hydroxyapatite (n=4) and polycaprolactone microspheres (n=1)	-	12 months after	Reaction similar to xanthelasma on the lower eyelids that included swelling and yellow deposits on the lower eyelids	Lower eyelids
24	1	1	0	54	Hyaluronic acid in the eyebrow region	-	6 years after	Bilateral periorbital edema with slight blue discoloration of the skin.	Eyelids
25	18	18	0	24-45	Hyaluronic acid or autologous fat: test n=6; nose n=8; both n=4	-	-	Visual loss (absence of light perception, ischemia at the injection site, different degrees of ptosis and examination of the fundus)	Eyes
26	1	1	0	57	Hyaluronic acid in the glabella, forehead and nasolabial folds	0,1mL	2 days after	Skin necrosis, erythema, discoloration, purple, and severe pain that extends from the left glabella to the top of the forehead	Forehead, in the parietal region
27	1	1	0	36	Botulinum toxin type A on the glabella, forehead and crow's feet	-	7 days after	Esotropia partial paralysis of the eye (presented double vision)	Eyes
28	2	2	0	24-42	Hyaluronic acid (HA)	1ml	During the procedure	Local necrosis of the chin skin, lingual paresthesia, headache and neck discomfort.	Chin and Tongue

continue...

...continuation

Table 1. Methodology of studies that present complications after orofacial harmonization.

Article	n	F	M	Age	Procedure performed	Material intensity / quantity	Time elapsed from the procedure	Complications	Affected region
29	5	3	2	47-53	Microfocused ultrasound (MFUS) to improve facial skin texture	4MHz / 4.5mm, 3.0mm and 1.5mm (809 lines); 7 MHz / 4.5mm and 3.0mm (318 lines) and 4MHz / 4.5mm, 7MHz / 4.5mm and 3.0mm deep (630 lines)	Minutes after procedure	Blisters, erosion / ulceration, skin and subcutaneous tissue and skin necrosis.	Facial skin
30	1	1	0	29	Hyaluronic acid (HA) in the nasal tip	-	During the procedure and after 3 days.	Severe pain, dizziness and blurred vision, limited extraocular movement, skin.	Periocular area and glabella
31	1	1	0	28	Botulinum toxin type A on the upper lip	one site per muscle, 2.5 units per site	1 week after	Appearance of depressing horizontal line when smiling	Lower facial third
32	1	1	0	36	Periocular hyaluronic acid and glabella	-	-	Loss of vision in the right eye and weakness in the left arm	Eyes and arms
33	1	1	0	52	Hyaluronic acid (HA) in the puppet lines and nasolabial folds	-	12 hours after	Bilateral painful erythematous facial edema and palpable sensitive area with hematoma and edema	Lower third of the face and lip

F: Female; M: Male; n: number of patients.

Table 2. Risk of bias based on JBI TOOL of eligible studies and included in the systematic review.

Article	1. Were patient's demographic characteristics clearly described?	2. Was the patient's history clearly described and presented as a timeline?	3. Was the current clinical condition of the patient on presentation clearly described?	4. Were diagnostic tests or assessment methods and the results clearly described?	5. Was the intervention(s) or treatment procedure(s) clearly described?	6. Was the post-intervention clinical condition clearly described?	7. Were adverse events (harms) or unanticipated events identified and described?	8. Does the case report provide takeaway lessons?
1 ¹⁹	-	-	+	+	-	+	+	+
2 ²⁰	+	-	+	+	+	+	+	+
3 ²¹	+	-	+	+	-	+	+	+
4 ²²	-	-	+	+	+	+	+	+
5 ²³	-	-	+	+	+	+	+	+
6 ²⁴	+	+	+	+	+	+	+	+
7 ²⁵	-	-	+	+	-	+	+	+
8 ²⁶	-	-	+	+	-	+	+	+
9 ²⁷	-	+	+	+	+	+	+	+
10 ²⁸	+	-	+	+	-	+	+	+
11 ²⁹	-	-	+	+	+	+	+	+
12 ³⁰	+	-	+	+	+	+	+	+
13 ³¹	-	-	+	+	-	-	+	+
14 ³²	-	-	+	+	-	+	+	+
15 ³³	-	-	+	+	-	+	+	+
16 ³⁴	+	-	+	+	-	+	+	+
17 ³⁵	-	-	+	+	-	+	+	+
18 ³⁶	-	-	+	+	+	+	+	+
19 ³⁷	-	-	+	+	-	+	+	+
20 ³⁸	+	-	+	+	-	+	+	+
21 ³⁹	-	-	+	+	-	-	+	+
22 ⁴⁰	-	-	+	+	-	+	+	+
23 ⁴¹	-	+	+	+	-	+	+	+
24 ⁴²	+	+	+	+	-	+	+	+
25 ⁴³	-	-	+	+	-	+	+	+
26 ⁴⁴	-	-	+	+	+	+	+	+
27 ⁴⁵	-	-	+	+	-	+	+	+
28 ⁴⁶	-	-	+	+	-	+	+	+
29 ⁴⁷	+	-	+	+	+	+	+	+
30 ⁴⁸	-	-	+	+	-	+	+	+
31 ⁴⁹	-	-	+	+	+	+	+	+
32 ⁵⁰	-	+	+	+	-	+	+	+
33 ⁵¹	-	-	+	+	-	+	+	+

hyaluronic acid in the submental region, the ischemia of the tongue occurs by injecting material into the submental artery or its branches⁴⁶. Still in the lower region of the face, the appearance of a deep horizontal line that was highlighted when the patient smiled, due to the application of botulinum toxin to correct gingival smile, the complication disappeared only after the effect of botulinum toxin ceased in three months⁴⁹. A more serious complication caused breathing difficulties and dyspnea in a patient who required hospitalization and intubation for mechanical ventilation in an intensive care unit (ICU) diagnosed with myasthenia gravis, after a cosmetic procedure with botulinum toxin³⁹. In the procedures performed on the lips, it was common to observe asymmetry, infections, fibrosis, hardening of the lips²¹, migration of the material used³² and painful injuries³⁵. Systemic complications after the cosmetic procedure were also detected in a patient with no history of diseases, manifesting with fever, astralgia and arthritis²³.

The present study had several relevant limitations: the nationality of the studied patients, which was not clarified; the techniques of the procedures performed; quantity and brand of material used with its concentration; the professional's specialty was also not specified. Such information would bring greater wealth to the discussion since several professionals are able to perform such procedures, and their qualification would help to demonstrate to these classes how their care is being performed and the most common complications, in addition to detecting possible failures of execution in the procedure. The amount of material and the concentration would provide a greater explanation of why there are some complications and, consequently, try to reduce such occurrences.

Given the above, the importance of a detailed history of procedures performed by the patient is emphasized^{31,35}, before performing the facial cosmetic procedure, as well as the complete understanding of the facial and vascular anatomy by the professional^{27,43,48,50,51}. Which can be a contributing factor to the induction of complications related to the training and execution of procedures by the professional, with complications resulting from injection in the blood vessels, vascular lesions and occlusion, infections caused by contamination of the product and technical errors of the injection of the material⁵⁷.

It is evident the importance of ensuring the keeping of good photographic documentation and always maintaining a good relationship with the patient until the complication is resolved²⁴. It must be communicated to the patient that even though it is a simple and non-invasive procedure, complications can

occur^{20,22,26}. The professional must exercise preventive measures so that complications do not occur³⁸, respecting professional ethics and responsibility, ensuring the patient's health and dignity^{16,55}, such measures avoid suffering and irreparable losses that can cause damage. Damage caused to the patient resulting from treatments can characterize civil liability^{55,56,58}, as well as, criminal liability events can occur through bodily injury that offend the patient's bodily integrity or health⁵⁸⁻⁶⁰. Thus, the importance of carrying out extensive studies for the detailed understanding of the possible causes and mechanisms of these events is evident in order to guarantee safer and more satisfactory aesthetic procedures for the professional and the patient.

CONCLUSIONS

It is possible to conclude that even the execution of less invasive facial cosmetic procedures can cause possible immediate or late complications after the procedure in areas of forehead, nose, lips and mainly, in the eyes and periocular region, which were the most affected with dry eyes, diplopia, visual loss and ptosis. It is important to make patients aware of this possibility beforehand. Professionals must remain alert for the immediate detection of any complications.

COLLABORATIONS

NLM Analysis and/or data interpretation, Conception and design study, Conceptualization, Data Curation, Final manuscript approval, Formal Analysis, Funding Acquisition, Investigation, Methodology, Realization of operations and/or trials, Resources, Validation, Visualization, Writing - Original Draft Preparation, Writing - Review & Editing.

JGDP Analysis and/or data interpretation, Conception and design study, Conceptualization, Data Curation, Final manuscript approval, Funding Acquisition, Investigation, Methodology, Realization of operations and/or trials, Supervision, Validation.

RHAS Analysis and/or data interpretation, Project Administration, Supervision, Visualization, Writing - Review & Editing.

REFERENCES

1. Yesilbek B, Simsek S, Valério P. O impacto psicossocial da estética facial em crianças e adolescentes e a possibilidade de intervenções precoces: relato de dois casos clínicos. *Rev Assoc Paul Cir Dent.* 2016;70(2):192-7.

2. Gatto RCJ, Garbin AJI, Corrente JE, Garbin CAS. The relationship between oral health-related quality of life, the need for orthodontic treatment and bullying, among Brazilian teenagers. *Dental Press J Orthod.* 2019;24(2):73-80.
3. Garbin AJI, Wakaiama B, Saliba TA, Garbin CAS. Harmonização Orofacial e suas implicações na odontologia. *Braz J Surg Clin Res.* 2019;27(2):116-22.
4. Soares DM, Palmeira PTSS, Pereira VF, Santos MESM, Tassitano RM, Laureano Filho JR. Evaluation of the main criteria of facial profile aesthetics and attractiveness. *Rev Bras Cir Plást.* 2012;27(4):547-51.
5. Vilhena J, Medeiros S, Novaes JV. A violência da imagem: estética, feminino e contemporaneidade. *Rev Mal Estar Subj.* 2005;5(1):109-44.
6. de Maio M. The minimal approach: An innovation in facial cosmetic procedures. *Aesthetic Plast Surg.* 2004;28(5):295-300.
7. Machado MA, Flores MRP, Daruge Júnior E, Da Silva RHA. Procedimentos estéticos em Odontologia: orientações para uma prática clínica segura. *Rev Dental Press Estét.* 2014;11(2):90-7.
8. Pedron IG, Silva LPN. Utilização da toxina botulínica associada à cirurgia gengival ressectiva na estética dentogengival. *Rev Odontol Bras Central.* 2017;26(77):57-60.
9. Farolch-Prats L, Nome-Chamorro C. Facial Contouring by Using Dermal Fillers and Botulinum Toxin A: A Practical Approach. *Aesthetic Plast Surg.* 2019;43(3):793-802.
10. Heydenrych I, Kapoor KM, De Boule K, Goodman G, Swift A, Kumar N, et al. 10-point plan for avoiding hyaluronic acid dermal filler-related complications during facial aesthetic procedures and algorithms for management. *Clin Cosmet Investig Dermatol.* 2018;11:603-11.
11. Papazian MF, Silva LM, Crepaldi AA, Crepaldi MLS, Aguiar AP. Principais aspectos dos preenchedores faciais. *Rev Faiepe.* 2018;8(1):101-16.
12. Srivastava S, Kharbanda S, Pal US, Shah V. Applications of botulinum toxin in dentistry: A comprehensive review. *Natl J Maxillofac Surg.* 2015;6(2):152-9.
13. Fitzgerald R, Carqueville J, Yang PT. An approach to structural facial rejuvenation with fillers in women. *Int J Womens Dermatol.* 2018;5(1):52-67.
14. Zagui MRB, Matayoshi S, Moura FC. Efeitos adversos associados à aplicação de toxina botulínica na face: revisão sistemática com meta-análise. *Arq Bras Oftalmol.* 2008;71(6):894-901.
15. Brasil. Ministério da Saúde. Documento de referência para o Programa Nacional de Segurança do Paciente / Ministério da Saúde; Fundação Oswaldo Cruz; Agência Nacional de Vigilância Sanitária. [Internet]. Brasília: Ministério da Saúde; 2014. 40 p. Available from: http://bvsmms.saude.gov.br/bvsm/publicacoes/documento_referencia_programa_nacional_seguranca.pdf
16. Conselho Federal de Odontologia de São Paulo. Resolução N°118/2012, 11 de maio de 2012. Código de ética odontológico. [Internet]. São Paulo: Conselho Federal de Odontologia; 2012. Available from: <http://www.crosp.org.br/uploads/etica/6ac4d2e1ab8cf02b189238519d7fd45.pdf>
17. Moher D, Liberati A, Tetzlaff J, Altman DG; PRISMA Group. Preferred reporting items for systematic reviews and meta-analyses: the PRISMA statement. *PLoS Med.* 2009;6(7):e1000097.
18. The Joanna Briggs Institute. 2017. Critical Appraisal Checklist for Case Reports. [Internet]. [cited 2020 Mar 10]. Available from: https://jbi.global/sites/default/files/2019-05/JBI_Critical_Appraisal-Checklist_for_Case_Reports2017_0.pdf
19. Ferreira MC, Salles AG, Gimenez R, Soares MF. Complications with the use of botulinum toxin type a in facial rejuvenation: report of 8 cases. *Aesthetic Plast Surg.* 2004;28(6):441-4.
20. Peter S, Mennel S. Retinal branch artery occlusion following injection of hyaluronic acid (Restylane). *Clin Exp Ophthalmol.* 2006;34(4):363-4.
21. Wolfram D, Tzankov A, Piza-Katzer H. Surgery for foreign body reactions due to injectable fillers. *Dermatology.* 2006;213(4):300-4.
22. Arat YO, Yen MT. Effect of botulinum toxin type a on tear production after treatment of lateral canthal rhytids. *Ophthalmic Plast Reconstr Surg.* 2007;23(1):22-4.
23. Alijotas-Reig J, Garcia-Gimenez V. Delayed immune-mediated adverse effects related to hyaluronic acid and acrylic hydrogel dermal fillers: clinical findings, long-term follow-up and review of the literature. *J Eur Acad Dermatol Venereol.* 2008;22(2):150-61.
24. Grunebaum LD, Bogdan Allemann I, Dayan S, Mandy S, Baumann L. The risk of alar necrosis associated with dermal filler injection. *Dermatol Surg.* 2009;35 Suppl 2:1635-40.
25. Lee WW, Murdock J, Albini TA, O'Brien TP, Levine ML. Ocular damage secondary to intense pulse light therapy to the face. *Ophthalmic Plast Reconstr Surg.* 2011;27(4):263-5.
26. Kang SM, Feneran A, Kim JK, Park O, Kim JE, Won CH, et al. Exaggeration of wrinkles after botulinum toxin injection for forehead horizontal lines. *Ann Dermatol.* 2011;23(2):217-21.
27. Pontes HA, Pontes FS, de Oliveira GF, de Almeida HA, Guimarães DM, Cavallero FC. Uncommon foreign body reaction caused by botulinum toxin. *J Craniofac Surg.* 2012;23(4):e303-5.
28. Khan TT, Herne K, Dayan SH, Woodward JA. Facial blanching due to neurotoxins: proposed mechanisms. *Dermatol Surg.* 2013;39(1 Pt 1):24-9.
29. Neri SRNG, Addor FAS, Parada MB, Schalka S. The use of hyaluronidase in complications caused by hyaluronic acid for volumization of the face: a case report. *Surg Cosmet Dermatol.* 2013;5(4):364-6.
30. Chen Y, Wang W, Li J, Yu Y, Li L, Lu N. Fundus artery occlusion caused by cosmetic facial injections. *Chin Med J (Engl).* 2014;127(8):1434-7.
31. Eun YS, Cho SH, Lee JD, Kim HS. Periorbital lipogranuloma related to filler migration: a rare complication of facial fillers. *J Cosmet Laser Ther.* 2014;16(3):149-50.
32. Grippaudo FR, Di Girolamo M, Mattei M, Pucci E, Grippaudo C. Diagnosis and management of dermal filler complications in the perioral region. *J Cosmet Laser Ther.* 2014;16(5):246-52.
33. Carle MV, Roe R, Novack R, Boyer DS. Cosmetic facial fillers and severe vision loss. *JAMA Ophthalmol.* 2014;132(5):637-9.
34. Sun ZS, Zhu GZ, Wang HB, Xu X, Cai B, Zeng L, et al. Clinical Outcomes of Impending Nasal Skin Necrosis Related to Nose and Nasolabial Fold Augmentation with Hyaluronic Acid Fillers. *Plast Reconstr Surg.* 2015;136(4):434e-41e.
35. Curi MM, Cardoso CL, Curra C, Koga D, Benini MB. Late-onset adverse reactions related to hyaluronic Acid dermal filler for aesthetic soft tissue augmentation. *J Craniofac Surg.* 2015;26(3):782-4.
36. Kim YK, Jung C, Woo SJ, Park KH. Cerebral Angiographic Findings of Cosmetic Facial Filler-related Ophthalmic and Retinal Artery Occlusion. *J Korean Med Sci.* 2015;30(12):1847-55.
37. Kang BK, Kang IJ, Jeong KH, Shin MK. Treatment of glabella skin necrosis following injection of hyaluronic acid filler using platelet-rich plasma. *J Cosmet Laser Ther.* 2016;18(2):111-2.
38. Chen W, Wu L, Jian XL, Zhang B, Li JY, Qin XL, et al. Retinal Branch Artery Embolization Following Hyaluronic Acid Injection: A Case Report. *Aesthet Surg J.* 2016;36(7):NP219-24.
39. Chegini A. Therapeutic Plasma Exchange in a rare case myasthenic crisis after Botox injection. *Atheroscler Suppl.* 2017;30:283-5.
40. Lin CH, Chiang CP, Wu BY, Gao HW. Filler migration to the forehead due to multiple filler injections in a patient addicted to cosmetic fillers. *J Cosmet Laser Ther.* 2017;19(2):124-6.
41. Or L, Eviatar JA, Massry GG, Bernardini FP, Hartstein ME. Xanthelasma-Like Reaction to Filler Injection. *Ophthalmic Plast Reconstr Surg.* 2017;33(4):244-7.

42. Yu JTS, Peng L, Ataullah S. Chronic Eyelid Edema Following Periocular Hyaluronic Acid Filler Treatment. *Ophthalmic Plast Reconstr Surg.* 2017;33(6):e139-40.
43. Hu XZ, Chen SQ, Zhang Q, Wu PS, Lu W. Clinical analysis of visual loss caused by facial cosmetic fillers injection. *Zhonghua Yan Ke Za Zhi.* 2017;53(8):594-8.
44. Maruyama S. A Histopathologic Diagnosis of Vascular Occlusion After Injection of Hyaluronic Acid Filler: Findings of Intravascular Foreign Body and Skin Necrosis. *Aesthet Surg J.* 2017;37(9):NP102-8.
45. Lee SK, Jun HJ. Esotropia following botulinum toxin type A injection for facial wrinkles. *J Cosmet Laser Ther.* 2018;20(1):50-1.
46. Wang Q, Zhao Y, Li H, Li P, Wang J. Vascular Complications After Chin Augmentation Using Hyaluronic Acid. *Aesthetic Plast Surg.* 2018;42(2):553-9.
47. Friedmann DP, Bourgeois GP, Chan HHL, Zedlitz AC, Butterwick KJ. Complications from microfocused transcutaneous ultrasound: Case series and review of the literature. *Lasers Surg Med.* 2018;50(1):13-9.
48. Bae IH, Kim MS, Choi H, Na CH, Shin BS. Ischemic oculomotor nerve palsy due to hyaluronic acid filler injection. *J Cosmet Dermatol.* 2018;17(6):1016-8.
49. Chen G, Oranges CM, Giordano S, Huang R, Wang W. Horizontal animation deformity as unusual complication of neurotoxin modulation of the gummy smile. *Dermatol Online J.* 2019;25(8):13030/qt49s9h9zh.
50. Shouhgy SS. Visual loss following cosmetic facial filler injection. *Arq Bras Oftalmol.* 2019;82(6):511-3.
51. Halepas S, Peters SM, Goldsmith JL, Ferneini EM. Vascular Compromise After Soft Tissue Facial Fillers: Case Report and Review of Current Treatment Protocols. *J Oral Maxillofac Surg.* 2020;78(3):440-5.
52. Chitre S. Dental Sealant placement: A Comparison technique. In: 13th International Conference and Exhibition on Dental Medicine; 2016 Aug 8-10; Toronto, Canada.
53. Guzelce E, Bassi F, Karacer O. Restoring congenitally missing mandibular central incisor using lithium disilicate based resin bonded prostheses: a case report. *Oral Health Dental Sci.* 2018;2(2):1-3.
54. Oliveira TFL, Oliveira LSAF, Santos L, Mascarenhas C, Lopes N, Dantas P. Responsabilidade civil em odontologia - uma visão por profissionais da área jurídica. *Odontol Clín Cient.* 2013;12(4):261-4. Brasil. Conselho Federal de Medicina. Resolução N° 2.217/2018, 27 de setembro de 2018. Código de ética médica. [Internet]. Brasília: Conselho Federal de Medicina; 2018. Available from: <https://portal.cfm.org.br/images/PDF/cem2019.pdf>
56. Silva RHA, Musse JO, Melani RFH, Oliveira RN. Responsabilidade civil do cirurgião-dentista: a importância do assistente técnico. *Rev Dental Press Ortodon Ortop Facial.* 2009;14(6):65-71.
57. Gutmann IE, Dutra RT. Reações adversas associadas ao uso de preenchedores faciais com ácido hialurônico. *Rev Elet Bioc Biotec Saúde.* 2018;11(20):7-17.
58. Netto AL, Ruiz AM. Responsabilidade Médica. *Rev Bras Oftalmol.* 2010;69(2):75-6.
59. Lolli LF, Lolli MCGS, Marson FC, Silva CO, Moreira MA, Silva RHA. Responsabilidade criminal do cirurgião-dentista. *Acta Jus.* 2013;1(1):17-23.
60. Brasil. Presidência da República. Decreto-Lei N° 2.848/1940, 7 de dezembro de 1940. Código Penal- Artigo 129. Casa Civil. Subchefia para assuntos jurídicos. [Internet]. Rio de Janeiro: Presidência da República; 1940. Available from: http://www.planalto.gov.br/ccivil_03/decreto-lei/del2848.htm

***Corresponding author:** **Ricardo Henrique Alves da Silva**
Avenida do Café, s/n, Bairro Monte Alegre, Ribeirão Preto, SP, Brazil
Zip Code: 14040-904
E-mail: ricardohenrique@usp.br