

# Mastopexy with breast implants and the pectoralis major muscle flap: a technique adopted by the Department of Plastic Surgery of Unicamp

*Mastopexia com uso de implantes associados a retalho de músculo peitoral maior: técnica utilizada na Disciplina de Cirurgia Plástica da Unicamp*

ANDREA BOLDRIN SOARES<sup>1</sup>  
 FERNANDO FABRÍCIO FRANCO<sup>2</sup>  
 ENDRIGO TOREZAN ROSIM<sup>1</sup>  
 BRENDA ARTUZI RENÓ<sup>1</sup>  
 JUSSARA OLIVO PINHEIRO  
 ALVES HACHMANN<sup>3</sup>  
 MARCELO DE CAMPOS GUIDI<sup>3</sup>  
 MARCO ANTONIO DE  
 CAMARGO BUENO<sup>4</sup>  
 PAULO KHARMANDAYAN<sup>5</sup>

This study was conducted at the School of Medical Sciences of Universidade Estadual de Campinas (Unicamp), Campinas, SP, Brazil.

Submitted to SGP (Sistema de Gestão de Publicações/Manager Publications System) of RBCP (Revista Brasileira de Cirurgia Plástica/Brazilian Journal of Plastic Surgery).

Paper received: July 15, 2011  
 Paper accepted: October 31, 2011

## ABSTRACT

**Background:** The correction of breast ptosis associated with skin sagging and low projection is still a subject of controversy in the literature. This study aims to describe the experience of the Plastic Surgery Department of Universidade Estadual de Campinas (Unicamp) with the technique of mastopexy with breast implants in a double plane and the pectoralis major muscle flap. **Methods:** A retrospective study of 20 patients with grade II or III mammary ptosis, who underwent surgery between June 2008 and September 2010, was performed. **Results:** A 9- and 12-month follow-up of patients showed neither breast or chest deformities nor recurrence of ptosis. All patients presented with good breast projection and adequate upper pole fill, with long-lasting and satisfactory results. **Conclusions:** Mastopexy with breast implants and the pectoralis major muscle flap technique is easy to perform, with a relatively short learning curve, good reproducibility, and satisfactory long-lasting results.

**Keywords:** Mammoplasty. Breast/surgery. Breast implantation. Surgical flaps.

## RESUMO

**Introdução:** A correção da ptose mamária associada à flacidez de pele e baixa projeção é ainda tema de discussões e controvérsias na literatura. O objetivo deste estudo é descrever a experiência da Disciplina de Cirurgia Plástica da Universidade Estadual de Campinas (Unicamp) com a técnica de mastopexia com implante mamário associado a retalho de sustentação do músculo peitoral maior. **Método:** Foi realizado estudo retrospectivo de 20 pacientes com ptose mamária graus II ou III, operadas no período de junho de 2008 a setembro de 2010. **Resultados:** Após seguimento pós-operatório entre 9 meses e 12 meses, não foram observados casos de deformidades mamárias ou torácicas e nenhuma paciente evoluiu com recidiva da ptose. Foram observados, em todas as pacientes, manutenção de boa projeção da mama e adequado preenchimento do polo superior mamário, gerando resultados duradouros e satisfatórios. **Conclusões:** A técnica de mastopexia com uso de implantes associados a retalho de músculo peitoral maior é de fácil realização, com curva de aprendizado relativamente curta, boa reprodutibilidade, e resultados duradouros e satisfatórios.

**Descritores:** Mamoplastia. Mama/cirurgia. Implante mamário. Retalhos cirúrgicos.

1. Resident Physician of Plastic Surgery at Universidade Estadual de Campinas (Unicamp), Campinas, SP, Brazil.
2. Specialist Member of the Brazilian Society of Plastic Surgery (SBCP), Collaborator Physician of the Discipline of Plastic Surgery at Unicamp, Campinas, SP, Brazil.
3. Specialist Member of the Brazilian Society of Plastic Surgery (SBCP), Assistant Physician of the Discipline of Plastic Surgery at Unicamp, Campinas, SP, Brazil.
4. Specialist Member of the Brazilian Society of Plastic Surgery (SBCP), Associate Professor of the Discipline of Plastic Surgery at Unicamp, Campinas, SP, Brazil.
5. Full-time Member of the Brazilian Society of Plastic Surgery (SBCP), Professor Doctor and Head of the Discipline of Plastic Surgery at Unicamp, Campinas, SP, Brazil.

## INTRODUCTION

Breast ptosis is caused by an imbalance between the breast skin and its content. There are several degrees of breast ptosis according to the relationship between the nipple and the inframammary crease as classified by Regnault in 1976 (Chart 1)<sup>1,2</sup>.

The correction of breast ptosis associated with skin sagging and low projection of the breast is a subject of controversy. A critical review of the aesthetic results and the degree of satisfaction of patients and surgeons is not well established in the medical literature<sup>2-5</sup>.

Several studies have described the correction of breast ptosis by an increase in breast volume, removal of excess skin, or a combination of both<sup>2-5</sup>. In cases of massive weight loss, fat catabolism and connective tissue alterations lead to reduction in breast projection and increased sagging, generating an unsightly appearance<sup>6-10</sup>. The correction of these defects is very difficult for surgeons under training, and even for experienced surgeons, and different techniques have been described in the literature.

Techniques showing good reproducibility and a low rate of complications have been investigated to achieve satisfactory long-lasting results. The use of the pectoralis major muscle type I was described by Caldeira & Lucas<sup>11</sup>, in 2000. A mastopexy procedure that includes the placement of textured silicone implants in a double plane for the treatment of breast ptosis, and the use of a portion of the pectoralis major muscle to support the implant in its lower quadrant is used at the Plastic Surgery Department of Universidade Estadual de Campinas (Unicamp).

The present study describes the experience of the Plastic Surgery Department of Unicamp with the technique of mastopexy with breast implants in a double plane and a pectoralis major muscle flap.

## METHODS

A retrospective study of patients with grade II or III breast ptosis, diagnosed according to the classification of Regnault<sup>1</sup>, who underwent surgery from June 2008 to September 2010, was performed.

Twenty patients who were followed up for 9–12 months after the surgery were included in the study. The average age of the patients was 32.2 years (range, 26–53 years). With regard to ethnicity, 16 patients were Caucasian, 3 were of mixed race, and 1 was of African descent.

Preoperative examination revealed an average body mass index of 23.2 kg/m<sup>2</sup>. On physical examination of the breast, almost all patients were found to have poor quality skin, and only 1 had no stretch marks on the breast.

All patients underwent mastopexy with breast implants and a supporting flap of the pectoralis major muscle in a double plane, according to the technique described below.

### Skin Markings

The skin markings were performed with the patient in an upright position, defining the midline, meridians, and mammary creases (Figure 1). Point A was marked as a projection of the mammary crease in both breasts. Points B and C were marked by digital clamping, and point D was marked 2 cm above the breast crease. These points were connected in a similar manner to the marking proposed by Peixoto<sup>6</sup>.

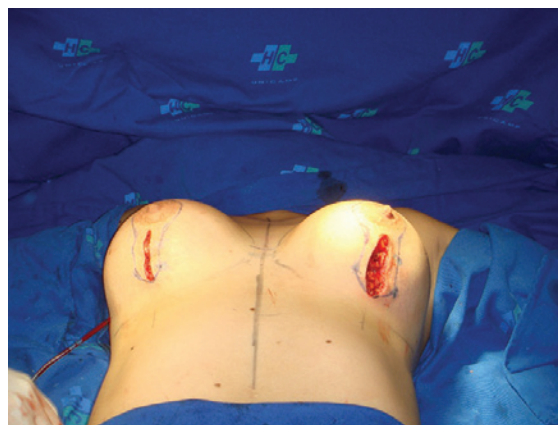
### Anesthesia and Surgical Technique

General anesthesia was used in all cases. With the patient in a supine position and a slight elevation of the dorsum (30 degrees), a vertical incision was made below the areolarpappillary complex, followed by the generation of a subglandular cavity for the implant.

An incision was then made in the pectoralis major muscle in the direction of its fibers, in the transition between the mid and lower thirds of the muscle (Figure 2). The lower portion

**Chart 1** – Regnault's<sup>1</sup> classification of breast ptosis.

Breast ptosis		
True ptosis	Grade I	Areola at the level of the mammary crease and above the contour of the gland
	Grade II	Areola below the level of the mammary crease and above the contour of the gland
	Grade III	Areola below the level of the mammary crease and below the contour of the gland
Partial ptosis		Areola above the crease and gland ptosis
Pseudoptosis		Areola above the mammary crease. Loose skin due to hypoplasia



**Figure 1** – Marking for skin resection (intraoperative period).

of the muscle was detached, and after rigorous hemostasis, the implants were positioned in a double plane. The upper part of the implant was positioned in the subglandular region and the lower part was submuscular, with the pectoralis muscle providing greater support to the implant (Figure 3).

The prepared muscular girdle was attached to the glandular tissue with nonabsorbable sutures. The need for closed drainage was assessed during surgery.

Using a bi-digital maneuver, the excess skin was marked and resected, resulting in a periareolar scar and a vertical or inverted T, depending on the amount of excised skin.

### Implants

Round, high profile, textured implants with a cohesive gel (Winner and Perthese brands), obtained by donation, were used.

## RESULTS

The volume of the implants ranged between 160 and 300 cc (average, 246.2 cc). Closed drainage (aspiration) with a portovac drain was used in 1 patient and maintained in place until 1 day after surgery.

No complications, including hematomas, seromas, infections, or capsular contractures, were reported in the patients

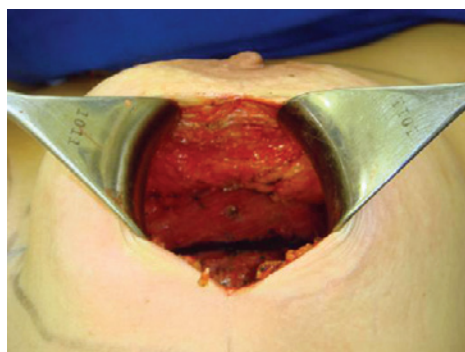


Figure 2 – Marking of the pectoralis major muscle flap.

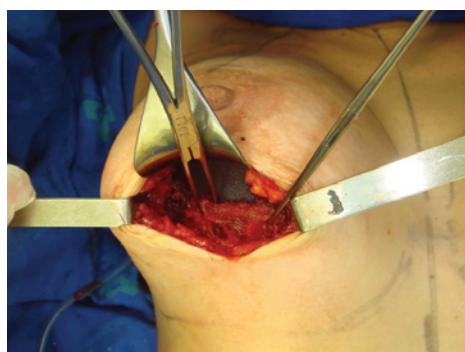


Figure 3 – Breast implant in double plane.

included in this study. There were 3 cases of partial dehiscence and 2 cases reporting enlarged scars.

At the 9 and 12-month follow-up examinations, there were no cases of breast or chest deformities, and none of the patients showed recurrence of ptosis. All patients presented with good breast projection and maintenance of adequate upper pole fill, with long-lasting and satisfactory results.

In the late postoperative period, the aesthetic results were considered satisfactory by the surgical staff and the patients (Table 1).

Figures 4 to 6 illustrate some cases of patients included in the study.

## DISCUSSION

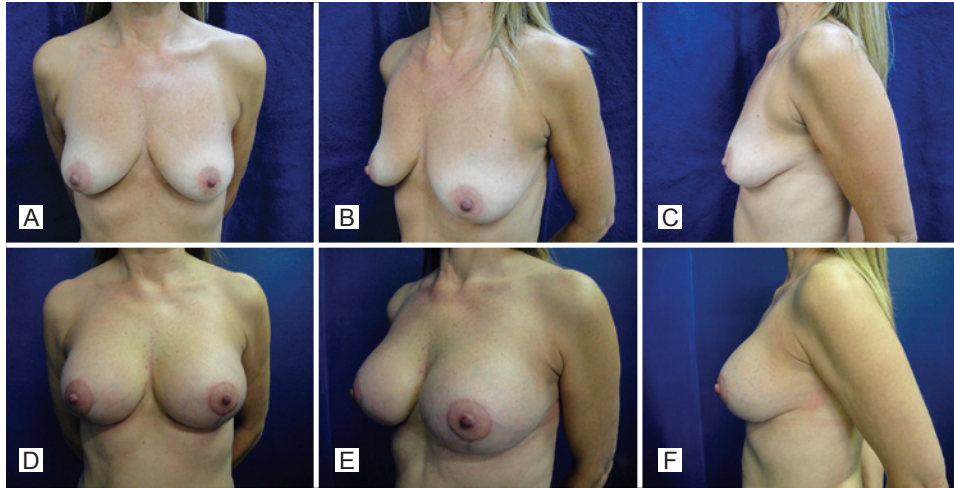
Mastopexy with breast implants is a procedure associated with a high degree of difficulty, which is even greater in patients with significant weight loss. This is because the skin of such patients is often of poor quality, characterized by stretch marks, excessive sagging, and decreased elasticity. This procedure is the subject of ongoing debate in the field of plastic surgery mainly because of the associated potential for complications, variation in results, and possibility of early recurrence of ptosis<sup>2-10</sup>.

The development of a mastopexy method capable of producing satisfactory and long-lasting results with good reproducibility has been the subject of research for many years. In the present study, we performed mastopexy using a technique that involves breast implants and the pectoralis major muscle flap. In this technique, an incision is made in the middle third of the pectoralis major muscle in the direction of its fibers, and the lower portion of the implant is supported by the pectoralis muscle flap while the upper portion is positioned above the muscle.

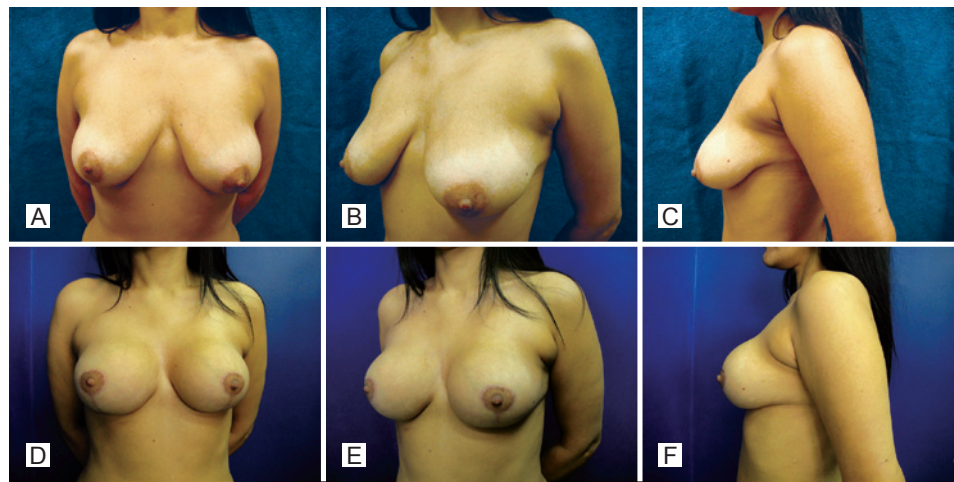
The use of muscular girdles in mastopexies has been reported in the literature for the reduction of early recurrence of breast ptosis, and this is achieved by providing better support to the implant and the parenchyma<sup>5,7,8,10-12</sup>. Moreover, the decrease in tension could potentially reduce the formation of scars<sup>11,12</sup>, resulting in a low incidence of dehiscences and enlarged or hypertrophic scars, such as the one presented in this study.

Table 1 – Assessment of the results obtained according to the patients and surgical staff.

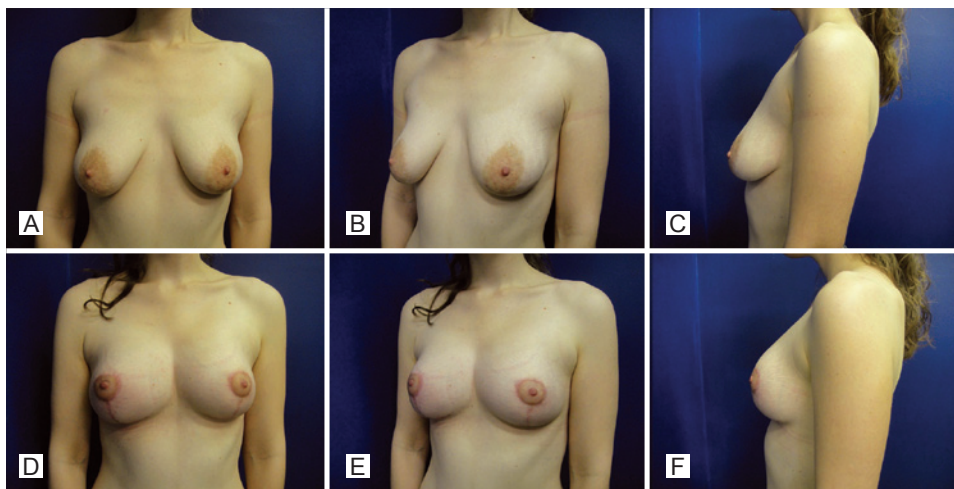
Postoperative results	Patients	Surgical staff
Unsatisfactory	—	—
Slightly satisfactory	—	—
Satisfactory	12	15
Very satisfactory	8	5



*Figure 4 – Case 1. A to C, preoperative period. D to F, postoperative period of 10 months.*



*Figure 5 – Case 2. A to C, preoperative period. D to F, postoperative period of 12 months.*



*Figure 6 – Case 3. A to C, preoperative period. D to F, postoperative period of 9 months.*

However, some disadvantages associated with the use of the pectoralis major muscle flap in mastopexies have been described in the literature, such as the possibility of thoracic deformities, muscular contractures, and potential need for the use of drains to avoid hematomas<sup>11</sup>. In the present study, aspirative drainage was only necessary in 1 patient, and no postoperative complications were reported.

## CONCLUSIONS

Mastopexy with the insertion of implants and the use of pectoralis major muscle flap is a technique that can be easily implemented; it has a relatively short learning curve, good reproducibility, and satisfactory short- and long-term results.

## REFERENCES

1. Regnault P. Breast ptosis. Definition and treatment. *Clin Plast Surg.* 1976;3(2):193-203.
2. Spear SL, Pelletiere CV, Menon N. One-stage augmentation combined with mastopexy: aesthetic results and patient satisfaction. *Aesthetic Plast Surg.* 2004;28(5):259-67.
3. Spear SL, Low M, Ducic I. Revision augmentation mastopexy: indications, operations, and outcomes. *Ann Plast Surg.* 2003;51(6):540-6.
4. Spear SL, Giese SY. Simultaneous breast augmentation and mastopexy. *Aesthetic Plast Surg.* 2001;107:1294-9.
5. Hurwitz DJ, Agha-Mohammadi S. Postbariatric surgery breast reshaping: the spiral flap. *Ann Plast Surg.* 2006;56(5):481-6.
6. Peixoto G. Reduction mammoplasty: a personal view. In: Goldwin RM, ed. *Reduction mammoplasty.* London: Little, Brown;1990. p. 337-62.
7. Colwell AS, Driscoll D, Breuing KH. Mastopexy techniques after massive weight loss: an algorithmic approach and review of the literature. *Ann Plast Surg.* 2009;63(1):28-33.
8. Hamdi M, Van Landuyt K, Blondeel P, Hijjawi JB, Roche N, Monstrey S. Autologous breast augmentation with the lateral intercostal artery perforator flap in massive weight loss patients. *J Plast Reconstr Aesthet Surg.* 2009;62(1):65-70.
9. Thornton DJ, Fourie R. Autologous augmentation-mastopexy after bariatric surgery: waste not want not! *Aesthetic Plast Surg.* 2010;34(4): 519-24.
10. Graf RM, Mansur AE, Tenius FP, Ono MC, Romano GG, Cruz GA. Mastopexy after massive weight loss: extended chest wall-based flap associated with a loop of pectoralis muscle. *Aesthetic Plast Surg.* 2008;32(2):371-4.
11. Caldeira AM, Lucas A. Pectoralis major muscle flap: a new support approach to mammoplasty, personal technique. *Aesthetic Plast Surg.* 2000;24(1):58-70.
12. Auersvald A, Auersvald LA. Breast augmentation and mastopexy using a pectoral muscle loop. *Aesthetic Plast Surg.* 2010;35(3):333-40.

### Correspondence to:

Andrea Boldrin Soares  
Rua Isabel Negrão Bertotti, 141 – ap. 74 – Mansões Santo Antonio – Campinas, SP, Brasil – CEP 13087-508  
E-mail: andreabsoares@yahoo.com.br