



Reconstruction of the distal third of the nose: case series and literature review

Reconstrução de terço distal do nariz: série de casos e revisão de literatura

RAISSA BARAKATT

DE FIGUEIREDO^{1*}

EDUARDO MACHADO

MARIANO

WILSON CINTRA-JUNIOR

HÉLIO KIYOTO

MAEBAYASHI

AN WAN CHING

JOSÉ ANTÔNIO CEZARETTI

■ ABSTRACT

Introduction: The nose has great aesthetic and functional importance, with a high incidence of malignant lesions. There are several techniques for reconstructing the distal third of the nose, but there is no universal indication; will depend on the characteristics of the injury. Surgical options vary between skin grafts and local, regional, and microsurgical flaps. The objective is to present a series of cases of reconstruction of the distal third of the nose using different surgical techniques, discussing the peculiarities and the results obtained. **Method:** This is a retrospective study carried out at the *Hospital do Servidor Público Estadual de São Paulo* (HSPE), evaluating a series of eight patients diagnosed with non-melanoma skin cancer located in the distal third of the nose and who underwent reconstruction by the team of Plastic Surgery. **Results:** Satisfactory results were obtained for all patients undergoing distal nose reconstruction, using total skin graft techniques (n=1) and local flaps (n=7), such as the bilobed, nasolabial, and dorsal nose flap. nose, paramedian frontal, and nasolabial transposition. **Conclusion:** Reconstruction of defects in the distal third of the nose is challenging and involves great technical variability. A careful assessment of the patient and the injury must be carried out, risks and benefits assessed and the decision shared with the patient.

Keywords: Nose neoplasms; Nose; Surgical flaps; Skin transplantation; Reconstructive surgical procedures.

■ RESUMO

Introdução: O nariz apresenta grande importância estética e funcional, com alta incidência de lesões malignas. Existem várias técnicas de reconstrução do terço distal do nariz, não havendo uma indicação universal; irá depender das características da lesão. As opções cirúrgicas variam entre enxerto de pele, retalhos locais, regionais e microcirúrgicos. O objetivo é apresentar uma série de casos de reconstrução de terço distal do nariz com diferentes técnicas cirúrgicas, discutindo as peculiaridades e os resultados obtidos. **Método:** Trata-se de estudo retrospectivo realizado no Hospital do Servidor Público Estadual de São Paulo (HSPE), avaliando uma série de oito pacientes com diagnóstico de câncer de pele não melanoma localizados em terço distal de nariz e que foram submetidos a reconstrução pela equipe de Cirurgia Plástica. **Resultados:** Foram obtidos resultados satisfatórios para todos os pacientes submetidos a reconstrução distal do nariz, tendo sido utilizadas técnicas de enxerto de pele total (n=1) e retalhos locais (n=7), tais como o retalho bilobado, nasogeniano, dorsal do nariz, frontal paramediano, e transposição nasolabial. **Conclusão:** A reconstrução de defeitos do terço distal do nariz é desafiadora e com grande variabilidade técnica. Deve-se realizar avaliação criteriosa do paciente e da lesão, avaliar riscos e benefícios e compartilhar a decisão com o paciente.

Descritores: Neoplasias nasais; Nariz; Retalhos cirúrgicos; Transplante de pele; Procedimentos cirúrgicos reconstrutivos.

Institution: Instituto de Assistência Médica ao Servidor Público Estadual de São Paulo (IAMSPE), São Paulo, SP, Brazil.

Article received: December 31, 2022.

Article accepted: December 5, 2023.

Conflicts of interest: none.

DOI: 10.5935/2177-1235.2024RBCP0779-EN

¹ Instituto de Assistência Médica ao Servidor Público Estadual, São Paulo, SP, Brazil.



INTRODUCTION

The nose is a complex, unique, three-dimensional anatomical structure with great functional and aesthetic importance, located in the center of the face¹⁻⁴. Its prominence on the face favors sun exposure and, consequently, presents a high incidence of skin cancer, mainly basal cell carcinoma (BCC), followed by squamous cell carcinoma (SCC), the most common cancer in the world population^{2,3,5,6}.

Demands for nasal reconstruction due to malignant lesions are on the rise. The surgical technique is challenging, especially in the distal third of the nose, where the skin is thicker and adheres to the underlying cartilage, and there is a greater risk of distortion of the nasal margins^{7,8}.

It is important to note that deeper injuries may compromise the cartilaginous framework and the nasal mucosa, requiring an even more complex reconstruction, aiming to maintain the functionality of the nose¹. Another important aspect is the analysis of the anatomical units, first described by Millard, and the nasal aesthetic subunits, later described by Burget and Menick, to adjust the surgical sutures where the subunits meet, thus creating a natural contour and hiding the sutures in the natural creases of the skin^{5,7,9-11}.

There are several techniques for reconstructing the distal third of the nose, but there is no universal indication³. The choice for each technique depends on the characteristics of the lesion, size, anatomical position, skin quality, patient comorbidities, and the surgeon's experience^{1,7}. Surgical options vary between skin grafts, and local, regional, and microsurgical flaps⁹.

OBJECTIVE

The objective of this work is to present a series of cases of reconstruction of the distal third of the nose using different surgical techniques, discussing the peculiarities and the results obtained.

METHOD

This is a retrospective study carried out in a single center, from March 2021 to March 2022. Eight patients diagnosed with non-melanoma skin cancer located in the distal third of the nose and who had reconstructions performed by the Surgery team were evaluated. Plastic surgery at the *Hospital do Servidor Público Estadual de São Paulo* (HSPE), in São Paulo, SP. After authorization from the Institutional Ethics Committee, the Free and Informed Consent Form was applied and the following data were collected from the patient's records: sex, age, comorbidities, histological type of tumor, reconstruction technique used, complications in the postoperative period, aesthetic and functional result, remission of the injury.

The diagnosis of non-melanoma skin cancer was made by prior biopsy, and written consent was signed before the procedure. Surgical excision of the lesion was performed with lateral margins of 4 to 6 mm. Intraoperative frozen section examination was performed until malignancy-free margins were obtained. Except for reconstruction with a paramedian frontal flap, which required general anesthesia and hospitalization, all other reconstructions were performed with local anesthesia and on an outpatient basis.

Preoperative injuries and recent and late postoperative outcomes were documented by digital imaging.

RESULTS

Five women (62.5%) and 3 men (37.5%) were treated, with a mean age of 82.2 years. Seven patients were Caucasian, with a Fitzpatrick classification between 1 and 2. Five patients had comorbidities, such as isolated arterial hypertension or associated with type 2 diabetes mellitus, and one patient had, in addition to these, asthma and dyslipidemia. Other patient data are summarized in Table 1 and some cases will be described below.

Table 1. Collected data.

Case	Sex	Age (years)	Size of the injury	Location of the injury	Histological type of pre-op/post-op lesion	Reconstruction carried out	Complication	Aesthetic/functional result	Injury remission
1 (Figure 1)	Feminine	88	0.4cm	Left nasal tip	CEC "in situ"/ actinic keratosis	Bilobed flap	None	Satisfactory / Satisfactory	Yes
2	Masculine	83	0.6cm	Left nasal wing	Nodular and micronodular BCC / nodular and superficial BCC	Auricular cartilage graft and flap bilobate	None	Satisfactory / Satisfactory	Yes

continued...

...continuation

Table 1. Collected data.

Case	Sex	Age years)	Size of the injury	Location of the injury	Histological type of pre-op/post-op lesion	Reconstruction carried out	Complication	Aesthetic/functional result	Injury remission
3 (Figure 2)	Feminine	74	1.0cm	Transition between back and nasal tip	Nodular BCC / nodular and micronodular BCC	Nasal dorsum flap	None	Nasal tip deviation / Satisfactory	Yes
4	Feminine	84	1.0cm	Right nasal wing	Nodular BCC/ micronodular and superficial BCC	Conch auricular cartilage graft and nasolabial flap pedicled superiorly	None	Satisfactory /Satisfactory	Yes
5 (Figure 3)	Masculine	85	4.0cm	Nasal dorsum and right and left lateral wall	Nodular and micronodular BCC /Nodular, micronodular, superficial and sclerodermi-form BCC	Pedicled paramedian frontal flap	None	Satisfactory / Satisfactory	Yes
6 (Figure 4)	Masculine	91	1.5cm	Left nasal tip	Nodular BCC/ nodular and infiltrative BCC	Tragal auricular cartilage graft and ear flap transpositionnasolabial	None	Quite satisfactory/ Quite satisfactory	Yes
7	Female	69	3.5cm	Nasal dorsum	Nodular, micronodular and sclerodermi-form BCC / Nodular and micronodular BCC	total skin graft	None	Regular / Satisfactory	Yes
8	Female	84	1.5cm	Right nasal wing and nasal tip	Nodular, micronodular and superficial BCC / nodular and superficial BCC superficial	total skin graft	None	Regular / Regular	Yes

Caption: BCC = basal cell carcinoma; SCC = squamous cell carcinoma

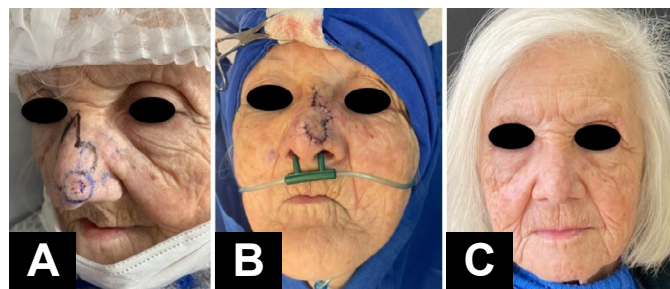

Figure 1. Case 1 - Squamous cell carcinoma *in situ* on the left nasal tip measuring 4mm. A) Surgical demarcation of the tumor with a 4mm lateral margin and the flap; B) Bilobed flap prepared; C) Late postoperative period of 1 year.

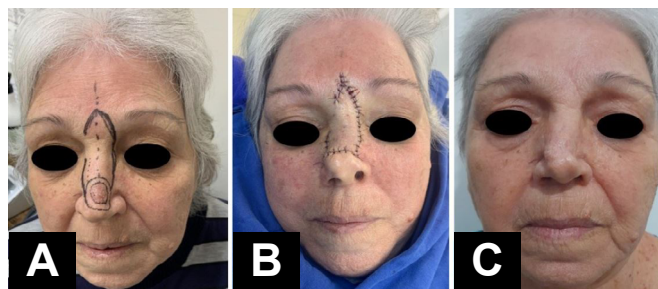

Figure 2. Case 3 - Nodular basal cell carcinoma located at the transition between the dorsum and nasal tip, measuring 1.0cm. A) Surgical demarcation of the tumor with a 4mm lateral margin and the frontonasal flap; B) Frontonasal Marchac flap positioned, leading to deviation of the nasal tip; C) Late postoperative period of one year.

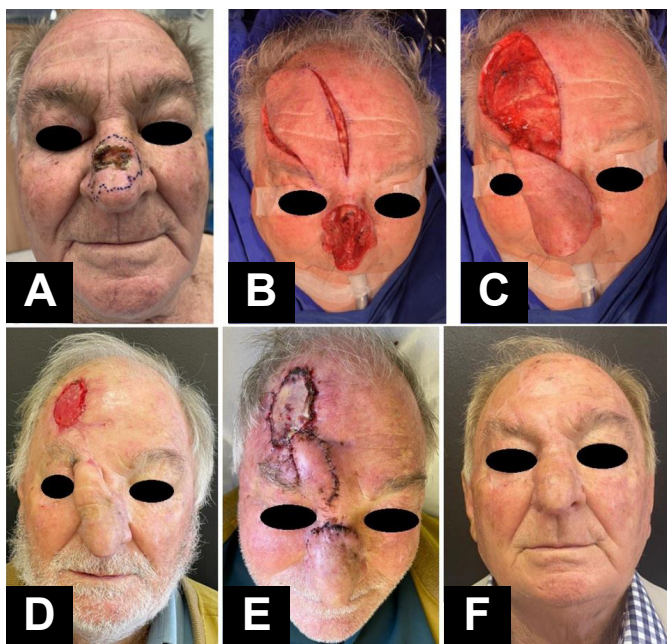

Figure 3. Case 5 - Ulcerated nodular and micronodular basal cell carcinoma measuring 4cm on the nasal dorsum and lateral walls of the nose. A) Surgical margins delimited by dermoscopy; B) Excision of the lesion with a lateral margin of 6mm and deep with resection of part of the nasal bone and septal, triangular and alar cartilages; C) Positioning of the frontal flap over the nasal defect; D) Pedicled paramedian frontal flap and forehead healing by secondary intention; E) Release of the pedicle of the paramedian frontal flap and graft from the donor area; F) One-year late postoperative result.

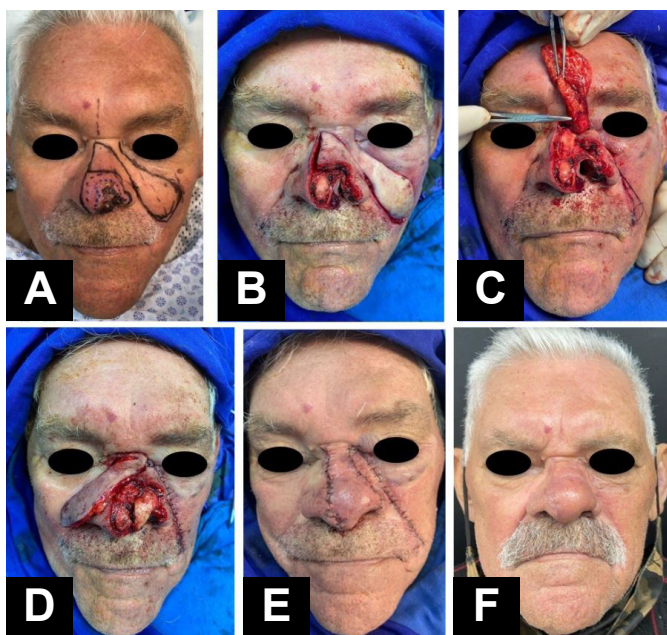


Figure 4. Case 6 - A) Ulcerated nodular basal cell carcinoma measuring 1.5cm on the left nasal tip demarcated with a lateral margin of 6 to 8mm; B) Excision of full-thickness lesion. Dissection of the axial nasolabial flap based on the angular artery in the proximal two-thirds and random in the distal third. Dissection of the dorsoalar residual inferior pedicle flap with a random pattern; C) Fixation of the residual dorsoalar flap of the inferior pedicle on the lateral nasal wall and inner corner of the eye; D) Closure of the proximal region of the internal nasal mucosa. Structuring the nasal tip with auricular cartilage graft; E) Transposition and fixation of the nasolabial flap in the region of the dorsum and tip of the nose, slimming the distal region and folding it over itself, to form the distal lining of the nasal vestibule; F) 30 days post-operative with very satisfactory results.

DISCUSSION

The oncological concept must be sovereign. The main objective is complete resection of the lesion, with evaluation of all margins before reconstruction. Mohs surgery, if available, is the gold standard for intraoperative margin assessment; Another form of evaluation is the frozen section examination, a method used in the patients in this study. If intraoperative evaluation is not possible, secondary intention healing, primary closure, and skin grafting should be chosen until postoperative evaluation is performed. Reconstruction should only be scheduled after pathological examination demonstrating margins free of involvement^{12,13}.

To define the best reconstruction approach, several aspects must be taken into consideration. First, consider the patient as a whole. If you have many comorbidities, a simpler single-stage technique is safer and more appropriate. Another factor to be analyzed is active smoking, where, when present, preference should be given to a single-stage technique¹⁴. The patient's active participation in the decision is important, especially in complex surgeries that require several approaches⁹.

The nasal defect must be evaluated in its location, related to the aesthetic subunits. The concept of nasal aesthetic units was described by Millard⁵, which improved surgical results. Later, Burget and Menick defended the concept of nasal aesthetic subunits, and if the defect affected more than 50% of the subunit, this entire region should be removed to camouflage the scar in the natural skin creases^{5,10}. However, this concept has been discussed in the literature, as the defect can become much larger and make reconstruction difficult¹⁴.

The depth of the nasal defect must be assessed to determine the affected components. In addition to the superficial soft tissue, the cartilaginous structure below may require reconstruction, using grafts mainly from the auricular region and the nasal septum¹⁴. The nasal mucosa is another structure that must be analyzed and reconstructed³. The main objectives are the aesthetics and respiratory function of the nose, that is, maintenance of similar skin color, reconstruction of the internal lining and nasal structural support, and avoiding airway stenosis⁵.

Local and regional flaps are preferred over skin grafts in terms of texture and color, but all types of reconstruction have their uses¹⁵. Reconstructing the distal third of the nose is challenging, as the skin is thick and adheres to cartilaginous structures; There is no local skin redundancy, which makes flap mobilization difficult. Reconstruction can generate tension and retraction of the nasal ala, causing aesthetic

and functional changes¹⁵. Surgical planning must be meticulous for the best possible result³.

Bilobed flap

The bilobed flap has excellent applicability for defects in the distal third of the nose⁹. It is composed of two “lobes” respecting the design at right angles between the axes, which allows double transposition¹⁶. The first “lobe” covers the defect, the second “lobe” covers the first donor area, and the second donor area is closed primarily³. Because the donor area is limited, this flap is generally used for small defects of up to 1.5 cm, with excellent results³. However, there are descriptions of its use for defects larger than 2.0cm with good results based on wide detachment for adequate tissue advancement¹⁷.

If there is a risk of nasal valve collapse, a cartilage graft can be associated with this technique⁹. This reconstruction has the advantage of being a single-stage procedure, good viability of the flap, good cosmetic result with similar skin texture and color, and discreet scar¹⁸. Among the disadvantages of this flap are the complex geometric lines of incision, requiring experience to not distort nasal symmetry, thus normally limiting it to minor defects^{7,9,14}.

Dorsal nose flap

The dorsal nose flap is based on the rotation of the skin of the proximal two-thirds of the nose and the glabellar region to cover distal defects, and closure of the donor area, which can be in VY, positioning the scar on the glabellar expression line. This technique was initially described by Gillies but became popular with Rieger, who described a flap with random vascularization and was later modified by Marchac and Toth, with axial vascularization of the angular artery close to the medial corner of the eye. This technique makes it possible to reconstruct defects in the supratip region measuring 1 to 2cm^{3,14,19-21}.

The advantage of the flap is that it can be performed in a single procedure, with a well-positioned scar and a good aesthetic result³. Among the disadvantages, we highlight the possible need for a disproportionately large flap to cover small defects and the possibility of traction of the tip of the nose upwards^{7,14}.

Nasolabial flap

The nasolabial flap is a widely used option in alar reconstruction. It can be designed based on an upper or lower pedicle, both with axial vascularization of branches of the facial artery, or V-Y^{3,15,22}. Ideally, some fibers of the common elevator muscle and nasal ala are

elevated together, constituting the smallest frequently used musculocutaneous flap²³. Reconstruction can be performed in one or two surgical stages; the flap must be designed 1 to 2mm larger, as it will shrink postoperatively; and the flap can serve as an internal nasal lining when necessary^{7,9}.

It presents reliable vascularization, discreet healing of the donor area and positioned in the pre-existing nasolabial fold, a good cosmetic result of the nasal ala, and the procedure can be performed in a single procedure^{3,9}. The disadvantages are the possibility of obliterating the concavity of the alar fold or even the need to perform a two-stage procedure^{7,9}.

Paramedian flap

The paramedian frontal flap is a reconstruction instrument widely used for larger defects located in the distal third of the nose^{9,24}. It is an interpolation flap with oblique skin from the forehead, with axial vascularization based on the supratrochlear artery³. It is generally created in two stages, in the first stage it is elevated and positioned in the nasal defect, and in the second, three weeks later, the pedicle is sectioned and the flap can be thinned and adjusted²⁵. Additional steps may be necessary for refinements, as well as reconstruction of the bone-cartilaginous framework⁹. The distal portion of the flap can be thinned and folded to form nasal mucosa³. The defect on the forehead can be closed by first or second intention, or grafted^{3,9}.

The advantage of the flap is having a reliable axial vascular supply, having the capacity to reconstruct large nasal defects in the distal third, with the possibility of reconstructing even the nasal mucosa; presenting satisfactory cosmetic results, as the skin on the forehead is compatible in color, texture and flexibility with that of the nose^{2,14,25}.

The disadvantages are the limited use in smokers, due to the risk of necrosis²⁵, the need to use general anesthesia, the multi-stage procedure, and a transverse scar on the forehead^{2,3}. Other negative points are the thick flap at the nasal tip when folded to create the lining and, if it is thinned, there is the possibility of reduced perfusion and local suffering¹. Finally, the psychological aspect of long-term reconstruction is a point that must be clarified so that patients have realistic expectations²⁵.

Nasolabial transposition flap

The nasolabial transposition flap is a reconstruction option for larger defects located in the distal third of the nose and was described by Beustes-Stefanelli et al.²⁶. It is designed using redundancy of nasolabial tissue to cover the nasal defect and a small,

inferiorly based residual dorsoalar flap to assist in tension-free closure of the inner corner of the ipsilateral eye associated with cheek advancement. The nasolabial flap has axial vascularization by branches of the facial artery in its proximal two-thirds and a random pattern in its distal third, and the dorsoalar residual flap has random vascularization. A cartilage graft can be associated for structuring, if necessary. The distal region of the nasolabial flap can be thinned and folded to form the lining of the nasal mucosa²⁶.

The advantages of the procedure are the possibility of reconstructing large nasal defects in a single procedure, reliable vascularization, without the need for general anesthesia, with good nasal aesthetic results, and a discreet scar in the pre-existing nasolabial fold. Disadvantages include the possibility of a thick flap at the nasal tip when folded to create the lining and, if it is thinned, there is the possibility of reduced perfusion and local suffering²⁶.

This flap was well indicated and performed in case 6 (Figure 4) of this study. The nasolabial flap was designed using tissue redundancy and a residual dorsoalar flap lateral to the defect. The nasolabial flap was transposed to the nasal dorsum and tip, in the distal region it was thinned and folded to create the nasal lining. The residual dorsoalar flap was transposed to the inner corner of the eye to close the area without tension. The structuring of the new nasal tip was carried out by collecting an auricular cartilage graft in a block from the region of the tragus blade, isthmus, and conchal cavity, as described by Pereira et al.²⁴. This unique, curved-shaped cartilage is fixed to the left alar region previously removed with the tumor to structure the new nasal tip.

Grafts

Skin grafts are options for reconstruction of the distal third of the nose in specific situations, normally when the patient has a high surgical risk for more complex procedures when strict surveillance is required for recurrence of malignancy, or temporarily until the definitive result of the anatomopathological examination^{9,27}. A total skin graft is used because it has greater thickness, less primary retraction, and better aesthetic results when compared to partial skin; maintained with a fixed dressing for 5 to 7 days to neutralize shear forces and allow better integration¹⁵. The pre- and post-auricular region, cervical, and clavicular region are used as graft donor areas¹⁵. The major disadvantage is the unfavorable aesthetic appearance due to the incompatibility of the skin in color, shape, and contour⁹.

CONCLUSION

Reconstruction of defects in the distal third of the nose is challenging, and multiple techniques are possible.

To decide on the reconstruction technique, a careful assessment of the patient and the characteristics of the defect must be carried out, risks and benefits assessed and the best options shared with the patient.

COLLABORATIONS

- RBF** Analysis and/or data interpretation, Conception and design study, Conceptualization, Data Curation, Formal Analysis, Investigation, Methodology, Project Administration, Realization of operations and/or trials, Software, Validation, Visualization, Writing - Original Draft Preparation, Writing - Review & Editing.
- EMM** Analysis and/or data interpretation, Conceptualization, Data Curation, Investigation, Methodology, Realization of operations and/or trials.
- WCJ** Analysis and/or data interpretation, Conception and design study, Conceptualization, Final manuscript approval, Formal Analysis, Project Administration, Supervision, Validation, Visualization, Writing - Review & Editing.
- HKM** Conceptualization, Final manuscript approval, Formal Analysis, Investigation, Supervision, Writing - Original Draft Preparation, Writing - Review & Editing.
- AWC** Final manuscript approval, Formal Analysis, Project Administration, Supervision.
- JAC** Formal Analysis, Project Administration, Supervision.

REFERENCES

1. Yildiz K, Gorgulu T, Yesiloglu N, Kelahmetoglu O, Camli MF, Canter HI. Hybrid reconstruction of distal nasal defects. *Dermatol Ther.* 2021;34(1):e14734.
2. Schäfer K, Rudolph C, Cotofana S, Goebeler M, Weyandt G. Large Nasal Defects with Exposed Cartilage: The Folded Transposition Flap as an Innovative Alternative to the Paramedian Forehead Flap. *Dermatology.* 2018;234(3-4):99-104.
3. Mysore Srinivas V, Kalapurmat Nagabhushanaiah M. Nose Reconstruction Using Local and Regional Flaps: The Challenges and Advantages. *J Cutan Aesthet Surg.* 2021;14(1):77-83.
4. Moura BB, Signore FL, Buzzo TE, Watanabe LP, Fischler R, Freitas JOG. Nasal reconstruction: an analysis of a series of cases. *Rev Bras Cir Plást.* 2016;31(3):368-72.
5. Marcasciano M, Tarallo M, Maruccia M, Fanelli B, La Viola G, Casella D, et al. Surgical Treatment with Locoregional Flap for the Nose. *Biomed Res Int.* 2017;2017:9750135.

6. Brasil. Ministério da Saúde. Instituto Nacional do Câncer. Estimativa 2020: incidência do Câncer no Brasil [Internet]. Rio de Janeiro: Instituto Nacional do Câncer; 2019 [acesso 17 abr 2022]. Disponível em: <https://www.inca.gov.br/sites/ufu.sti.inca.local/files/media/document/estimativa-2020-incidencia-de-cancer-no-brasil.pdf>
7. Cason RW, Shamma RL, Pyfer BJ, Glener AD, Marcus JR, Cook JL. Cutaneous Reconstruction of the Nasal Distal Third: Alternative Local Flaps for a Complex Region. *Plast Reconstr Surg Glob Open*. 2021;9(5):e3444.
8. Souza MPS, Pessoa SGP, Muniz VV, Rebelo AD, Holanda EF, Pessoa LMGP. Opções de reconstrução após ressecção de tumor de pele nasal. *Rev Bras Cir Plást*. 2019;34(Suppl. 3):50-2.
9. Konofaos P, Alvarez S, McKinnie JE, Wallace RD. Nasal Reconstruction: A Simplified Approach Based on 419 Operated Cases. *Aesthetic Plast Surg*. 2015;39(1):91-9.
10. Burget GC, Menick FJ. The subunit principle in nasal reconstruction. *Plast Reconstr Surg*. 1985;76(2):239-47.
11. Marinho CCC, Miranda ML, Lima RC, Rodrigues CJ, Pego KVT, Reis CF, et al. Reconstruction of the nasal subunits after tumor resection. *Rev Bras Cir Plást*. 2021;36(2):156-63.
12. National Comprehensive Cancer Network. Basal Cell Skin Cancer (Version 2.2022) [Internet]. 2022 [acesso 4 abr 2022]. Disponível em: <https://www.nccn.org/>
13. National Comprehensive Cancer Network. Squamous Cell Skin Cancer (Version 2.2022) [Internet]. 2022 [acesso 2 de abr 2022]. Disponível em: <https://www.nccn.org/>
14. Rohrich RJ, Griffin JR, Ansari M, Beran SJ, Potter JK. Nasal reconstruction--beyond aesthetic subunits: a 15-year review of 1334 cases. *Plast Reconstr Surg*. 2004;114(6):1405-16; discussion 1417-9.
15. Sadick H, Häussler D, Rotter N. [Options for reconstruction of nasal defects]. *HNO*. 2020;68(12):959-70. German.
16. Tissiani LAL, Alonso N, Carneiro MH, Bazzi K, Rocco M. Versatilidade do retalho bilobado. *Rev Bras Cir Plást*. 2011;26(3):411-7.
17. Vasilakis V, Nguyen KT, Klein GM, Brewer BW. Revisiting Nasal Reconstruction after Mohs Surgery: A Simplified Approach Based on the Liberal Application of Local Flaps. *Ann Plast Surg*. 2019;83(3):300-4.
18. Laitano FF, Teixeira LF, Siqueira EJ, Alvarez GS, Martins PDE, Oliveira MP. Uso de retalho cutâneo para reconstrução nasal após ressecção neoplásica: 102 casos. *Rev Bras Cir Plást*. 2012;27(3 Suppl.1):21.
19. Redondo P, Bernad I, Moreno E, Ivars M. Elongated Dorsal Nasal Flap to Reconstruct Large Defects of the Nose. *Dermatol Surg*. 2017;43(8):1036-41.
20. Marchac D, Toth B. The axial frontonasal flap revisited. *Plast Reconstr Surg*. 1985;76(5):686-94.
21. Decusati FL, Rinaldi AE. Reconstrução de defeitos nasais utilizando o retalho de Rieger. *Rev Bras Cir Plást*. 2020;35(2):149-53.
22. Rosseto M, Nunes e Silva D, Lyrio ALC, Lyrio ALC, Rosseto AC. Retalho nasogeniano de pedículo inferior na reconstrução de asa nasal. *Rev Bras Cir Plást*. 2022;37(1):22-6.
23. Cerci FB, Nguyen TH. Nasolabial interpolation flap for alar reconstruction after Mohs micrographic surgery. *Surg Cosmet Dermatol*. 2014;6(2):113-20.
24. Pereira CM, Venturelli Júnior EP, Rocha RS, Gonçalves PR, Silva FN, Bocardo SD. Reconstrução nasal com retalho frontal paramediano após ressecção oncológica. *Rev Bras Cir Plást*. 2020;35(3):373-7.
25. Zito PM, Hohman MH, Mazzoni T. Paramedian Forehead Flaps [Internet]. *StatPearls [Internet]*. Treasure Island (FL): StatPearls Publishing [acesso 2 mar 2022]. Disponível em: <https://www.ncbi.nlm.nih.gov/books/NBK499932/?report=printable>
26. Beustes-Stefanelli M, O'Toole G, Schertenleib P. The Midline-based nasolabial transposition (MNT) flap: an original single-stage technique for nasal tip reconstruction. *Ann Plast Surg*. 2015;74(4):426-31.
27. Sbalchiero JC, Gregório TCR, Leitão L, Leal PRA, Dibe MJA. Condutas na reconstrução da ponta nasal no tratamento das neoplasias cutâneas. *Rev Bras Cir Plást*. 2005;20(1):12-6.

***Corresponding author: Raissa Barakatt de Figueiredo**

Diretoria da Cirurgia Plástica

Rua Pedro de Toledo, 1.800, 9º andar, Vila Clementino, São Paulo-SP

Zip code: 04039-000

E-mail: raissa_barakatt@hotmail.com