

# Umbilical Restoration in Abdominoplasty: A Simple Rectangular Technique

Luis López-Tallaj, MD<sup>1</sup>

José de Gervais, MD<sup>2</sup>

- 1] Candidate to the Brazilian Society of Plastic Surgery.
- 2] Full member of the Brazilian Society of Plastic Surgery, Head of the Plastic and Hand Surgery Service of Rio de Janeiro Santa Casa da Misericórdia Hospital.

Study performed at the Plastic and Hand Surgery Service of Rio de Janeiro Santa Casa da Misericórdia Hospital.

Address for correspondence:

Luis López Tallaj, MD

R. Santa Luzia 206-11<sup>a</sup> Enf.  
20020-020 – Rio de Janeiro – RJ  
Brazil

Phone: (55 21) 220-1778  
e-mail: lopeztallaj@email.com

**Keywords:** Umbilicus; reconstruction; restoration; dermolipectomy; flap.

## ABSTRACT

*The authors present a simple technique for umbilicus restoration in abdominal dermolipectomy. The procedure consists of a rectangular incision in the skin of the abdomen, slightly curved at the superior and inferior poles, after freeing the umbilicus with a circular incision in the abdominal tissue. The technique gives the umbilicus a natural, circular shape, obtaining a satisfactory result. Different drawings and pictures are shown to explain the skin procedure.*

## INTRODUCTION

The umbilicus has been described as a 1.5 to 2 cm diameter depressed scar, surrounded by a natural skin fold, anatomically situated at the level of the superior iliac crests<sup>(1, 2)</sup>. Many surgical procedures for reconstructing the umbilicus during dermolipectomy have been described.

Some authors have proposed using a different array of skin incisions to improve the shape of the umbilicus and disguise the periumbilical scar<sup>(1, 3, 4, 5)</sup>. Others defend using a conchal cartilage composite graft as the donating area to recreate the shape of the umbilicus<sup>(6)</sup>.

Most of the existing procedures propose a circular skin incision of the umbilical cone to free it from its original position. The biological development of a circular scar eventually leads to retraction of the circular incision, and therefore to stenosis of the neo-umbilicus.

The authors propose a simple procedure that allows restoring the umbilical anatomy and hiding the scar that is buried around the umbilicus, leaving only its inferior margin visible.

## SURGICAL TECHNIQUE

The first half of umbilicus restoration comprises a skin incision, to free the umbilicus from its original position. After marking the incision area, we position the

index finger in the umbilical cavity and cut around the mark, freeing the umbilicus cone in a circular fashion (Fig. 1), measuring 1.5 cm in diameter.

After removing the excess abdominal skin, the next phase is to reposition the neo-umbilicus. A fixation point with mononylon 3-0, 5 mm under the margin of the umbilicus is employed to put it at the aponeurosis of the linea alba. This suture allows the fixation of the umbilicus. A second suture inserts it at the xiphumbilical line (Fig. 2).

After the guide sutures are placed to approximate the abdominal flap and the pubic area, we decide upon the position of the umbilicus on the abdominal skin. The position is marked 0.5 cm under the projected




Fig. 1 – After drawing a circle, the incision is performed around the index finger positioned in the umbilicus cavity to free the circular cone.

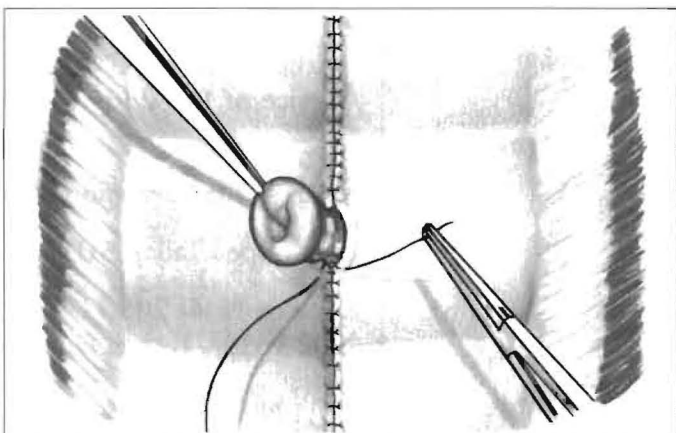


Fig. 2 – We use mononylon 3-0, 5 mm fixation suture, under the umbilicus margin, at 6:00 and 12:00 o'clock.

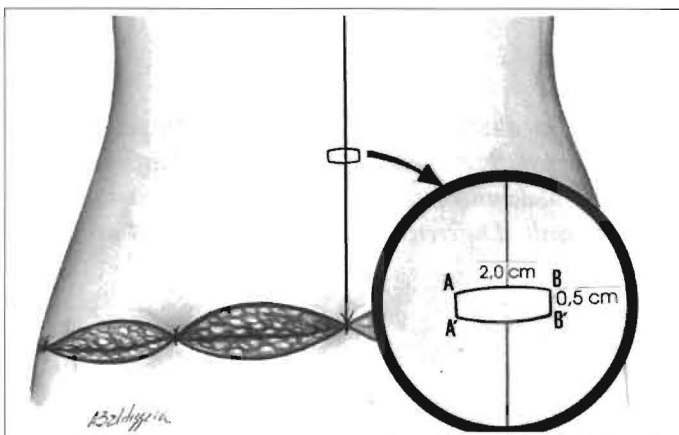


Fig. 3a – Drawing of the slightly curved rectangular marking at the superior and inferior poles over the abdominal wall skin.

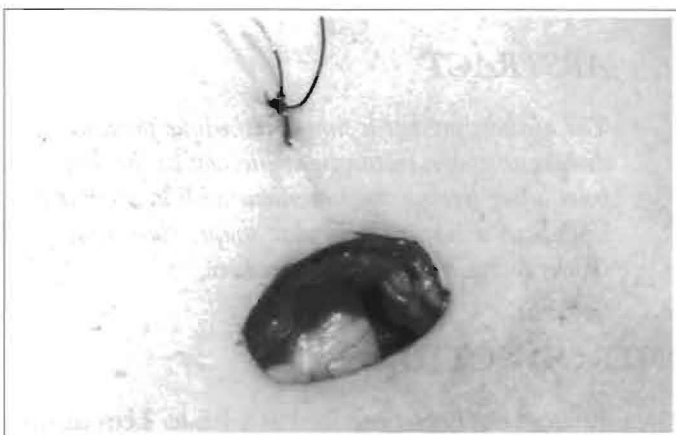

Fig. 3b – View of the umbilical cone after the rectangular incision through the abdominal wall.

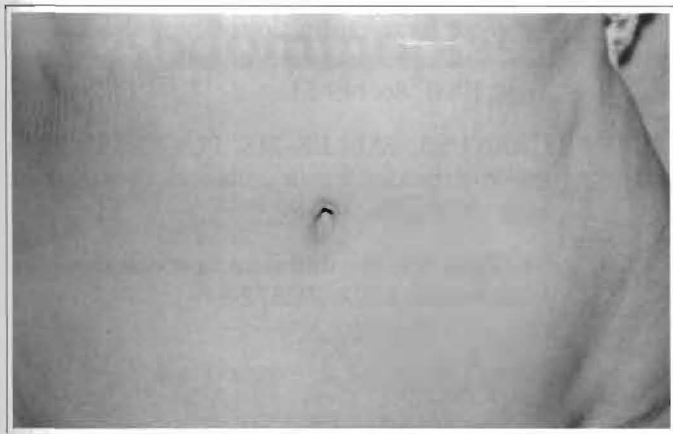


Fig. 4 – One year and 6 month postoperative period, demonstrating the natural aspect of the umbilicus, with a practically unnoticeable scar.

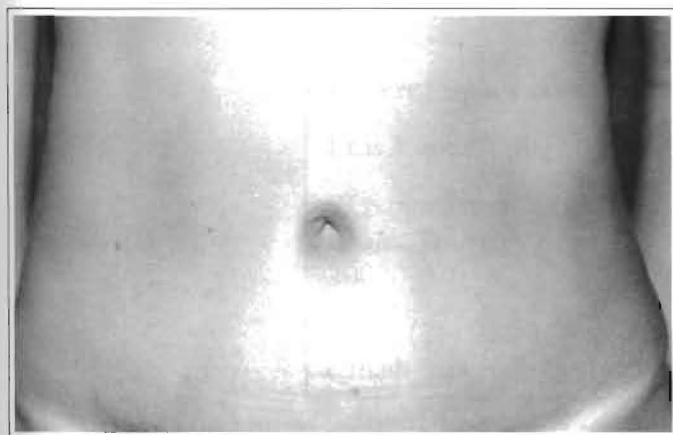


Fig. 5 – One year postoperative period, with a hidden scar buried around the umbilicus.

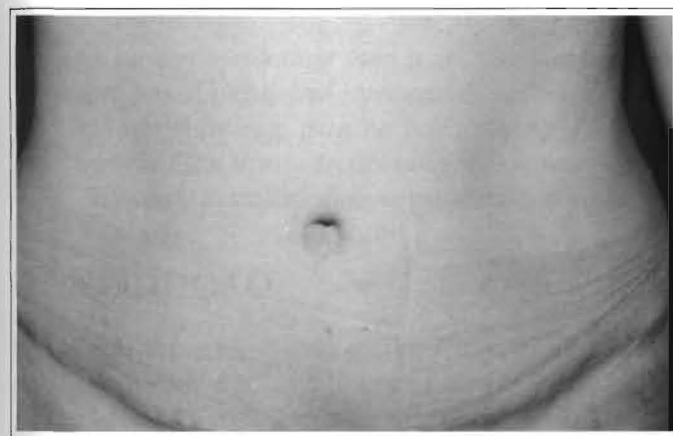


Fig. 6 – Six-month postoperative period showing a preserved anatomical shape.

position of the umbilicus on the abdominal skin. This positioning reduces skin tension on the pubic incision.

A rectangle, slightly curved at the superior and inferior poles is drawn on the abdominal skin in the neo-umbilical position (Figs. 3a & 3b). The A-B line should not exceed 2 cm, and the A-A' line should not exceed 0.5 cm. Subcutaneous fat is removed with a pair of scissors after the skin incision is made around the neo-umbilical position.

## POSTOPERATIVE PERIOD

A vaseline-saturated gauze dressing is kept over the entire umbilical area during the immediate postoperative period. We tell the patient to change the dressing, using a mild topical corticoid and gauze to fill the umbilicus after bathing after the seventh day. After three weeks, we place a small sphere that is kept in place for 3 months to maintain the shape and compress the scar until it flattens.

## COMPLICATIONS

In our series from February 1999 to February 2001, there were four complications, that were treated with dressings, and three hypertrophic scars treated with triamcinolone spray.

## CONCLUSION

The umbilicus is a neonatal scar that remains invisible because it is hidden in the back of the cavity, and it is essential to the abdominal contour. It helps define the median abdominal sulcus, contributing to the proportionate curve of the inferior abdomen<sup>(7)</sup>. Many techniques have been proposed to reposition the umbilicus<sup>(1, 3, 4)</sup>. In the present study we present another easy way to perform the technique. This was used in 110 surgeries, from February 1999 to February 2001, all of which maintained the anatomical shape of the umbilicus and, due to its importance as a sexual focus<sup>(8)</sup>, maintained its integrity in this respect (Figs. 4 - 6).

## REFERENCES

1. BAROUDI R. Umbilicoplasty. *Clin. Plast. Surg.* 1975; 2:431-48.

2. DUBOU R, OUSTERHOUT DK. Placement of the umbilicus in an abdominoplasty. *Plast. Reconstr. Surg.* 1978; 61:291-3.
3. MASSIHA H, MONTEGUT W, PHILLIPS R. A method of reconstructing a natural looking umbilicus in abdominoplasty. *Ann. Plast. Surg.* 1997; 38:228-31.
4. ITOH Y, ARAI K. Umbilical reconstruction using a coneshaped flap. *Ann. Plast. Surg.* 1992; 28:335-8.
5. CANNISTRA G, PECORRELLI E. Umbilical restoration in abdominal dermolipectomy: a simple double-Y, double-M technique. *Aesth. Plast. Surg.* 1999; 23:364-66.
6. MATSUO K, KONDOH S, HIROSE T. A simple technique for reconstruction of the umbilicus using a conchal cartilage composite graft. *Plast. Reconstr. Surg.* 1990; 86:149-51.
7. CRAIG SB, FALLER MS, PUCKETT CL. In search of the ideal female umbilicus. *Plast. Reconstr. Surg.* 2000; 105:389-92.
8. BROWN ES. The umbilicus as sexual focus. *Int. J. Psychoanal.* 1997; 78:577-8.