



Alternatives to omphaloplasty in aesthetic surgery of the abdomen: Review of the *Revista Brasileira de Cirurgia Plástica* and presentation of the experience with the technique in H

Alternativas para onfaloplastia em cirurgia estética do abdome: Revisão da Revista Brasileira de Cirurgia Plástica e apresentação da experiência com técnica em H

BALDUINO FERREIRA DE MENEZES NETO^{1*}
LUCAS VANNUCHI MAGNANI¹
MURILO SGARBI SECANHO¹
FAUSTO VITERBO DE OLIVEIRA NETO¹

■ ABSTRACT

Introduction: Abdominoplasty has been among the most popular cosmetic procedures in plastic surgery in recent years. From the perspective of body image, making the new navel is a key part, and its absence, distortion, or poor healing compromises the surgical result. Several techniques have been described, but all with their limitations. The objective was to gather a summary of the surgical possibilities presented in the *Revista Brasileira de Cirurgia Plástica* (RBCP), in addition to reintroducing the technique in H. **Method:** A qualitative review of the literature published in the RBCP in the period from 2000 to 2021 was carried out. Articles were included that described a proposal for umbilicoplasty, referring to the number of patients, age, follow-up time, assessment of patient satisfaction, and complications, excluding publications without aesthetic purposes or patients after major weight loss. **Results:** 38 articles were found, 7 of which were excluded by analyzing the titles and abstracts. Two independent authors reviewed the other articles, excluding another 20. In the end, 11 articles were included in this review. **Conclusion:** Omphaloplasty in abdominoplasties can be performed in several ways, providing surgeons with various alternatives. The H technique is one of these tools which can be widely used and bring consistent results.

Keywords: Umbilicus; Review; Abdomen; Reconstructive surgical procedures; Aesthetics.

■ RESUMO

Introdução: A abdominoplastia está entre os procedimentos estéticos mais procurados na cirurgia plástica nos últimos anos. Dentro da perspectiva da imagem corporal, a confecção do neoumbigo é peça chave, e sua ausência, distorção ou má cicatrização comprometem o resultado cirúrgico. Diversas técnicas foram descritas, mas todas com suas limitações. O objetivo foi reunir um resumo das possibilidades cirúrgicas apresentadas na *Revista Brasileira de Cirurgia Plástica* (RBCP), além de reapresentar a técnica em H. **Método:** Foi realizada revisão qualitativa da literatura publicada na RBCP no período de 2000 a 2021. Foram incluídos artigos que descrevessem uma proposta de umbilicoplastia, referindo número de pacientes, idade, tempo de seguimento, avaliação da satisfação dos pacientes e complicações; sendo excluídas publicações sem fins estéticos ou pacientes pós grandes perdas ponderais. **Resultados:** Foram encontrados 38 artigos, sendo excluídos 7 pela análise dos títulos e resumos. Os demais artigos foram revisados por dois autores independentes, sendo realizada a exclusão de mais 20 artigos. No final, 11 artigos foram incluídos nesta revisão. **Conclusão:** A onfaloplastia em abdominoplastias pode ser realizada de várias formas, possibilitando uma gama variável de alternativas para os cirurgiões. A técnica em H é mais uma dessas ferramentas, podendo ser amplamente utilizada e trazendo resultados consistentes.

Descritores: Umbigo; Revisão; Abdome; Procedimentos cirúrgicos reconstrutivos; Estética.

Institution: Hospital das Clínicas da Faculdade de Medicina de Botucatu, Botucatu, SP, Brazil.

Article received: February 23, 2022.
Article accepted: July 11, 2022.

Conflicts of interest: none.

DOI: 10.5935/2177-1235.2023RBCP0706-EN

¹ Hospital das Clínicas da Faculdade de Medicina de Botucatu, Botucatu, SP, Brazil.



INTRODUCTION

Abdominoplasty is among the most popular cosmetic procedures in plastic surgery in recent years¹. Their search not only impacts body contouring issues, but also improves patients' quality of life and self-esteem of patients².

From the perspective of body image, the navel is a key part since it has a definitive role in the aesthetics of the abdominal wall. Its absence, distortion, or poor healing compromises the surgical outcome³.

Due to its importance, the construction of the neoumbilicus, which aims to seek a natural position, in the midline, at the level of the superior iliac crests, with a minimal evident scar³, and 1.5 to 2 cm in diameter⁴, is a determining factor for postoperative success^{5,6}.

Several techniques have been described in the literature, but all with their limitations⁷⁻¹⁰.

More recent options, which try to deepen the scar, not making it visible, present complications, such as a flattened navel¹¹.

Furthermore, neo-umbilical stenosis is a frequent complication in surgical tactics that aim to construct a small umbilicus or result in circular or concentric scars¹²⁻¹⁵.

When the umbilical stump is long, it needs to be shortened, which may result in other complications, such as stenosis or discharge from the neoumbilicus¹⁶.

Due to the complexity of the issue and the search to improve and develop a surgical tactic with better results, Viterbo¹⁷ (1998) described the H-shaped technique for omphaloplasty. In it, using four rectangular flaps, there is the reconstruction of the lateral walls of the navel, with good results and lower rates of aesthetic complications.

OBJECTIVE

This article summarizes the surgical possibilities presented in the Revista Brasileira de Cirurgia Plástica (RBCP) in the last 20 years and reintroduces the surgical technique in H.

METHOD

In order to carry out a qualitative review of the literature, a study of publications in the RBCP from 2000 to 2021 was carried out.

Analysis of RBCP articles

The research was carried out in articles with the descriptors "omphaloplasty," "umbilicus," "neoumbilicus," "umbilicoplasty," and "umbilical scar" in September 2021 on the RBCP website.

Surgical technique

In the navel, which will be removed from the abdomen, we mark four lines in the longitudinal direction, from the bottom to the edges, creating a division of four equal parts in the umbilical circumference (Figure 1A). Next, two transverse lateral lines are drawn, deeply connecting the longitudinal lines, in order to delimit two lateral flaps, with the base having $\frac{1}{4}$ of the circumference of the umbilicus and the length half of the base, and these values may vary, for correct very deep navels (Figure 1B). Then, two more transversal lines are drawn, superficially joining the longitudinal lines (Figure 1C).

After making the incisions, we will release the navel as a "bow-tie," with a central part and two lateral flaps. Then, a simple stitch is applied, leaving the thread long for easy flap location.

After displacement, traction, resection, and suture of the abdominal flap, we mark the place where the umbilicus will emerge, the design of the capital letter "H" inside a square that will have dimensions of $\frac{1}{4}$ of the umbilicus circumference (Figure 1D).




Figure 1. Right side view: Four longitudinal lines are drawn from the bottom to the edges (A); two lateral transverse lines are drawn in a vertical plane, deeply joining the longitudinal lines (B); two transverse lines are drawn, superficially joining the longitudinal lines in a horizontal plane (C); a capital letter "H" is drawn where the new navel will emerge (D).

After incising the skin, we will have two flaps, one on the upper base and the other on the lower base. These flaps will have the same dimensions as the navel flaps, that is, a base equal to $\frac{1}{4}$ of the circumference of the navel and a length equal to half the base.

The abdominal wall and umbilicus flaps will be sutured to be perfectly interposed (Figure 2).

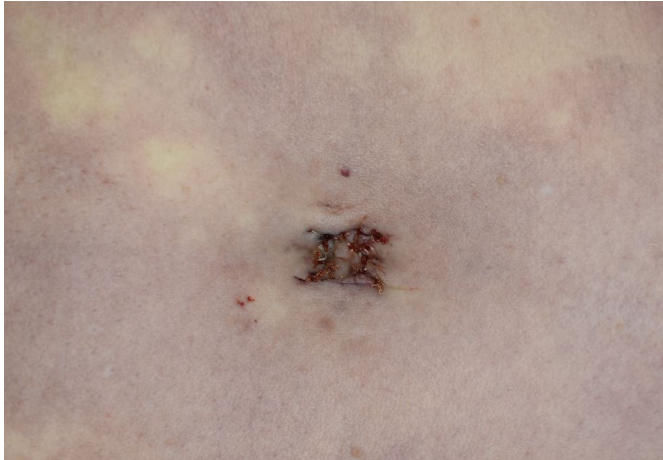


Figure 2. Appearance at the end of the procedure in right lateral view: suture of the abdominal wall and umbilicus flaps (preferably with non-absorbable monofilament thread).

Article inclusion criteria

Articles published in the RBCP and available on its website were included, describing a proposal for umbilicoplasty, referring to the number of patients, age, follow-up time, assessment of patient satisfaction, and complications.

Article exclusion criteria

Articles that performed umbilicoplasty for non-aesthetic purposes, patients after major weight loss, or did not adequately detail the above data were excluded.

CEP

The research complies with the Helsinki recommendations and the Research Ethics Committee (CEP) of the Hospital das Clínicas of the Faculdade de Medicina de Botucatu, being approved under opinion number 4,961,829.

RESULTS

RBCP Articles

For the sum of the descriptors “omphaloplasty,” “umbilicus,” “neoumbilicus,” or “umbilicoplasty,” “umbilical scar,” or “neo-omphaloplasty,” 38 articles were found.

By analyzing the titles and abstracts, 7 articles were excluded, as they focused on post-great weight loss and pathological alterations of the navel or mini-abdominoplasty.

Due to the small number of articles that fit the 5 inclusion criteria, we decided to conduct a qualitative

review, allowing the inclusion of articles with at least three of the five inclusion criteria.

Among those selected for abstract evaluation, 20 articles were excluded for not including at least three of the following criteria: patients’ age, follow-up time, description of the technique, complications, and report of satisfaction; in addition to excluding those that were just case reports or predominantly included patients after major weight loss.

In the end, 11 articles¹⁸⁻²⁸ were included for full reading and analysis by two independent researchers (BFMN and LVM), with only 7 having all five criteria, 1 having four criteria, and 3 having three. The summary of the data found is in Table 1.

Due to the lack of standardization and the use of systematic evaluation methods, it was impossible to carry out statistical analyses regarding the inclusion criteria.

DISCUSSION

Even after the most varied surgical techniques, Umbilical reconstruction remains an important challenge for plastic surgeons. Attention should be given to the umbilical anatomical units and their maintenance or creation - bun, mamelon, and umbilical sulcus^{4,29}. For many, the ideal shape sought is an oval or “T” navel with a vertical orientation of small dimensions, similar to that of young women^{22,30}.

The absence of anatomical patterns or the presence of distortions, pathological scarring, and stenosis, among other complications, can lead to dissatisfaction with the result, in addition to having difficult surgical correction³¹.

Vernon³² (1957) was the first surgeon to describe the transposition technique for creating a new navel in abdominoplasty. The surgery described consisted of a circular technique. Other authors continued to develop new approaches, but still in circular scars³³. Grazer & Goldwyn³⁴ (1977), in a study of 10,574 patients who underwent abdominoplasty, reported that 45% claimed to have stenosis or cicatricial contracture in the navel. Rosique et al.³⁵ (2009) reported a seven times greater chance of these complications when using the circumferential tactic.

Intending to seek better results, Avelar³⁶ (1978) described a technique with an internal scar by creating a star-shaped flap, in which the resulting scar presented variation in direction, thus reducing complications such as stenosis and cicatricial retraction. Other techniques based on non-circular scars were developed after these, but with aesthetic results that are often unsatisfactory¹¹.

Despite the various umbilicoplasty options described in the literature, the senior author sought an

Table 1. Summary of article data included for full reading and analysis.

Article	No. of patients	Age	Time to follow-up	Satisfaction	Complications
Technique for umbilicoplasty, avoiding one of the main stigmas of abdominoplasties ¹⁸	100	X	+ 3 months	Full of patient – 89%; Full of surgeon – 85%; Reasonable of patient – 11%; Reasonable for the surgeon – 13%; Patient dissatisfaction – 0%; Surgeon dissatisfaction – 2%.	2 cases – circular contracture of the new navel (2%).
Routine neo-omphaloplasty in abdominoplasties ¹⁹	46	X	2 to 19 months	X	1 case - erasure of the scar (keloid scar) (2.1%); 3 cases – dehiscence (6.5%).
Triangular umbilicoplasty with dermal flap ²⁰	194	X	X	188 patients (96.91%) Had positive satisfaction; In 186 cases (95.88%) the surgeons had positive satisfaction.	5 cases - Epidermolysis in umbilical stump (10.8%); 3 cases – umbilical narrowing due to scar retraction (6.5%).
Technique with umbilical pedicle in a “kite” and incision of the skin of the abdomen in a “Y” ²¹	31	28 and 57 years	6 months	bad 0; reasonable 3.2%; good 6.5%; very good 12.9%; Excellent 77.4%.	5 cases – epidermolysis of the stump (16.1%); 1 case – necrosis of the retail (3.2%); 3 cases – epidermolysis of creases (9.6%); 1 case – stenosis stigma (3.2%); 1 case – visible scar (3.2%).
Vertical incision umbilicoplasty: description of the technique and evaluation of satisfaction ²²	128	25 to 62 years	40 months	92.2% of the patients were very satisfied, and the technical evaluation by the evaluating surgeon attested to a degree of 88.8% satisfaction.	2 cases – umbilical scar suture dehiscence (1.5%); 4 cases – hypertrophic scar (3.1%); 2 cases – Stenosis (1.5%); 1 case – umbilicus necrosis (0.7%).
Omphaloplasty: Y/V technique ²³	88	27 to 62 years	36 months	It does not explain patient satisfaction.	3 cases – Suture dehiscence in (3.4%); 1 case – umbilical stenosis (1.13%); 4 cases – chronic alterations of the scar (4.54%); 2 cases – scars with keloid (2.27%).
Cosmetic and functional surgery of the umbilicus: transumbilical plication technique ²⁴	30	26 to 59 years	X	X	Hassle-free.
Omphaloplasty: “infinity” technique ²⁵	418	21 to 73 years	120 months	91% satisfaction.	9 cases – partial dehiscence (2.1%); 7 cases – stenoses (1.5%); 5 cases – keloids (1.1%).
Neo-omphaloplasty without a scar ²⁶	127	31 to 50 years	4 to 10 months	“All patients monitored and evaluated presented results considered good by the themselves and by the surgeon”.	It does not describe the numbers: partial erasure of the umbilical depression; epidermolysis of the flap dermis.

continue...

...continuation

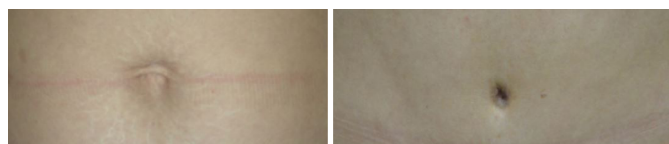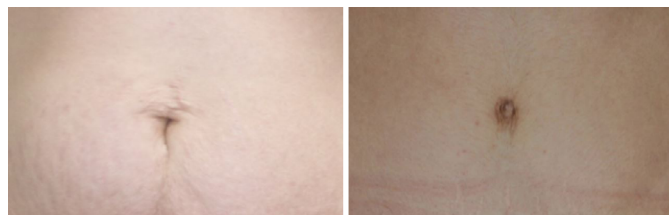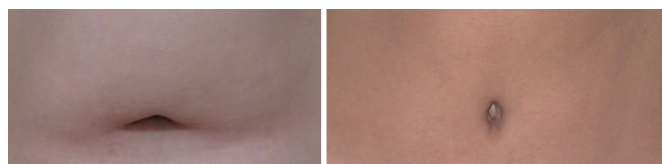
Table 1. Summary of article data included for full reading and analysis.

Article	No. of patients	Age	Time to follow-up	Satisfaction	Complications
Isosceles triangle omphaloplasty with double fixation in abdominoplasty ²⁷	97	25 to 65 years	Up to 12 months	82.5% if felt very satisfied; 10.3% satisfied; 7.2% not very satisfied.	3 cases – stenoses (3%); 2 cases – hypertrophic (2%); 2 cases – atrophic (2%).
Neo-omphaloplasty with X incision in 401 consecutive abdominoplasties ²⁸	401	23 to 67 years	5 to 36 months	43 patients rated their result: 67.4% – Excellent; 23.2% – Very good; 9.3% – Good. Evaluation of surgeons: 77% –Excellent; 18% – Very good; 5% – Good.	16 cases – Infection (3.9%); 11 cases – seroma (2.7%); 6 cases – necrosis (1.5%); 4 cases – hematoma (1%); 2 cases – dehiscence (0.5%).

alternative that would provide more satisfactory results. Thus, in 1998, he published the “H” technique, in which four rectangular flaps are interposed alternately, and the resulting scar presents eight 90-degree changes in direction. Thus, the great advantage of this tactic is the possibility of avoiding tensions and superficializations and being safe regarding the presence of retractions. Furthermore, the technique allows the superficializing or deepening of the navel, with the variation of the perpendicular lines that delimit the flap.

When observed in an orthostatic position, the horizontal scar of the lower flap is deeply positioned unapparent. The more superficial scars are arranged longitudinally in the lateral flaps, and to avoid the appearance of these, also reducing the risk of the navel becoming flat, it must be attached to the aponeurosis.

Neo-omphaloplasty with the H-shaped technique presents a surgical tactic that provides a satisfactory aesthetic result with a deeply located horizontal scar, making it an excellent option in the plastic surgeon’s arsenal (Figures 3 to 5).

**Figure 3.** Female patient, 35 years old, 11 years before and after surgery.**Figure 4.** Female patient, 29 years old, pre- and 2 years after surgery.**Figure 5.** Female patient, 35 years old, pre- and 6-month postoperative period.

CONCLUSION

Omphaloplasty in abdominoplasties can be performed in several ways, providing surgeons with a wide range of alternatives.

The H technique is one of these tools which can be widely used and bring consistent results.

COLLABORATIONS

BFMN Analysis and/or data interpretation, Conception and design study, Conceptualization, Data Curation, Project Administration, Writing - Original Draft Preparation.

LVM Analysis and/or data interpretation, Data Curation.

MSS Data Curation, Writing - Original Draft Preparation.

FV Conceptualization, Supervision.

REFERENCES

1. Cosmetic Surgery National Data Bank Statistics. *Aesthet Surg J.* 2018;38(suppl_3):1-24. DOI: 10.1093/asj/sjy132
2. Papadopoulos NA, Staffler V, Mirceva V, Henrich G, Papadopoulos ON, Kovacs L, et al. Does abdominoplasty have a positive influence on quality of life, self-esteem, and emotional stability? *Plast Reconstr Surg.* 2012;129(6):957e-62e.
3. Akbaş H, Güneren E, Eroğlu U, Uysal OA. Natural-looking umbilicus as an important part of abdominoplasty. *Aesthetic Plast Surg.* 2003;27(2):139-42.

4. Donnabella A. Anatomical reconstruction of the umbilicus. *Rev Bras Cir Plást.* 2013;28(1):119-23.
5. Matarasso A, Matarasso DM, Matarasso EJ. Abdominoplasty: classic principles and technique. *Clin Plast Surg.* 2014;41(4):655-72.
6. Martinez-Teixido L, Serra-Mestre JM, Serra-Renom JM. A new technique for creating a neo-umbilicus in abdominoplasty. *J Plast Reconstr Aesthet Surg.* 2017;70(12):1760-7.
7. Mowlavi A, Huynh PM, Huynh DC, Wilhelmi BJ. A new technique involving a spherical stainless steel device to optimize positioning of the umbilicus. *Aesthetic Plast Surg.* 2012;36(5):1062-5.
8. Bruekers SE, van der Lei B, Tan TL, Luijendijk RW, Stevens HP "Scarless" umbilicoplasty: a new umbilicoplasty technique and a review of the English language literature. *Ann Plast Surg.* 2009;63(1):15-20.
9. Hazani R, Israeli R, Feingold RS. Reconstructing a natural looking umbilicus: a new technique. *Ann Plast Surg.* 2009;63(4):358-60.
10. Lee MJ, Mustoe TA. Simplified technique for creating a youthful umbilicus in abdominoplasty. *Plast Reconstr Surg.* 2002;109(6):2136-40.
11. da Silva Júnior VV, de Sousa FRS. Improvement on the Neo-umbilicoplasty Technique and Review of the Literature. *Aesthetic Plast Surg.* 2017;41(3):600-7.
12. Baack BR, Anson G, Nachbar JM, White DJ. Umbilicoplasty: the construction of a new umbilicus and correction of umbilical stenosis without external scars. *Plast Reconstr Surg.* 1996;97(1):227-32.
13. de Lacerda DJ, Martins DM, Marques A, Brenda E, de Moura Andrews J. Umbilicoplasty for the abdomen with a thin adipose layer. *Br J Plast Surg.* 1994;47(5):386-7.
14. Mazzocchi M, Trignano E, Armenti AF, Figus A, Dessy LA. Long-term results of a versatile technique for umbilicoplasty in abdominoplasty. *Aesthetic Plast Surg.* 2011;35(4):456-62.
15. Kachare S, Kapsalis C, Kachare M, Hiller A, Abell S, Lee TJ, et al. Earplug Umbilicoplasty: A Simple Method to Prevent Umbilical Stenosis in a Tummy Tuck. *Eplasty.* 2019;19:e12.
16. Restrep JAZ, Garcia CP, Mattiello CM, Rendon NB, Duarte FO, Ely JB. Indicações de neo-onfaloplastia em pacientes submetidos a abdominoplastia. *Rev Bras Cir Plást.* 2019;34(0):86-9.
17. Viterbo F. The H technic in omphaloplasty. *Rev Paul Med.* 1988;106(2):85-8.
18. D'Assumpção EA. Technique for umbilicoplastie avoiding one of the most important stigma of abdominoplasties. *Rev Bras Cir Plást.* 2005;20(3):160-6.
19. Nogueira DSC. Routine neoomphaloplasty during abdominoplasties. *Rev Bras Cir Plást.* 2008;23(3):207-13.
20. Pereira JFV, Schutz LV, Kostic V, d'Avila CLP, Mateus FN. Triangular umbilicoplasty with skin flap. *Rev Bras Cir Plást.* 2011;26(3):496-501.
21. Vendramin FS, Fernandes AWC. Umbilicoplastia: técnica com pedículo umbilical em "pipa" e incisão da pele do abdome em "Y". *Rev Bras Cir Plást.* 2019;34(Suppl.3):8-11.
22. Pedroso DB, Soares DAS, Cammarota MC, Daher LMC, Galdino MCA, Santos GC, et al. Umbilicoplasty by vertical incision: description of the technique and assessment of satisfaction. *Rev Bras Cir Plást.* 2017;32(4):534-40.
23. Guimarães VHM, Guimarães VA, Gonçalves FA, Carvalho PCC. Omphaloplasty: Y/V technique. *Rev Bras Cir Plást.* 2018;33(3):355-63.
24. Chia CY, Roxo ACW, Labanca L, Ritter PD. Aesthetic and functional surgery of umbilicus: transumbilicous plication technique. *Rev Bras Cir Plást.* 2011;26(2):293-7.
25. Furtado IR. Omphaloplasty: "infinity" technique. *Rev Bras Cir Plást.* 2011;26(2):298-301.
26. Amud RJM. Omphaloplasty Without Scars. *Rev Bras Cir. Plást.* 2008;23(1):37-40.
27. Campos R, Campos BVBL. Omphaloplasty based on an isosceles triangle with double fixation in abdominoplasty. *Rev Bras Cir Plást.* 2019;34(1):38-44.
28. Cló TCT. Neoomphaloplasty using an X-shaped incision in 401 consecutive abdominoplasties. *Rev Bras Cir Plást.* 2013;28(3):375-80.
29. Mendes FH, Donnabella A, Fagotti Moreira AR. Fleur-de-lis Abdominoplasty and Neo-umbilicus. *Clin Plast Surg.* 2019;46(1):49-60. DOI: 10.1016/j.cps.2018.08.007
30. Craig SB, Faller MS, Puckett CL. In search of the ideal female umbilicus. *Plast Reconstr Surg.* 2000;105(1):389-92.
31. Mendes FH, Viterbo F, Luna ALAP. Inner Scar Umbilicus: New Horizons for Vertical Abdominoplasty. *Plast Reconstr Surg.* 2018;141(4):507e-16e. DOI: 10.1097/PRS.0000000000004258
32. Vernon S. Umbilical transplantation upward and abdominal contouring in lipectomy. *Am J Surg.* 1957;94(3):490-2.
33. Pitanguy I. Abdominallipctomy: an approach to it through an analysis of 300 consecutive cases. *Plast Reconstr Surg.* 1967;40(4):384-91.
34. Grazer FM, Goldwyn RM. Abdominoplasty assessed by survey, with emphasis on complications. *Plast Reconstr Surg.* 1977;59(4):513-7.
35. Rosique MJF, Rosique RG, Lee FDI, Kawakami H, Glatstein N, Mélega JM. Estudo comparativo entre técnicas de onfaloplastia. *Rev Bras Cir Plást.* 2009;24(1):47-51.
36. Avelar J. Abdominoplasty-Systematization of a technique without external umbilical scar. *Aesthetic Plast Surg.* 1978;2(1):141-51. DOI: 10.1007/BF01577947

***Corresponding author:** **Balduino Ferreira de Menezes Neto**
 Rua Doutor Adolfo Pardini Filho, 1028, Chácara Recreio Vista Alegre, Botucatu, SP, Brazil
 Zip Code: 18608-760
 E-mail: balduinofmneto@gmail.com