

Tarsoconjunctival Flap in Total Plane Oncology Reconstructions of the Eyelids

Patrícia Breder de Barros, MD¹

Rafael Anlicoara, MD²

Paulo Roberto de Albuquerque Leal, MD³

- 1] Member of the SBCP, former-resident of the Plastic Surgery and Reconstructive Microsurgery Service of the Instituto Nacional de Câncer.
- 2] Second Year Medical Resident of the Plastic Surgery and Reconstructive Microsurgery Service of the Instituto Nacional de Câncer.
- 3] Member of the SBCP and Head of the Plastic Surgery and Reconstructive Microsurgery Service of the Instituto Nacional de Câncer.

Instituto Nacional de Câncer – Plastic Surgery and
Reconstructive Microsurgery Service

Address for correspondence:

Patrícia Breder de Barros, MD

Pça. Cruz Vermelha, 23 – 8º andar
20230-130 – Rio de Janeiro – RJ
Brazil

Phone: (55 21) 2506-6087

Keywords: Lid reconstruction; Hughes flap; tarsoconjunctival.

ABSTRACT

The authors present the results obtained with the tarsoconjunctival flap technique in eyelid reconstructions of total plane defects and affecting more than 50% of the horizontal length of the lower eyelid.

They describe how the method was used in 40 cases and discuss major aspects in the evolution of the procedure.

They conclude by defending the utilization of the method as the technique of choice in complex lid lesions due to its satisfactory aesthetic and functional results.

INTRODUCTION

Two major objectives should be observed in lid reconstructions: functional integrity and aesthetic quality. What technique to use depends on how much the anatomy is affected as a consequence of tumor resec-

tion; thus, site and dimensions are important. In superficial defects, only the anterior lamella needs to be repaired. Total width defects, however, demand reconstruction of the anterior and posterior lamellae.

The tarsoconjunctival flap, described by Hughes⁽¹⁾ in 1937, has proved to be a suitable option for reconstructions of total width lid defects and has the major advantage of enabling the reconstruction to be performed with the lid tissue itself.

METHODS

The present study assessed 40 patients operated successively at the Instituto Nacional de Câncer – Plastic Surgery and Reconstructive Microsurgery Service, from February 1997 to January 2002. The sample was made up of patients with lower lid skin tumors whose treatment led to defects of at least 50% of the horizontal length of the total width of the structure (involvement of anterior and posterior lamellae).

OPERATIVE TECHNIQUE

Initially the tumor is identified (Fig. 2) and resected according to oncology safety standards (Fig. 3).

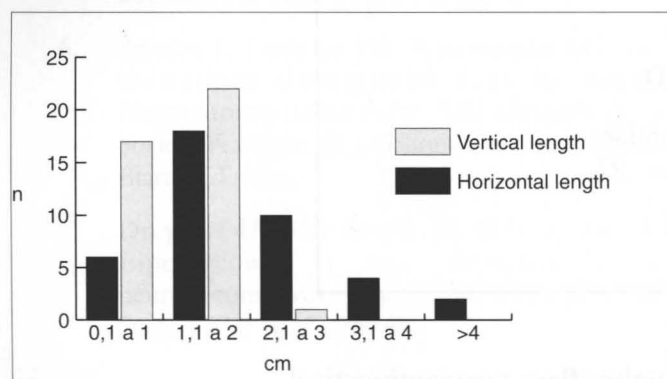


Fig. 1 – Measurements of lid defects.

Table I

Procedure	Cases
Graft Superior contralateral lid skin	19
Graft Superior contralat lid skin. + retroauricular skin	1
Graft Superior ipsilateral + contralateral lid skin	1
Graft Ipsilateral superior lid skin	3
Graft Retroauricular skin	5
Graft Supraclavicular Skin	4
Flap Glabella	1
Flap Musculocutaneous of upper lid	2
Flap Mustardé	1
Flap Mustardé + mediofrontal	1
Flap Nasogenian	1
Graft + Flap Upper contralateral lid skin + Nasogenian flap	1

Reconstruction of the anterior lamella - procedures used.

The upper lid is then everted, and the measures of the defect transported to the donor area, taking into account that the flap should be less than 1/4 of the original defect in size in order to spare the donor area.

Once the flap is designed (Fig. 4) and infiltrated with a 1: 200.000 vasoconstrictor, it begins to be freed by means of a 2 to 3 mm horizontal incision of the lash margin and by lateral vertical incisions up to almost the whole vertical length of the tarsus. Detachment begins posterior to the tarsal plate, freeing the flap of the Müller muscle/elevator complex, in order to preserve the upper lid elevator mechanism.

Finally, the flap is transposed to the defect (Fig. 5), fixing it with separate sutures of polyglycolic acid 6-0.

Once the posterior lamella is repaired and has its own blood supply, the anterior lamella is reconstructed. A total skin graft was used in the case demonstrated (Fig. 6).

An occlusive dressing is used after a Brown dressing for graft cases.

Lids remain sutured occluding the eyeball completely for a minimum of 3 weeks, when the flap pedicle is sectioned 1 mm above the border of the lid, and the neo-border lid is sutured with a continuous technique using polyglycolic acid 6-0.

RESULTS

There were a total of 40 cases, 35 of which females (70%) and 15 males, with ages ranging between 35 and 87 years.

Basocellular Carcinoma was the most frequent tumor found, with 36 cases (89%), followed by Spinocellular Carcinoma, 3 cases (8%), and then only 1 case (3%) of Trichoblastic Carcinoma.

In relation to the size of the defects, most cases were in the 1.1 to 2.0 cm range, both in the horizontal and vertical length (Fig. 1).

Satisfactory aesthetic and functional results were reached (Fig. 7), based on satisfactory occlusion and balance of the lid border.

The reconstruction of the anterior lamella was performed with total skin grafts, local flaps or an association of them, as may be observed in Table I.

The interval for cutting the pedicle ranged from 3 to 6 weeks, with a mean of 37 days, for reasons not related to the technique.

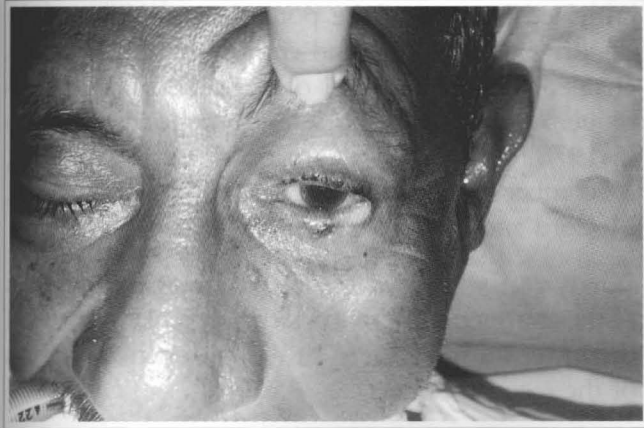

Fig. 2 - Identification of the tumor, affecting practically the whole horizontal extent of the lower lid and lash border.

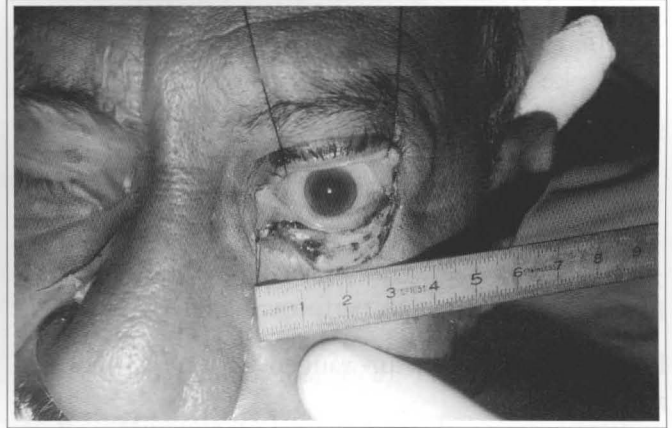


Fig. 3 - Defect caused by resecting the tumor with safety margins.

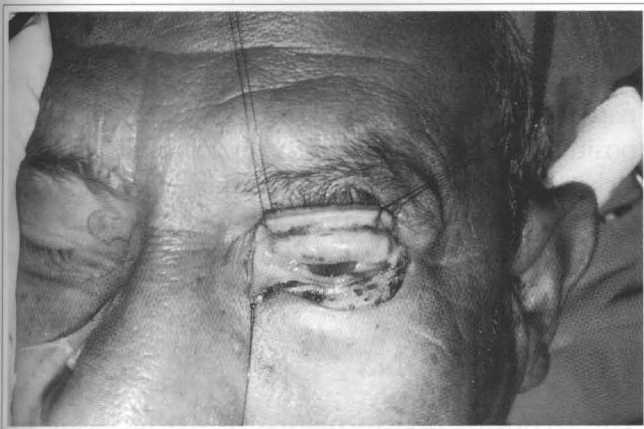

Fig. 4 - Flap planning.

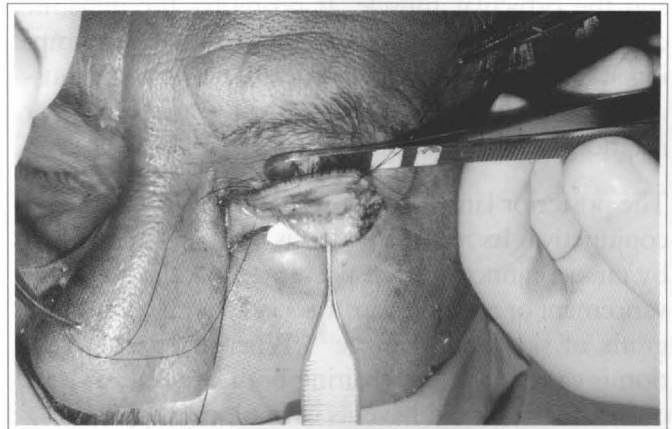


Fig. 5 - Transposition of flap, detaching it from the Müller muscle/ elevator complex.

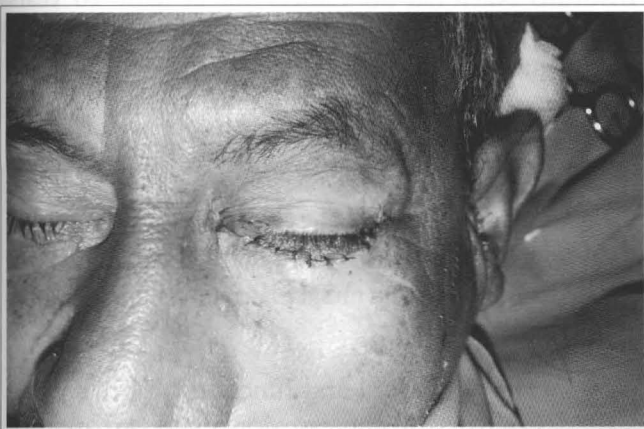

Fig. 6 - Reconstruction of the anterior lamella with total skin graft.

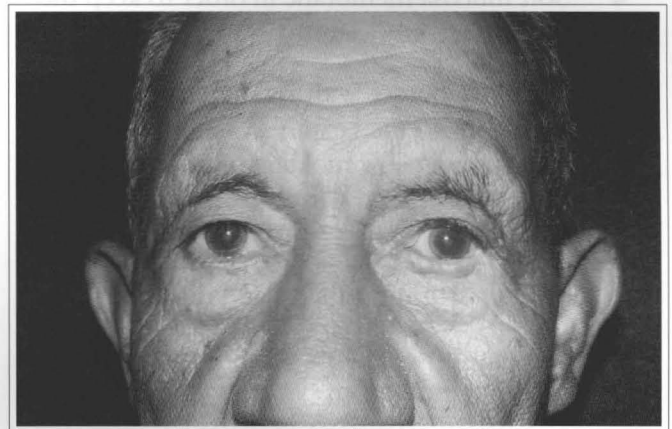


Fig. 7 - Two-month postoperative of patient with excellent aesthetic and functional result, in addition to oncological cure.

The complications observed were:

- ◆ 1 case of conjunctival hyperemia that evolved with satisfactory final results after utilization of lubricating eye drops.
- ◆ 1 case of infection, in which the flap had to be repositioned to the donor area and the reconstruction reprogrammed.
- ◆ 1 case of ectropium, treated with canthopexy and skin auto-grafting.
- ◆ 1 case of external canthus synechia, in which cantholysis was performed.

Post-operative follow-up ranged between 2 months and 4 years.

DISCUSSION

The anterior lamella of the lids is represented by skin and the orbicular muscle. It promotes the dynamic closure of the lids and contributes to the tear pumping system. It can be reconstructed with skin or musculocutaneous flaps by advancement, transposition or rotation or with total skin grafts⁽²⁾.

The posterior lamella is comprised by the tarsum and conjunctiva. Its reconstruction is normally performed by tarsoconjunctival transposition, in addition to advancement or rotation flaps associated with compound grafts of skin and cartilage⁽²⁾. When the reconstruction is carried out by repairing both lamellae, at least one of them should have its own blood supply.

Other objectives to be achieved are⁽²⁾:

- ◆ Soft mucosa membrane in order to keep the eye surface lubricated.
- ◆ Stable lid border with rigid skeletal support, equivalent to the tarsum to assure shape and stability, but allow molding of the eyeball and keeping lashes and skin away from the cornea.
- ◆ Fixation to medial and lateral canthus ligaments, assuring stability and direction.
- ◆ Adequate musculature to allow for tonus and complete occlusion.
- ◆ Thin flexible skin for efficient lid excursion.
- ◆ Adequate elevating action to elevate the up-

per lid above the visual axis.

In 1937, Hughes⁽¹⁾ described the tarsoconjunctival flap for central lower lid total plane defects with the upper lid as the donor area. The original technique was criticized because of the potential morbidity of the donor area: retraction and entropion. Other studies enabled the current level of perfection of the technique. Among the authors, are: Hughes himself who in 1976⁽³⁾, published a revision of technical details, Macomber *et al.*⁽⁴⁾, Cies and Barlett⁽⁵⁾, Pollock *et al.*⁽⁶⁾, McCord and Nunery⁽⁷⁾.

Lowry *et al.*⁽⁸⁾ carried out electromyography studies of the contracting activity of the orbicular muscles of the lower lid in order to show the functional results of the reconstruction.

The routine at the Instituto Nacional de Câncer, for cases with total plane losses of more than 50 % is the tarsoconjunctival flap to reconstruct the posterior lamella. The anterior lamella is repaired by skin grafts or local flaps.

Historically, Mustardé⁽⁹⁾ has criticized the indiscriminate use of the upper eyelid as a donor in flap transposition for lower lid defects. The concept, however, lacks consistency in relation to the technique discussed in the present study, because, in addition to excellent functional results in the lower lid, no major changes are observed in the upper lid.

CONCLUSIONS

The reconstruction technique of the lid using the tarsoconjunctival flap has been used by the Plastic Surgery Repair and Microsurgery Service of the Instituto Nacional do Câncer for at least 10 years. The cases presented were operated on and followed by the authors, who concluded that:

- ◆ The technique described has proved to be a safe and simple procedure for four years.
- ◆ The reconstruction of all eyelid planes is fully achieved when a conjunctival membrane, a rigid element (tarsal plate) and skin are available.
- ◆ The aesthetical and functional aspects were evaluated in the cases operated on, and no sequelae or alterations resulting from the technique were observed.

- ◆ The quality of the results maintained during the observation period allowed the authors to conclude that the method is the first option in total plane and larger than 50 % lid defects.

REFERENCES

1. Hughes WL. A new method for rebuilding a lower lid: Report of a case. *Arch Ophthalmol.* 1937; 17:1008-12.
2. Backer SR, Swanson MD. Local flaps in facial reconstruction. 1 ed. Missouri: Mosby;1995.
3. Hughes WL. Total lower lid reconstruction: Technical details. *Trans Am Ophthalmol Soc.* 1976; 74:321-5.
4. Macomber WB, Wang MK, Gottlieb E. Epithelial tumors of the eyelids. *Surg Gynecol Obstet.* 1954; 98:331-9.
5. Cies WA, Barlett RE. Modification of the Mustardé and Hughes methods of reconstructing the lower lid. *Ann Ophthalmol.* 1967; 7:1497-510.
6. Pollock WJ, Colon GA, Ryan RF. Reconstruction of the lower lid by a different lid-splitting operation. *Plast Reconstr Surg.* 1972; 50:184-201.
7. McCord CD Jr., Nunery WR. Reconstructive Procedures of the lower eyelid and outer canthus. In C. D. McCord Jr. (Ed.), *Oculoplastic Surgery.* New York: Raven Press; 1981. p.194-8.
8. Lowry JC, Bartley GB, Litchy WJ. Electromyographic studies of the reconstructed lower eyelid after a modified Hughes procedure. *Am J Ophthalmol.* 1995; 119-225.
9. Mustardé JC. *Cirurgía reparadora y reconstructora de la región orbital.* 1 ed. Barcelona: Ediciones Toray; 1982.