



Inferior pedicle nasolabial flap in nasal ala reconstruction

Retalho nasogeniano de pedículo inferior na reconstrução de asa nasal

MARCELO ROSSETO^{1,2*}
DANIEL NUNES E SILVA²
ANA LUIZA CEOLIN LYRIO³
ANA LARA CEOLIN LYRIO⁴
ANTÔNIO CAVICHINI
ROSSETO⁵

■ ABSTRACT

Introduction: The nasal alar has always been a major reconstructive difficulty, and in the search for a flap with skin characteristics similar to this one, we came across the inferiorly based nasolabial flap. The objective of this study was to demonstrate the viability of the proposed flap for reconstruction of the nasal alar after removal of skin tumors. **Methods:** This study analysed twenty cases of inferiorly based nasolabial flap performed with the same surgical technique in the period between 2008-2019 and followed up for one year of postoperative. **Results:** Of the 20 studied cases, 13 (65%) did not present complications, being the most described: partial defect coverage and partial disappearance of the nasolabial sulcus. **Conclusion:** The inferiorly based nasolabial flap proved to be a viable flap for nasal alar reconstruction due to the quality of the skin, easy execution, and minimal complication rates.

Keywords: Skin neoplasms; Carcinoma, basal cell; Surgical flaps; Nasal surgical procedures; Reconstructive surgical procedures.

■ RESUMO

Introdução: A asa nasal sempre foi uma grande dificuldade reconstrutiva e, na busca de um retalho com características da pele semelhantes a esta, deparamos com o retalho nasogeniano de pedículo inferior. O objetivo do trabalho foi demonstrar a viabilidade do retalho proposto para reconstrução da asa nasal após a retirada de tumores cutâneos. **Métodos:** Foram analisados 20 casos de retalho nasogeniano de pedículo inferior realizados com a mesma técnica cirúrgica no período entre 2008 e 2019 e acompanhados por um ano de pós-operatório. **Resultados:** Dos 20 casos estudados, 13 (65%) não apresentaram complicações, sendo as mais relatadas: cobertura parcial do defeito e desaparecimento parcial do sulco nasogeniano. **Conclusão:** O retalho nasogeniano de base inferior mostrou ser um retalho viável à reconstrução da asa nasal pela qualidade de pele, fácil execução e índices mínimos de complicações.

Descritores: Neoplasias cutâneas; Carcinoma basocelular; Retalhos cirúrgicos; Procedimentos cirúrgicos nasais; Procedimentos cirúrgicos reconstrutivos.

Institution: Campo Grande
Alfredo Abrao Cancer Hospital,
Plastic Surgery Service, Campo
Grande, MS, Brazil.

Submitted article: March 5, 2021.
Article accepted: July 14, 2021.

Conflicts of interest: none.

DOI: 10.5935/2177-1235.2022RBCP0005

INTRODUCTION

The first descriptions of flaps in the history of plastic surgery (6th century BC) were for nasal reconstruction in ancient India; the technique became known as the mid-frontal flap or the Indian method. Gaspare Tagliacozzi, in 1597, described a new option for nose reconstruction: a direct cutaneous flap of the

upper limb called the Italian method¹. Dieffenbach described the nasolabial flap and Converse the scalp flap based on the superficial temporal artery²⁻⁴.

The nasal ala has always been a major reconstructive difficulty due to its thin skin, which, after being reconstructed, normally required surgical refinements for a better appearance. Looking for an alternative to correct these defects, in which the skin would present similar

¹ Campo Grande Alfredo Abrao Cancer Hospital, Plastic Surgery Service, Campo Grande, MS, Brazil.

² Federal University of Mato Grosso do Sul, Plastic Surgery, Campo Grande, MS, Brazil.

³ State University of Mato Grosso do Sul, Medicine, Campo Grande, MS, Brazil.

⁴ Anhanguera-Uniderp University, Medicine, Campo Grande, MS, Brazil.

⁵ University of Marília, Medicine, Marília, SP, Brasil.

characteristics of the nasal ala and allow reconstruction in a single surgical procedure, we came across the nasolabial flap with an inferior pedicle.

OBJECTIVE

To demonstrate the viability of the inferior nasolabial flap for nasal ala reconstruction after removal of skin tumors.

METHODS

The study was carried out with primary data obtained from a retrospective study of 20 cases of nasal alar reconstruction using an inferior pedicle nasolabial flap, after removal of basal cell carcinoma, in the period between 2008 and 2019. The patients were operated on at the Hospital de Câncer de Campo Grande Alfredo Abrao, MS. The results of the immediate postoperative period were analyzed, with seven, 30 and 90 days after surgery and after 1 year and the occurrence or not of complications.

We selected the cases of patients with tumors restricted to the nasal ala, who had been previously biopsied with a positive diagnosis for basal cell carcinoma and who agreed to sign the Free and Informed Consent Form. The Ethics Committee approved the study of the Hospital de Câncer de Campo Grande Alfredo Abrão (n.º 002.2021).

Surgical technique

After demarcating the tumor with oncological safety margins with methylene blue, the tumor area was anesthetized with modified Klein's solution [100 ml of 0.9% SF + 1 ampoule of adrenaline (millesimal solution) + 20 ml of lidocaine at 2 % (without vasoconstrictor) + 4 ml of 8.4% Na+ bicarbonate] + infraorbital nerve block associated with sedation with midazolam and fentanyl performed by the anesthesiologist.

After vasoconstriction, the tumor was resected, and rigorous hemostasis of the excised area was performed.

The search for thin skin, similar to that of the nasal ala, led us to use the skin of the lateral nasal dorsum. We demarcated the flap to be made, extending from the nasal ala to the inner corner of the eye, preserving the area of the internal canthal ligament and the lacrimal duct. Then, we made the inferior pedicle nasolabial skin flap (Figure 1A) and rotated it to its new bed (Figure 1B), in which it was sutured with 5.0 nylon. After slight detachment and hemostasis, the donor area was sutured with 4.0 vicryl and 5.0 nylon, generating a scar without tension (Figure 1C).

The excised tumor was sent for anatomopathological examination to confirm the safety margins.

RESULTS

During 11 years, 20 cases of patients needing nasal ala reconstruction after basal cell carcinoma excision were analyzed and operated on, 13 (65%) were male, and 7 (35%) were female. The age of the patients ranged between 45 and 80 years, with 50% in the age group from 61 to 70 years. All patients presented Fitzpatrick between I and III. Only 7 (35%) required refinements for the operated patients, performed in only one additional surgical time (Figure 2). In the immediate postoperative period, two patients had partial coverage of the defect, and another two patients had complications, one being an infection and the other an unsightly staining of the flap.

At the consultation after 60 days, one patient evolved with an unsightly scar, and two had partial disappearance of the nasolabial fold. In the follow-up up to one year after the surgeries, thirteen patients (65%) did not present any complications, and no patient evolved with necrosis (Figure 3).

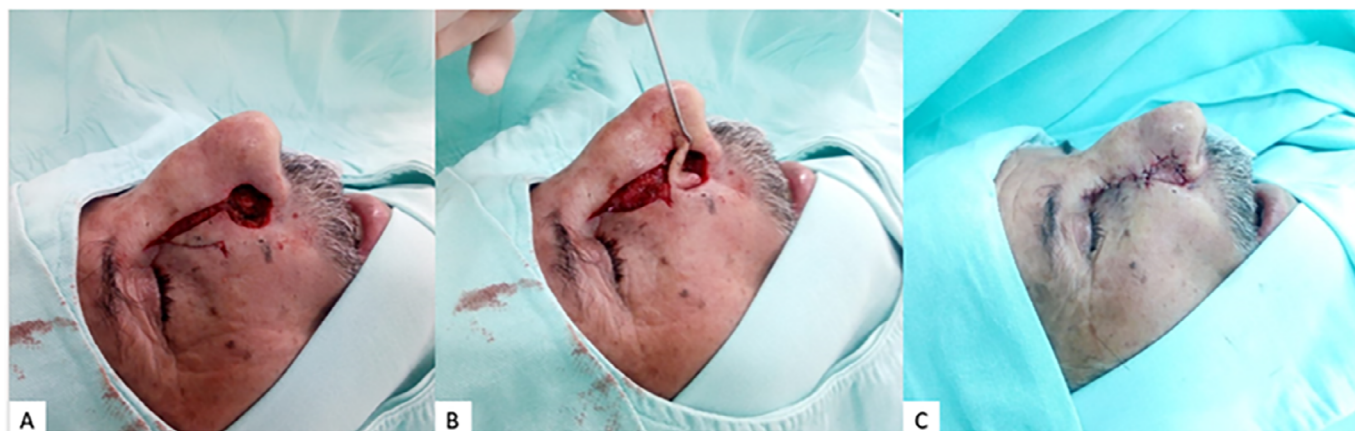

Figure 1. Technical sequence of transposition flap. A: Tumor excision and flap creation; B: Rotation of the flap; C: Immediate postoperative period.

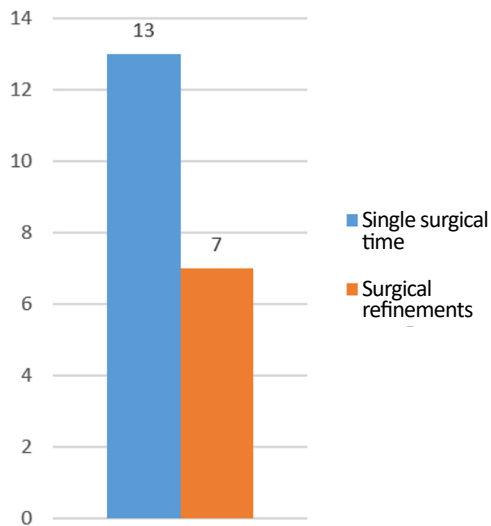


Figure 2. Distribution of patients by the need for surgical refinement (N=20).

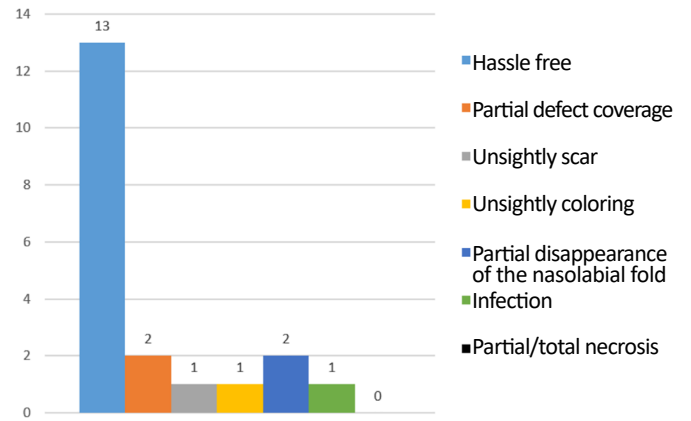


Figure 3. Complications in the postoperative flaps (N=20).

Figures 4 and 5 illustrate the surgical technique, and Figures 6 and 7 illustrate the long-term follow-up of some cases in the series.

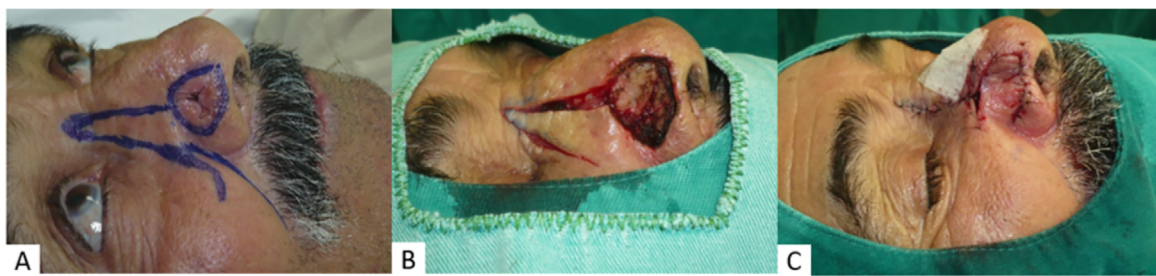

Figure 4. A: Demarcation of the retractor; B: Tumor excision and flap creation; C: Immediate postoperative period.

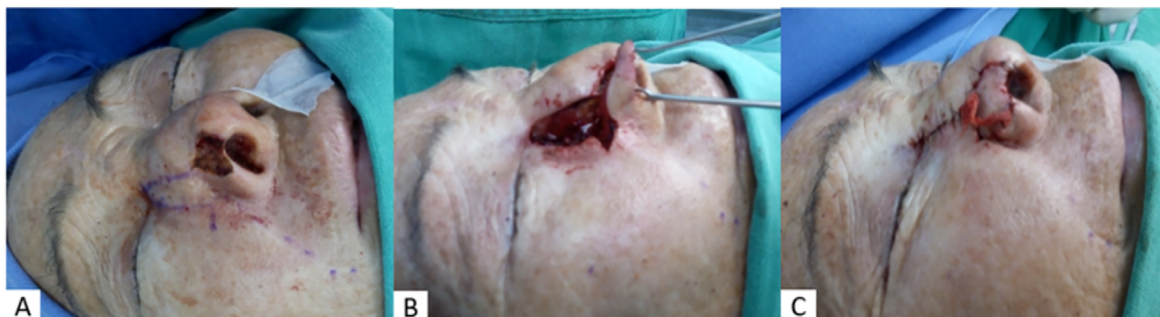

Figure 5. A: Tumor excision and flap demarcation; B: Fabrication and rotation of the flap; C: Immediate postoperative period.

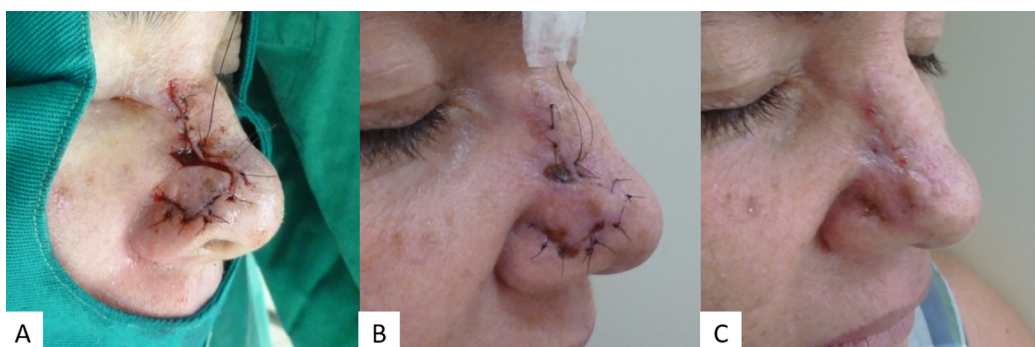


Figure 6. A: Immediate postoperative period; B: Seven postoperative days; C: 30 days after surgery.

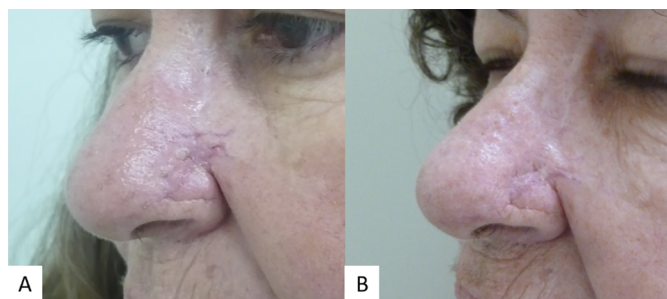


Figure 7. A: Postoperative period of 90 days; B: One-year postoperative period.

DISCUSSION

In the literature, there is a large arsenal described for nose reconstruction. However, due to its limits and concave shape, the nasal ala represents a challenge for the surgeon to preserve its function allied to a satisfactory aesthetic result.

Some authors reported the bilobed flap (44%) as the most used for this nasal subunit (nasal wing), followed by the VY flap and the superior pedicle nasolabial flap⁵; other authors reported a predominance of the use of the superior pedicle nasolabial flap (55.84%)^{6,7}. In the present study, we did not find, in the literature, a case series of the inferior pedicle nasolabial flap to serve as a comparison with our work.

The inferior pedicle nasolabial flap is based, in the design, on the Limberg rhomboid flap. This one, which considers the resection area as a diamond, proposes making the flap parallel to one of the four axes of the lesion, making the “V” of the donor area close by approximation when rotating the flap. The inferior pedicle nasolabial flap, in essence, is the Limberg flap designed in the most suitable axis for the correction of the nasal ala defect.

Skin thickness is one of the limiting factors for the reconstruction to be aesthetically similar to that of the nasal ala. The mid-frontal flap is an option for major reconstructions that encompass more than half of the nose, including the nasal wings, being described as the most appropriate for safety, amount of skin obtained and similarity in skin characteristics⁸; however, it requires several refinement surgeries in Caucasian patients for esthetic improvement due to the thickness of this flap. Despite its limited coverage area, the inferior pedicle nasolabial flap, being restricted to defects in the nasal ala, presented a skin thickness practically compatible with the anterior thickness, not requiring refinements to thin the flap in 70% of the cases performed.

According to Gokrem et al.⁹, the VY myocutaneous advancement flap is an option for nasal reconstruction of small and medium defects, avoiding the disadvantages of the frontal flap and presenting the advantages of

safety and similar characteristics between the donor and recipient areas, and can be used in various regions of the nose. However, it requires great experience from the surgeon to guarantee the viability of this flap due to the narrow pedicle. In contrast, the inferior pedicle nasolabial flap is easy to make, not requiring great experience on the surgeon's part to perform it.

According to Laitano et al.⁵, the bilobed flap has the advantage of being a simple procedure, performed in a single stage, with good aesthetic and functional results and a high degree of patient acceptance, unlike the superior pedicle nasolabial flap. The bilobed flap for nasal alar reconstruction showed the same specificities compared to the inferior pedicle nasolabial flap.

The interpolation flap for nasal ala correction, cited by Sakai et al.¹⁰, promotes the preservation of the nasolabial fold; however, when the patient is male, hair follicles may be transferred, which does not happen with the inferior pedicle nasolabial flap because their skin does not contain hair follicles.

CONCLUSION

The inferior base nasolabial flap proved to be a viable flap for nasal ala reconstruction due to the quality of the skin, easy execution and minimal complication rates.

COLLABORATIONS

MR	Conception and design study, Final manuscript approval, Methodology, Realization of operations and/or trials, Supervision, Writing - Review & Editing
DNS	Analysis and/or data interpretation, Final manuscript approval, Writing - Review & Editing
ALCL	Analysis and/or data interpretation, Final manuscript approval, Visualization, Writing - Original Draft Preparation, Writing - Review & Editing
ALCL	Final manuscript approval, Writing - Original Draft Preparation, Writing - Review & Editing
ACR	Analysis and/or data interpretation, Final manuscript approval, Writing - Review & Editing

REFERENCES

1. Mélega JM, Viterbo F, Mendes FH. Cirurgia plástica: os princípios e a atualidade. Rio de Janeiro: Guanabara Koogan; 2011.

2. Ferreira LM. Cirurgia Plástica. Guias de Medicina Ambulatorial e Hospitalar – Unifesp Escola Paulista de Medicina. São Paulo: Manole; 2007. p 3-11; 355-60; 663-83.
4. Herbert DC, Harrison RG. Nasolabial subcutaneous pedicle flaps. *Br J Plast Surg*. 1975;28(2):85-9.
5. Converse JM. Reconstruction of the nose by the scalping flap technique. *Surg Clin North Am*. 1959;39(2):335-65.
6. Laitano FF, Teixeira LF, Siqueira EJ, Alvarez GSe, Martins PDE, Oliveira MP. Uso de retalho cutâneo para reconstrução nasal após ressecção neoplásica. *Rev Bras Cir Plást*. 2012;27(2):217-22.
7. Souza Filho MV, Kobig RN, Barros PB, Dibe MJA, Leal PRA. Reconstrução nasal: análise de 253 casos realizados no Instituto Nacional de Câncer. *Rev Bras Cancerol*. 2002;48(2):239-45.
8. Moura BB, Signore FL, Buzzo TE, Watanabe LP, Fischler R, Freitas JOG. Reconstrução nasal: análise de série de casos. *Rev Bras Cir Plást*. 2016;31(3):368-72.
9. Cintra HPL, Bouchama A, Holanda T, Jaimovich CA, Pitanguy I. Uso do retalho médio-frontal na reconstrução do nariz.. *Rev Bras Cir Plást*. 2013;28(2):212-7.
10. Gokrem S, Tuncali D, Akbuga U, Terzioglu A, Aslan G. Reconstruction of small to medium defects in the soft tissues of the nose with nasalis musculocutaneous V-Y advancement flaps. *Scand J Plast Reconstr Surg Hand Surg*. 2006;40(3):140-7. DOI: 10.1080/02844310500491575
11. Sakai RL, Tavares LCV, Komatsu CA, Faiwichoq L. Retalho nasogeniano de interpolação na reconstrução da asa nasal após ressecção de tumores cutâneos. *Rev Bras Cir Plást*. 2018;33(2):217-21.

Corresponding author:*Marcelo Rosseto**

Rua Raul Pires Barbosa, 1477, Chácara Cachoeira, Campo Grande, MS, Brazil

Zip Code 79040-150

E-mail: marcelorosseto@yahoo.com.br