

Giant Dermatofibrosarcoma Protuberans

César Silveira Cláudio-da-Silva, MD¹
Luiz César Boghossian, MD¹
Luiz Fernando Fernandes Gonçalves, MD²
Diogo Franco, MD²
Talita Franco, MD³

- 1] Staff members, Plastic Surgery Service of the Hospital Universitário Clementino Fraga Filho, UFRJ
- 2] Resident physicians, Plastic Surgery Service of the Hospital Universitário Clementino Fraga Filho, UFRJ
- 3] Chief, Plastic Surgery Service of the Hospital Universitário Clementino Fraga Filho, UFRJ

Work performed by the Plastic Surgery Service of the
Hospital Universitário Clementino Fraga Filho,
UFRJ

Address for Correspondence:

Talita Franco, MD
Rua Ramon Franco, 98 - Urca
Rio de Janeiro - RJ - Brazil
22290-290

ABSTRACT

Dermatofibrosarcoma protuberans is a rare malignant skin tumor, locally aggressive. It has a high rate of local recurrence but metastasis is very rare. Aggressive excision is required with a surgical margin of at least 3 cm. The authors analyse a remarkable case weighing 3850 g and measuring 28 x 23 x 16 cm, on the upper limb of a male patient, treated at the Plastic Surgery Service of the Hospital Universitário Clementino Fraga Filho (UFRJ), in 1993.

A retrospective study of this pathology, performed at the same Service between January 1984 and May 1994, detected other four cases sited in different areas of the body and which were also surgically treated.

Using data from the pertinent literature, the authors discuss the etiopathogenic aspects and the treatment methods of this tumor which, in addition to its rarity, presents special characteristics as to size, malignity and evolution.

INTRODUCTION

Dermatofibrosarcoma protuberans was described for the first time in 1924 by Darier and Ferrand, who recognized it as a clinical entity and named it "Progressive Recurrent Dermatofibroma" or "Skin Fibrosarcoma"

(2). In 1925, Hoffman was the first to utilize the term "Dermatofibrosarcoma protuberans" (5). The diagnosis was based on the patient's clinical history and the macroscopic aspects of the lesion until 1962, when

TABLE 1

Age	Sex	Site	Lesion size (cm)	Surgical margins	Evolution
34	M	Thorax (posterior)	4,5	Peripheral - 4 cm Depth - aponeurotic fascia	Surgery - January 1984 Last evaluation: August 1984 WELL
42	F	Thorax (anterior)	4,0	Peripheral - 2 cm Depth - subcutaneous	Surgery - July 1991 Last evaluation: August 1992 WELL
48	F	Front area - recurrence from surgery performed 15 years ago	1,5	Peripheral - 1 cm Depth - periosteum	Surgery - February 1994 Last evaluation: May 1994 WELL
42	M	Thorax (anterior) - recurrence after one year of a surgery performed in 1987	9,0	—	In preoperative stage

QUADRO 1

Idade	Sexo	Localização	Tamanho da Lesão (cm)	Margens Cirúrgicas	Evolução
34	M	Tórax (posterior)	4,5	Periférica - 4 cm Profundidade - fásia aponeurótica	Cirurgia - jan/1984 Última consulta: ago/1984 Bem
42	F	Tórax (anterior)	4,0	Periférica - 2 cm Profundidade - subcutâneo	Cirurgia - jul/1991 Última consulta: ago/1992 Bem
48	F	Região frontal recidiva de cirurgia há 15 anos	1,5	Periférica - 1 cm Profundidade - periósteo	Cirurgia - fev/1994 Última consulta: mai/1994 Bem
42	M	Tórax (anterior) recidiva, 1 ano após, de cirurgia feita em 1987	9,0	—	Em pré operatório

Taylor and Helwig thoroughly described its microscopical characteristics⁽¹²⁾.

This kind of sarcoma represents 0.1% of all malignant tumors⁽¹⁾.

Rutgers and colleagues, in 1992, presented an extensive literature review with 913 cases. In this report, the primary size of the tumor ranges from 1 to 8 cm⁽⁹⁾. Taylor and Helwig (1962), in a series of 115 cases, describe the largest tumor as presenting a 12 cm diameter⁽¹²⁾.

The tumor histopathogenesis is quite controversial. Histological and ultrastructural data and tissue cultures point to a fibrohistiocytic origin^(7, 12). Others have suggested a neurogenic derivation, based on morphological characteristics and electron microscopy^(3, 4). Recent cytogenetic studies associate this pathology with chromosomal aberrations⁽¹¹⁾.

The tumor presents a locally aggressive behaviour and infiltrative

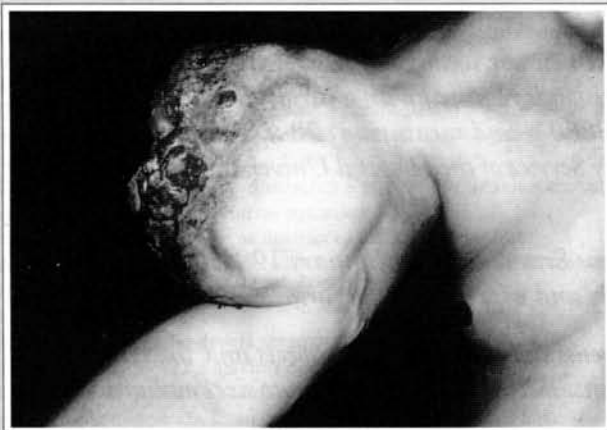

Fig. 1 - View of the ulcerated lesion, with 28 x 23 x 16 cm in measure and which weighed, after being removed, 3850 g. Intense collateral circulation, as it can be observed at the arm internal side and at the clavicular area.

Fig. 1 - Aspecto da lesão, ulcerada, com 28 x 23 x 16cm de extensão e que pesou, ao ser retirada, 3850g. Circulação colateral intensa, como se pode notar na face interna do braço e na região clavicular.

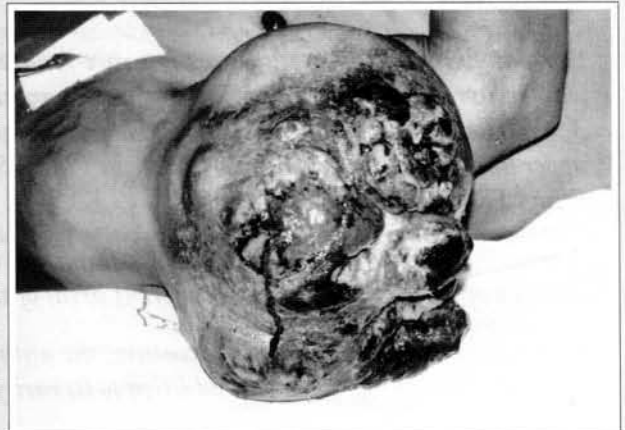

Fig. 2 - Another view of the tumor, with the catheter introduced in the subclavian artery to perform the nourishing vessels embolization.

Fig. 2 - Outro aspecto do tumor, observando-se o catéter introduzido na artéria subclávia.

growth. Local recurrences are frequent but the metastasis are rare. It may affect any area of the body, particularly the thorax and proximal extremities, and is more frequent in males between the second and fifth decades in life.

The case described in this work was chosen on account of its characteristics as a giant tumor which rapidly reached extremely large dimensions in an upper limb. The tumor occurrence on limbs determines major hindrances, due to the circulatory problems it may cause and the difficult covering of the bloody area after the tumor removal.

CASE REPORT

A.C.S., 38, male, sought our Service in October 1992, presenting a primary multinodular tumor at the proximal third of the right upper limb. The clinical picture had begun 30 months ago with a small hardened cutaneous nodule, which evolved slowly during 12 months. After this period the lesion began to grow rapidly and became vegetative, in a torus formation, erythematous, friable, partially covered by a fetid seropurulent secretion, with some ulcerations, small necrose areas and increased local vascularization. At the patient's first visit to our Service the tumor had 28 x 23 x 16 cm in measure and 3,850 grams in weight

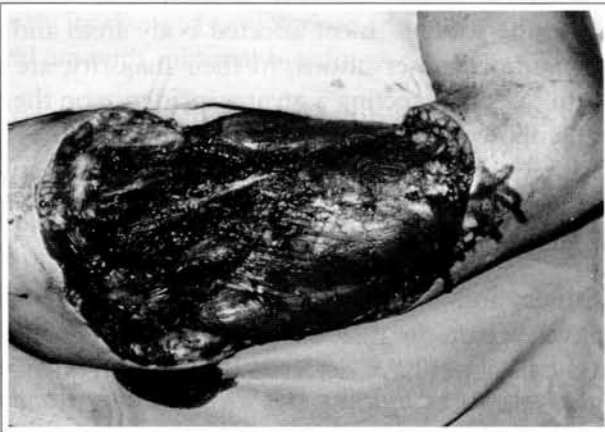


Fig. 3 – Immediate post-operative period, showing the extension of the resection which partially included the deltoid muscle.

Fig. 3 - Pós-operatório Imediato, evidenciando a extensão da ressecção que incluiu parte do músculo deltóide.

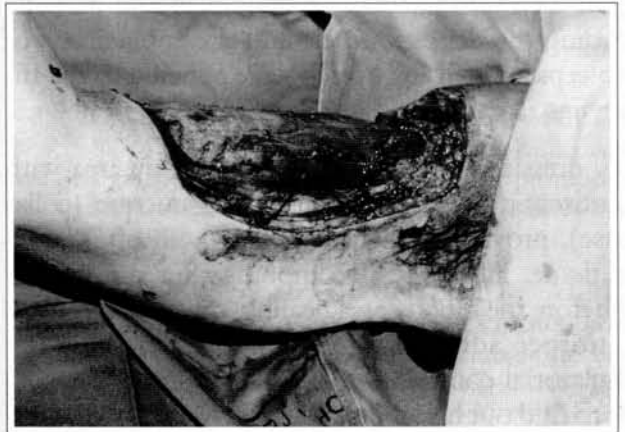

Fig. 4 – A strip of sane skin remained at the arm internal side, protecting the limb vasculoneural bundle.

Fig. 4 - Na face interna do braço restou faixa de pele sã, protegendo o feixe vasculo-nervoso do membro.

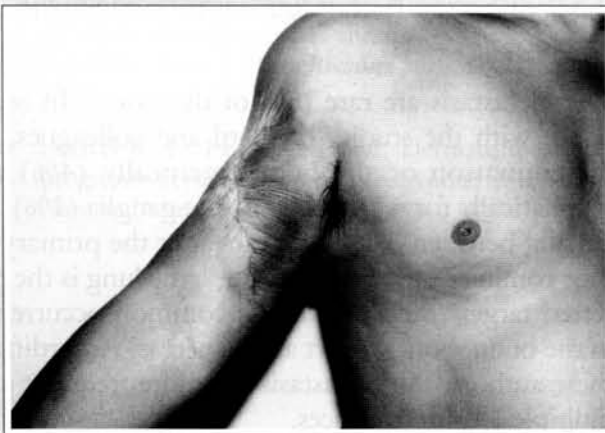


Fig. 5 – After one year post-operative, the area completely healed by second intention, with no local recurrences nor metastasis.

Fig. 5 - Com um ano de pós-operatório, observa-se região totalmente cicatrizada por segunda intenção, sem recidivas locais ou metástases.

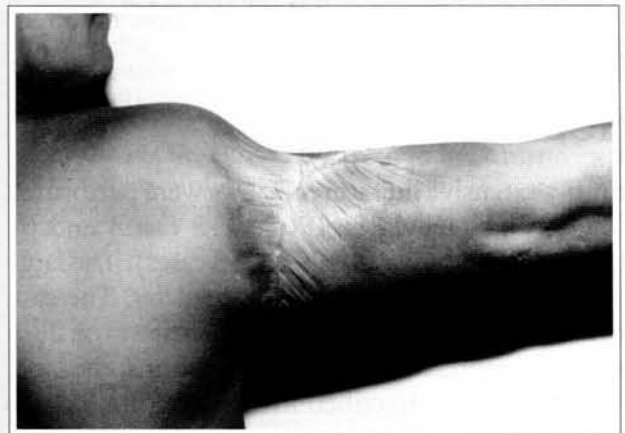


Fig. 6 – View of the arm posterior side, showing only a discreet restriction of the arm raising beyond the horizontal plane.

Fig. 6 - Aspecto da face posterior do braço, notando-se apenas discreta restrição da elevação do braço além da horizontal.

(fig. 1).

In June 2nd, 1993 an arteriography was performed, showing a hypervascularized mass nourished mainly by the first muscular branch of the right brachial artery.

In July 16, 1993, the embolization of the two arterial pedicles which nourished the tumoral mass was performed with a polyvinyl alcohol sponge and two metallic springs, one at each pedicle (fig. 2). The tumor volume was moderately reduced and its turgescence was markedly reduced.

In July 19, 1993, an ample resection of the lesion was performed with peripheral margins of 2 cm, reaching, in depth, the subaponeurotic plan and partially including the deltoid muscle and the aponeurosis of the biceps and triceps, which were adhered to the tumor (figs. 3 & 4).

Daily dressings were made on the bloody area with an antiseptic (hexachlorophene) and uncture (collagenase), providing a satisfactory growth of granulation tissue. However, two months after the surgery and before the bloody area healing, the patient moved to another address and stopped coming to the ambulatorial control. Only in June 1994 it was possible to find out his whereabouts; he was in good conditions, with the bloody area completely healed, with no important functional restrictions and no signs of tumor recurrence (figs. 5 & 6).

In a retrospective study of the period comprised between January 1984 and May 1994, other four cases of dermatofibrosarcoma protuberans were detected; these cases are analysed in Table I.

DISCUSSION

The most extensive literature reviews were performed by Taylor and Helwig in 1962 (115 cases) and by Rutgers and colleagues in 1992 (913 cases). The largest tumor described had a 12 cm diameter. The case reported in this work presented dimensions of 28 x 23 x 16 cm, representing, for what it seems, the largest volume already described in the literature for this type of tumor.

The "Dermatofibrosarcoma protuberans" histopathogenesis is controversial. The first references as to its origin were made in 1962 by Taylor and Helwig, who analysed the histological characteristics

of 115 cases and stated that the pathology origin was fibrohistiocytic⁽¹²⁾. In 1976, by means of a tissue culture and an ultrastructural study, Ozzello and Hamels expressed the same opinion⁽⁷⁾. However, with an extensive study by electron microscopy, Hashimoto and colleagues (1974) suggested that the main cell originates from a neural cell modified as endoneural or perineural cell⁽⁴⁾. In 1985, Fletcher and colleagues corroborated this hypothesis⁽⁶⁾. Stephenson and colleagues associated the tumor with the trisomy of the chromosome 7 and chromosomal ring⁽¹¹⁾, but suggested additional studies might be performed to determine these data significance, for the cytogenetic knowledge of the pathology in the literature is quite limited.

As to the patients' most affected body areas and age, the authors' observations, in their majority, are uniform^(1, 6, 9, 12), detecting a greater incidence on the thorax, followed by the limbs proximal extremities and, less frequently, the head and neck, in patients between 20 and 50 years in age. In our casuistry, however small, we have observed the same prevalence.

Rutgers and colleagues and Lanskin report a slight prevalence on the male sex^(6, 9), while Bendix-Hansen and colleagues have detected the same frequency on both sexes⁽¹⁾.

The local recurrence index is of about 50%, even after the adequate excision of the lesion. Rutgers and colleagues and Lanskin observe that surgical margins wider than 3 cm cause this index to drop to 20 - 30%^(6, 9). Smola and colleagues, on their turn, suggest the aponeurotic fascia resection to minimize the recurrences⁽¹⁰⁾.

The metastasis are rare (5% of the cases). In accordance with the studies of Platil and colleagues, the dissemination occurs hematogenically (4%) and lymphatically for regional lymphatic ganglia (1%), occurring between 7 and 15 years after the primary tumor coming out⁽⁸⁾. For Lanskin⁽⁶⁾, the lung is the preferred target (80%), with less common occurrences in the brain, bones, heart and pancreas. According to these authors, the metastasis are more frequent after multiple local recurrences.

In our casuistry, only one patient was controlled for 12 months after surgery, and he did not present local recurrences nor metastasis. As to the giant tumor case, after one year the patient was well, even without medical follow-up and with the bloody area healed by sec-

ond intention. In accordance with our patients' characteristics, this generally occurs because they are feeling well and do not want to be absent from work or have transportation expenses "just to be seen by the doctor". In case of recurrence, they will undoubtedly come back.

As far as the treatment is concerned, the authors unanimously advise local surgical resection with peripheral margins of 2-3 cm, including the subjacent fascia. We have opted for the same procedure, but in infiltrative lesions the resection must go beyond the fascia as far as necessary.

The preoperative embolization of the tumoral mass was indicated only for the giant tumor, reducing significantly its size and turgescence and facilitating the surgical act with minimal bleeding.

In a conjoint evaluation with our hospital Oncology Service, we have opted not to use radiotherapy as adjuvant or therapeutic procedure. Referring to the literature, we have found out that the radiotherapy role is still undefined. The authors whose works we have used in our research emphatically state that the "Dermatofibrosarcoma protuberans" cases treated with radiotherapy did not present any response (1, 9, 12). Among them, only Taylor and colleagues consider that radiotherapy may represent a therapeutic alternative in unresectable lesions (12).

REFERENCES

1. Bendix-Hansen, K., Myhre-Jensen, O., Kaae, S. Dermatofibrosarcoma protuberans: A clinico-pathological study of nineteen cases and review of the world literature. *Scand. J. Plast. Reconstr. Surg.* 17:247-252, 1983.
2. DARIER, J.; FERRAND, M. Dermatofibromes progressifs et recidivants ou fibrosarcomes de la peau. *Ann. de Dermat.* 6:545-62, 1924.
3. FLETCHER, C. D.; EVANS, B. J.; MACARTNEY, J.C. Dermatofibrosarcoma protuberans: a clinico-pathological and immunohistochemical study with a review of the literature. *Histopathology* 9:921-938, 1985.
4. HASHIMOTO, K.; BROWNSTEIN, M.H.; JAKOBIAC, F. A. Dermatofibrosarcoma protuberans. *Arch. Dermatol.* 110:874-885, 1974.
5. HOFFMAN, E. Uber das Knollentreibende Fibrosarkon der Haut (Dermatofibrosarcoma protuberans). *Dermat. Zeitschn* 43:1-8, 1925.
6. LANSKIN, W. B. Dermatofibrosarcoma protuberans. *Cancer Journal for Clinicians* 42(2):116-125, 1992.
7. OZZELO, L.; HAMELS, J. The Histiocytic Nature of Dermatofibrosarcoma protuberans - Tissue culture and electron microscopic study. *Am. J. Clin. Pathol.* 65:136-148, 1976.
8. PATIL, P. K.; PATEL, S. G.; KRISHNAMURTHY, S.; MISTRY, R. C.; DESPHANDE, R. K. AND DESAI, P. B. Dermatofibrosarcoma protuberans Metastatic to the Lung. A case report. *Tumori* 78:49-51, 1992.
9. RUTGERS, E. J.; KROON, B. B.; ALBUSLUTTER, C. E.; GORTZAK, E. Dermatofibrosarcoma protuberans: Treatment and prognosis. *European Journal of Surgical Oncology* 18:241-248, 1992.
10. SMOLA, M. G.; SOYER, H. P.; SCHARNAGL, E. Surgical Treatment of Dermatofibrosarcoma protuberans. A retrospective study of 20 cases with review of literature. *European Journal of Surgical Oncology* 17:447-453, 1991.
11. STEPHENSON, C. F.; BENDER, C. S.; LEONG, S. P. L.; DAVIS, J. R. AND SANDBERG, A. A. Ring Chromosome in a Dermatofibrosarcoma protuberans. *Cancer Genet. Cytogenet.* 58:52-54, 1991.
12. TAYLOR, H. B.; HELWIG, E. B. Dermatofibrosarcoma protuberans: A Study of 115 cases. *Cancer* 15:717-725, 1962.