



Nanofat injector: a low-cost disposable device for standardization and optimization of grafting time

Nanofat injector: dispositivo descartável de baixo custo para padronização e otimização do tempo de enxertia

JOÃO MAXIMILIANO^{1*}

MIRIAN PEDRON²

ANTONIO CARLOS PINTO OLIVEIRA¹

EDUARDO MADALOSSO ZANIN¹

DANIELE WALTER DUARTE¹

CIRO PAZ PORTINHO¹

JOÃO LUIZ MARTINS²

MARCUS VINICIUS MARTINS COLLARES¹

■ ABSTRACT

Introduction: Nanofat graft improves skin quality in damage secondary to aging and scar sequelae. We present the initial results of the nanofat graft using a low-cost disposable device, proposing a standardization of its use according to the area to be treated. **Methods:** A prospective cohort was conducted from July 2019 to March 2020. The inclusion criterion was patients who underwent nanofat grafting for skin treatment. The exclusion criterion was the previous performance of some invasive treatment of the skin. Twenty consecutive patients who met the prerequisites were analyzed. The results were evaluated in the 6th postoperative month. The patients answered a questionnaire, classifying from 1 - very bad to 10 - excellent, changes in skin quality. **Results:** The twenty patients followed did not present any postoperative complications. Edema after the application was reduced between three and seven days. There was no hematoma or infection. Patients who underwent only nanofat grafting without another associated surgery could return to their activities after 24 hours. The scores reported by patients at 6 months were between 7 and 10, with a mean of 8. **Conclusion:** The use of the Smartneedle™ system for nanofat grafting presents patient satisfaction similar to other application methods and allows a uniform and standardized distribution of the graft according to the anatomical region and optimizing surgical time

Keywords: Fats; Face; Skin; Skin abnormalities; Facial expression.

Institution: Hospital de Clínicas de Porto Alegre, Porto Alegre, RS, Brazil.

Article received: May 7, 2020.

Article accepted: April 23, 2021.

Conflicts of interest: none

DOI: 10.5935/2177-1235.2021RBCP0068

¹ Hospital de Clínicas de Porto Alegre, Plastic Surgery Service, Porto Alegre, RS, Brazil.

² Private Clinic, Private Clinic - Porto Alegre, Porto Alegre, RS, Brazil.

■ RESUMO

Introdução: O enxerto de gordura nano melhora a qualidade da pele nos danos secundários ao envelhecimento e nas sequelas cicatriciais. Apresentamos resultados iniciais do enxerto de gordura nano com o uso de um dispositivo descartável de baixo custo propondo uma padronização da sua utilização conforme a área a ser tratada. **Métodos:** Foi realizada uma coorte prospectiva de julho de 2019 a março de 2020. O critério de inclusão foi pacientes que realizaram enxerto de gordura nano para tratamento da pele. Já o critério de exclusão foi a realização prévia de algum tratamento invasivo da pele. Foram analisadas 20 pacientes consecutivas que preencheram os pré-requisitos. Os resultados foram avaliados no 6º mês de pós-operatório. As pacientes responderam um questionário, classificando de 1 - muito ruim a 10 - excelente, as alterações na qualidade da pele. **Resultados:** As vinte pacientes acompanhadas não apresentaram nenhuma complicação pós-operatória. O edema após aplicação reduziu entre três e sete dias. Não houve hematoma nem infecção. As pacientes que realizaram somente enxerto de gordura nano, sem outra cirurgia associada, conseguiram voltar às suas atividades após 24 horas. Os escores relatados pelas pacientes com 6 meses foram entre 7 e 10, com média de 8. **Conclusão:** A utilização do sistema *Smartneedle*[™] para a enxertia de gordura nano apresenta resultados na satisfação das pacientes semelhante aos outros métodos de aplicação e permite uma distribuição uniforme e padronizada do enxerto conforme a região anatômica, além de otimizar o tempo cirúrgico. **Descritores:** Gorduras; Face; Pele; Anormalidades da pele; Expressão facial.

INTRODUCTION

Tonnard et al., in 2013¹, described the nanofat graft. The intradermal injection of the graft with 27 gauge needles became viable through the emulsification and filtering of the liposuctioned fat. The laboratory analysis showed complete destruction of the adipocytes and a total loss of the volumization capacity; however, it allows the isolation of the stromal vascular fraction of the fat, maintaining its regenerative potential intact². The nanofat graft improves the quality of the skin in damages secondary to aging and in the healing sequelae³⁻⁵. This work aims to present the initial results of the nanofat graft with the use of a low-cost disposable device, proposing a standardization of its use according to the area to be treated.

METHODS

A prospective cohort was conducted from July 2019 to March 2020. The approval of the institutional review board of the Hospital de Clínicas de Porto Alegre was granted, project number 2008-0058, and this research-based study was conducted following the

provisions of the Declaration of Helsinki. The inclusion criterion was patients who underwent nanofat grafting for skin treatment. The exclusion criterion was the previous performance of some invasive treatment of the skin. Twenty consecutive patients who met the prerequisites were analyzed.

The results were evaluated in the 6th postoperative month. The patients answered a questionnaire, classifying from 1 - very bad to 10 - excellent, changes in skin quality.

To remove the graft, we chose between the infraumbilical region or the inner thigh⁶. Infiltration is performed with saline solution and adrenaline at a concentration of 1:300,000. Liposuction is performed with a 3mm cannula, with 1mm holes and rough surface^{1, FAGA}.

The collected fat is washed and decanted⁷. The first part is the micrograft and is ready for use; the second is transferred 30 times by each of the three 2.4mm, 1.8mm and 1.4mm^{FAGA} protractors. After transfers, the emulsified graft will be ready¹. According to the need for nano graft volume, a percentage of the emulsified graft can go to the third

stage. This step consists of passing once in each of the three filters¹, FAGA: 0.5mm, 0.3mm and 0.15mm (Figures 1 and 2).

For application, the fat is transferred from the 20ml syringe to the 3ml syringe and coupled to the *Multineedle 19 Needles System* (JM Biotech Co. Ltd., Daegu, South Korea) (Figures 3 and 4). The depth to be grafted is standardized by anatomical region (Table 1 and Figure 5). The system is applied to 90 degrees concerning the skin for complete penetration of all needles. An application of 0.3ml of nano graft per stitch is performed (0.016ml injected by each needle) (Figure 6). After finishing the grafting, skin massage is performed with the nano graft.

RESULTS

The twenty patients followed did not present any postoperative complications. Edema after application decreased between three and seven days. There was no hematoma or infection. Patients who underwent only nanofat grafting without another associated surgery could return to their activities after 24 hours (Figures 7 and 8).

The scores reported by patients at six months were between 7 and 10, with a mean of 8 (Table 2).

DISCUSSION

The indication of nanofat graft aiming at skin treatment is growing worldwide. We did not find any article described with an unfavorable conclusion to its use. The main advantages of the nano graft are the maintenance of stem cells derived from adipose tissue

(ADSCs), in addition to the possibility of intradermal grafting, which was not possible before its description. The ADSCs have already been widely studied, and their regenerative potential well documented, with several applications to plastic surgery^{3-5,8}. Sesé, in 2019², described that the isolation of ADSCs, when carried out by the mechanical emulsification system, requires a quantity of fat ten times lower than the standard method, enzymatic isolation, and produces a higher concentration of stem cells, which explains its regenerative potential². The process of obtaining the nano graft is summarized in three stages: micrograft, emulsified fat and nanofat graft. Despite adding surgical time – due to preparation in three stages – when compared to the classic graft, all stages generate grafts with properties to treat different changes in aging, as shown in Figure 1.

In 2013, Tonnard et al.¹ described the application of the nano graft with 27 gauge needles. Still, the method requires a long time to perform, resulting in prolonged edema due to the formation of subdermal “fat lakes” and, mainly, the impossibility of standardizing the depth of application. Verpaele et al., in 2019⁹, described a new method, where they associate micro-needling with the deposit of the nano graft; for this, 8ml and 20 minutes of micro-needling are required. The system described in this article allows standardizing the injection depth according to the different anatomical areas¹⁰. With standardized grafting, injections are uniformly intradermal, reducing the risk of perforation of subdermal vascular plexus. This explains the lower potential of ecchymosis secondary to the procedure compared to the other methods already described¹.

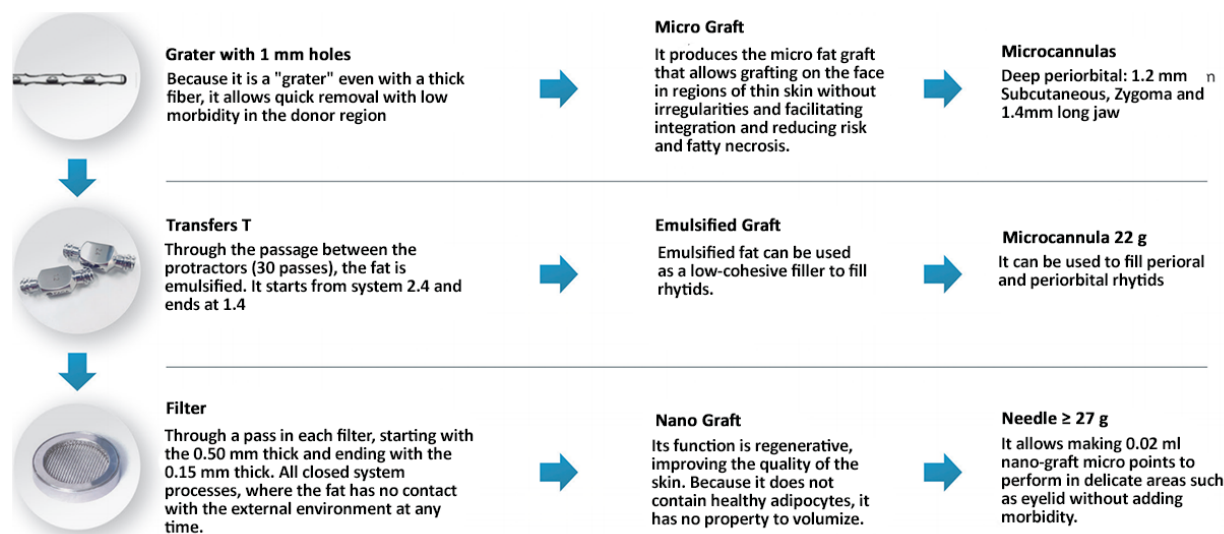


Figure 1. Protocol for obtaining the nanofat graft. Source: FAGA Medical | Surgical equipment and medical-hospital products(<http://www.fagamed.com.br/index.php>).

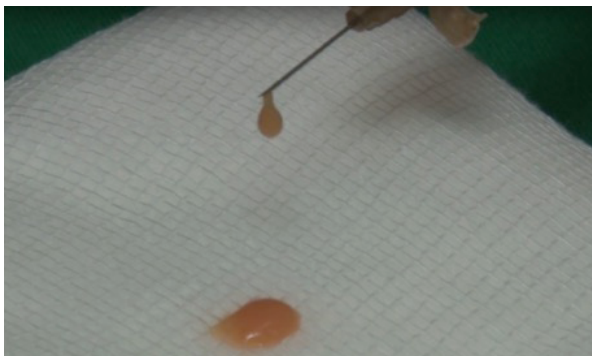


Figure 2. Nanofat graft (needle 27 gauge).

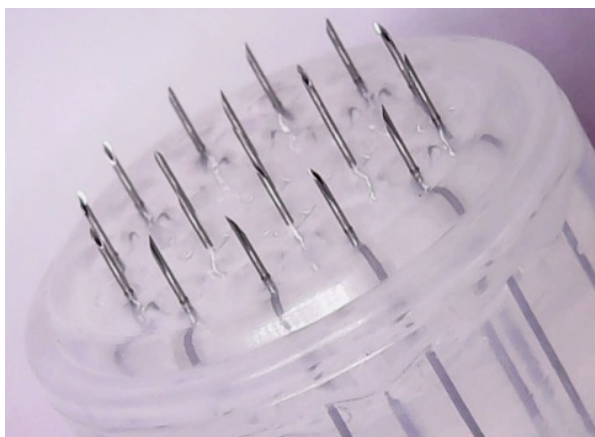


Figure 3. Multi needle System

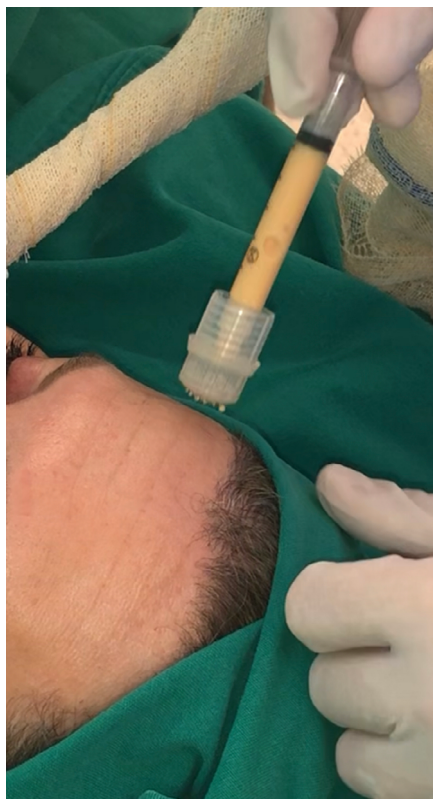

Figure 4. Photo illustrating the moment of application of the Nanofat Injector - Disposable low cost device for fat grafting.

Table 1. Depth to be grafted standardized by anatomical region.

Muscle	Number of a needles	Size
Frontal	19 needles	1mm
Orbital	19 needles	1mm
Zygomatic	19 needles	2mm
Maxillary and Mandibular	19 needles	2mm
Perioral	19 needles	1mm
Anterior cervical	19 needles	1mm
Back of hands	19 needles	1mm
Skin treatment after radiotherapy	19 needles	2mm

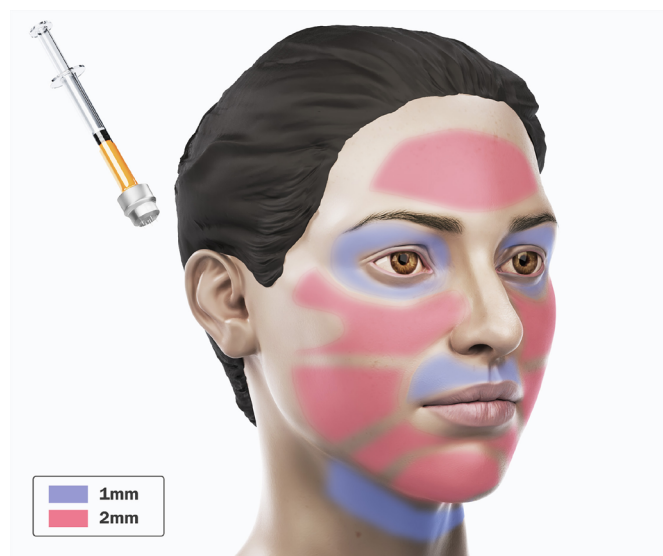

Figure 5. Anatomical regions for grafting.

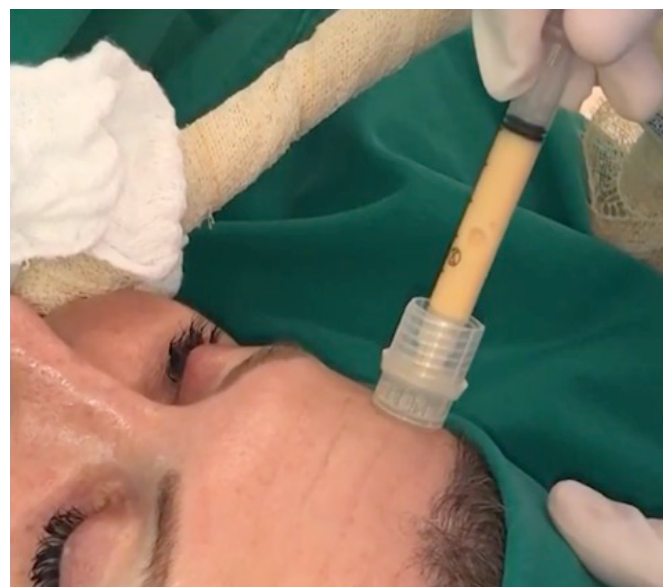

Figure 6. Application of multi needle system.

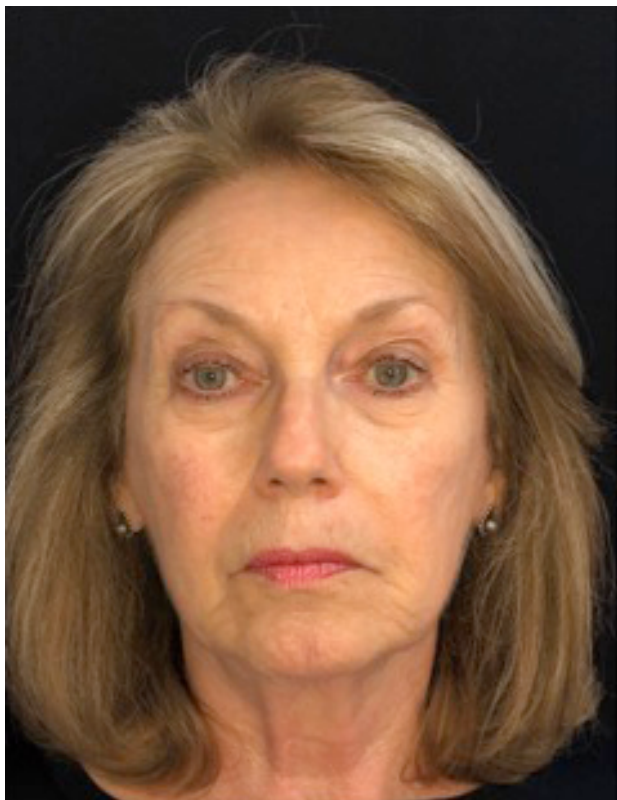

Figure 7. Preoperative aspect of nanofat grafting, six months after the procedure. Nano grafting: 6ml perioral and 12ml in the maxillary region.

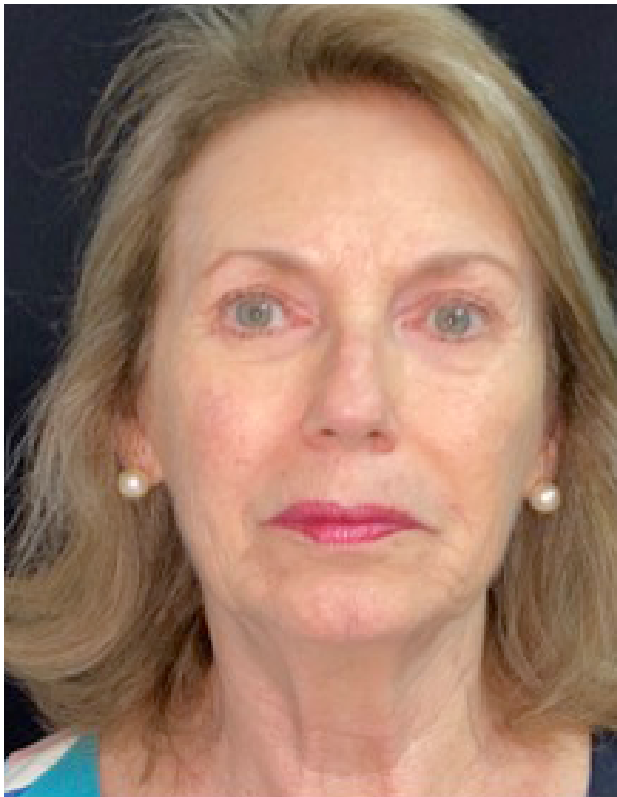

Figure 8. Postoperative aspect of nanofat grafting, six months after the procedure. Nano grafting: 6ml perioral and 12ml in the maxillary region.

Table 2. Satisfaction scores (0-10), age and gender of patients 6 months after surgery

	Score 0-10 6 months PO.	Age	Gender
MEC	7	54	F
IT	9	44	F
ES	10	53	F
EM	8	53	F
JP	8	50	F
SM	7	43	F
LG	7	44	F
EP	8	52	F
LP	9	67	F
MG	7	63	F
IR	8	64	F
RP	7	60	F
FL	7	61	F
EB	10	74	F
LB	8	54	F
VR	8	59	F
LC	9	58	F
JM	7	55	F
RR	8	48	F
MT	8	76	F

Furthermore, the proposed technique allows the control of the injection volume of the nano graft, and with the system of 19 needles, it is possible to graft 8ml in 2 minutes. Each application of 0.3ml requires between three and five seconds, with an injection of 0.016ml per point, which reduces the risk of large deposits, as well as prolonged edema¹. If the surgeon's goal is nano graft deposition and not microneedling, we believe this is the best system currently available. It allows a fast application, low morbidity, uniform deposit and adequate depth for the selected anatomical region. Finally, state-of-the-art technologies are usually associated with high investment. Still, the described system has a cost of R\$ 65 per device, so it is possible to put it on the surgical budget without derailing the surgery.

CONCLUSION

The use of the *Smartneedle*[™] system for nanofat grafting presents results in patient satisfaction similar to other application methods. It allows a uniform and standardized distribution of the graft according to the anatomical region and optimizes surgical time.

COLLABORATIONS

- JM** Analysis and/or data interpretation, Conception and design study, Conceptualization, Data Curation, Final manuscript approval, Formal Analysis, Funding Acquisition, Investigation, Methodology, Project Administration, Realization of operations and/or trials, Resources, Software, Supervision, Validation, Visualization, Writing - Original Draft Preparation, Writing - Review & Editing
- MP** Analysis and/or data interpretation, Conception and design study, Conceptualization, Data Curation, Final manuscript approval, Formal Analysis, Funding Acquisition, Investigation, Methodology, Project Administration, Realization of operations and/or trials, Resources, Software, Supervision, Validation, Visualization, Writing - Original Draft Preparation, Writing - Review & Editing
- ACPO** Analysis and/or data interpretation, Conception and design study, Conceptualization, Data Curation, Final manuscript approval, Formal Analysis, Funding Acquisition, Investigation, Methodology, Project Administration, Realization of operations and/or trials, Resources, Software, Supervision, Validation, Visualization, Writing - Original Draft Preparation, Writing - Review & Editing
- EMZ** Analysis and/or data interpretation, Conception and design study, Conceptualization, Data Curation, Final manuscript approval, Formal Analysis, Funding Acquisition, Investigation, Methodology, Project Administration, Realization of operations and/or trials, Resources, Software, Supervision, Validation, Visualization, Writing - Original Draft Preparation, Writing - Review & Editing
- DWD** Analysis and/or data interpretation, Conception and design study, Conceptualization, Data Curation, Final manuscript approval, Formal Analysis, Funding Acquisition, Investigation, Methodology, Project Administration, Realization of operations and/or trials, Resources, Software, Supervision, Validation, Visualization, Writing - Original Draft Preparation, Writing - Review & Editing

- CPP** Analysis and/or data interpretation, Conception and design study, Conceptualization, Data Curation, Final manuscript approval, Formal Analysis, Funding Acquisition, Investigation, Methodology, Project Administration, Realization of operations and/or trials, Resources, Software, Supervision, Validation, Visualization, Writing - Original Draft Preparation, Writing - Review & Editing
- JLM** Analysis and/or data interpretation, Conception and design study, Conceptualization, Data Curation, Final manuscript approval, Formal Analysis, Funding Acquisition, Investigation, Methodology, Project Administration, Realization of operations and/or trials, Resources, Software, Supervision, Validation, Visualization, Writing - Original Draft Preparation, Writing - Review & Editing
- MVMC** Analysis and/or data interpretation, Conception and design study, Conceptualization, Data Curation, Final manuscript approval, Formal Analysis, Funding Acquisition, Investigation, Methodology, Project Administration, Realization of operations and/or trials, Resources, Software, Supervision, Validation, Visualization, Writing - Original Draft Preparation, Writing - Review & Editing

REFERENCES

1. Tonnard P, Verpaele A, Peeters G, Hamdi M, Cornelissen M, Declercq H. Nanofat grafting: basic research and clinical applications. *Plast Reconstr Surg*. 2013 Oct;132(4):1017-26.
1. Sesé B, Sarmartin JM, Ortega B, Matas-Palau A, Lluill R. Nanofat cell aggregates: a nearly constitutive stromal cell inoculum for regenerative site-specific therapies. *Plast Reconstr Surg*. 2019 Nov;144(5):1079-88.
2. Oh DS, Kim DH, Roh TS, Yun IS, Kim YS. Correction of dark coloration of the lower eyelid skin with nanofat grafting. *Arch Aesthetic Plast Surg*. 2014;20:92-6.
3. Menkes S, Luca M, Soldati G, Polla L. Subcutaneous injections of nanofat adipose-derived stem cell grafting in facial rejuvenation. *Plast Reconstr Surg Glob Open*. 2020 Jan;8(1):e2550. DOI: <https://doi.org/10.1097/GOX.0000000000002550>
4. Jan SN, Bashir MM, Khan FA, Hidayat Z, Ansari HH, Sohail M, et al. Unfiltered nanofat injections rejuvenate postburn scars of face. *Ann Plast Surg*. 2019 Jan;82(1):28-33. DOI: <https://doi.org/10.1097/SAP.0000000000001631>
5. Padoin AV, Braga-Silva J, Martins P, Rezende K, Rezende AR, Grechi B, et al. Sources of processed lipoaspirate cells: influence of donor site on cell concentration. *Plast Reconstr Surg*. 2008 Aug;122(2):614-8. DOI: <https://doi.org/10.1097/PRS.0b013e31817d5476>
6. Condé-Green A, Amorim NF, Pitanguy I. Influence of decantation, washing and centrifugation on adipocyte and mesenchymal stem cell content of aspirated adipose tissue: a comparative study. *J Plast Reconstr Aesthet Surg*. 2010 Aug;63(8):1375-81.

7. Martins JMP, Oliveira FS, Lima EOC, Dullius D, Durli ICLO, Hiraiwa E, et al. Use of derived adipose stem cells to reduce complications of cutaneous scarring in smokers. An experimental model in rats. *Acta Cir Bras.* 2019;34(6):e201900605. DOI: <https://doi.org/10.1590/s0102-865020190060000005>
8. Verpaele A, Tonnard P, Jeganathan C, Ramaut L. Nanofat needling: a novel method for uniform delivery of adipose-derived stromal vascular fraction into the skin: correction. *Plast Reconstr Surg.* 2019 Jul;144(1):264. DOI: <https://doi.org/10.1097/PRS.00000000000006078>
9. Hausauer AK, Josnes DH. PRP e microagulhamento em medicina estética. Rio de Janeiro: Thieme Revinter Publicações; 2019.

Corresponding author:*João Maximiliano**

Rua Ramiro Barcelos, 2350, Santa Cecília, Porto Alegre, RS, Brazil.

Zip Code: 90035-003

E-mail: jmaximilianopm@gmail.com