



Pulmonary thromboembolism due to superficial venous thrombophlebitis in upper limbs after cosmetic breast plastic surgery: report of 3 cases

Tromboembolismo pulmonar decorrente de tromboflebitis venosas superficiais em membros superiores pós-cirurgia plástica mamária estética: relato de 3 casos

MÁRCIA BALBINA LORENZO HOYOS^{1*} 

■ ABSTRACT

Superficial thrombosis and thrombophlebitis of the upper limbs are frequent and often underestimated diseases. We report three patients in the postoperative cosmetic breast plastic surgery period who presented thrombophlebitis in the upper limbs and who evolved with pulmonary thromboembolism. All patients had a typical clinical picture, with Doppler ultrasound evidence of thrombosis/superficial phlebitis of the upper limbs and absence of lesions in the lower limbs and an increase in D-dimer and evidence of pulmonary embolism by computed tomography or pulmonary scintigraphy. The three cases evolved with improvement after anticoagulation and without sequelae.

Keywords: Thrombophlebitis; Thrombosis; Pulmonary embolism; Augmentation mammoplasty; Postoperative complications; Thromboembolism; Venous thromboembolism.

■ RESUMO

Tromboses e tromboflebitis superficiais de membros superiores são doenças frequentes e muitas vezes pouco valorizadas. Relatamos três pacientes no pós-operatório de cirurgias plásticas mamárias estéticas que apresentaram tromboflebite em membros superiores e que evoluíram com tromboembolismo pulmonar. Todas as pacientes apresentaram quadro clínico típico, com comprovação pelo Doppler ultrassonografia de trombose/flebite superficial de membros superiores e ausência de lesões em membros inferiores, bem como aumento de dímero-D e comprovação da embolia pulmonar por tomografia computadorizada ou cintilografia pulmonar. Os três casos evoluíram com melhora após anticoagulação e sem sequelas.

Descritores: Tromboflebite; Trombose; Embolia pulmonar; Mamoplastia de aumento; Complicações pós-operatórias; Tromboembolia; Tromboembolia venosa.

Institution: Rede de Assistência à Saúde
Metropolitana de Sarandi, Sarandi, PR,
Brasil.

Article received: 20/11/2019.
Article accepted: 15/7/2020.

Conflicts of interest: none

DOI: 10.5935/2177-1235.2021RBCP0016

¹ Clínica Dra. Márcia Balbina L. Hoyos, Plastic Surgery, Maringá, PR, Brazil.

INTRODUCTION

Thromboembolic phenomena can result from thrombosis and/or superficial venous thrombophlebitis (SVT) of the upper limbs¹. Most superficial thromboses also compete with phlebitis, in contrast to deep vein thrombosis (DVT), where phlebitis may be absent². Pulmonary thromboembolism (PTE) can rarely be related to lower limb SVT (lower limbs)¹. There are few upper limb SVT reports (upper limbs) leading

to PTE³⁻⁷, and there are no reported cases related to cosmetic surgery.

In this article, we report 3 cases of patients who underwent cosmetic breast plastic surgery who had confirmed upper limb SVT and evolved with PTE.

CASE REPORT

Check Chart 1.

Chart 1. Details of the cases.

Type	Case 1	Case 2	Case 3
Surgery performed	Retromuscular augmentation mastopexy (dual plane) and abdominoplasty	Retro augmentation mammoplasty Muscular (dual plane)	Retro Muscular Augmentation Mammoplasty (dual plane)
Date surgery	19/12/2013	16/02/2016	Day 09/8/2017
Site of surgery	Hospital Metropolitano de Sarndi (PR) - Private	Hospital do Câncer - Maringá (PR) - Private	Hospital do Câncer - Maringá (PR) - Private
Duration of surgery	Five hours and 30 minutes.	1h20 min	1 hour
Type and Duration of anesthesia	Epidural and General 6h30min h	General 1 h 50 min.	General 1 h 30 min.
Use of BCP	Suspended for 1 month pre-Operative and after surgery	Suspended only after Surgery	Didn't use
Chemo prophylaxis	Made heparin intraoperatively and maintained for 4 days postoperatively	not performed	not performed
Venous puncture site	RIGHT upper member	RIGHT upper member	LEFT upper limb
Ultrasound of upper limbs	thrombophlebitis of basilica and brachial veins BILATERALLY	left basilica thrombophlebitis at elbow level	presence of imaging suggestive of occlusive thrombotic residues in the median vein of the right elbow
Ultrasound of lower limbs	absence of thrombi in deep and superficial vessels	absence of lesions in superficial and deep veins	absence of lesions in superficial and deep veins
D-dmin *ref. positive = or > 500 ng/ml *FEU equivalent fibrinogenic units)	2110.00 ng/ml	810.0 ng/ml	4110 ng/ml
Pulmonary tomography	Signs of pulmonary thromboembolism in the distal third of the left pulmonary artery. Possible small clots embolizing the posterior segment of the lower lobe to the right	Discrete bilateral basal opacities, which may correspond to the opacity of decubitus	SIGNS of PTE in the right lower lobe posterior segment
Pulmonary scintigraphy	Not performed	Presence of focal areas, with decreased blood perfusion, of a subsegmental pattern dispersed in the posterior segment of the right upper lobe, superior of the right lower lobe, lateral of the middle lobe and lateral of the left lower lobe, of a subsegmentary pattern, disagreeing with the inhalation pattern. High probability of pulmonary thromboembolism. 2. Presence of focal areas of radiotracer hypocaptation located in the most basal portions of the right lung, suggesting a parenchymal process (atelectasis?)	Not performed
Investigation for thrombophilia	Negative	POSITIVE, diagnosed with antiphospholipid antibody syndrome (point mutation C677T: Heterozygous mutated), IgM Cardiolipin antibodies 64.0 MPL-U and after 6 months 57.0 MPL-U (Positive higher than 40)	Negative
Other exams		Normal echocardiogram	

BCP - Birth control pills. FEU - Equivalent fibrinogenic units. PTE - Pulmonary thromboembolism.

Case 1. A 31-year-old female patient without comorbidities who underwent a mastopexy of retromuscular augmentation and abdominoplasty without liposuction. She wore elastic stockings during the procedure and for one more week, an anti-thrombosis device for 24 hours, subcutaneous heparinization in the intra and postoperative periods for four days (heparin from 10 to 15 thousand U/day), and contraception suspended for 30 days before surgery. After 15 days, she had pain in her upper limbs, and on the 18th day, she had sudden dyspnea diagnosed with PTE (Figures 1 and 2). She was hospitalized for 7 days, 5 of them in an intensive care unit, oxygen supplementation (without orotracheal intubation), observation, and anticoagulation. It evolved without sequelae.

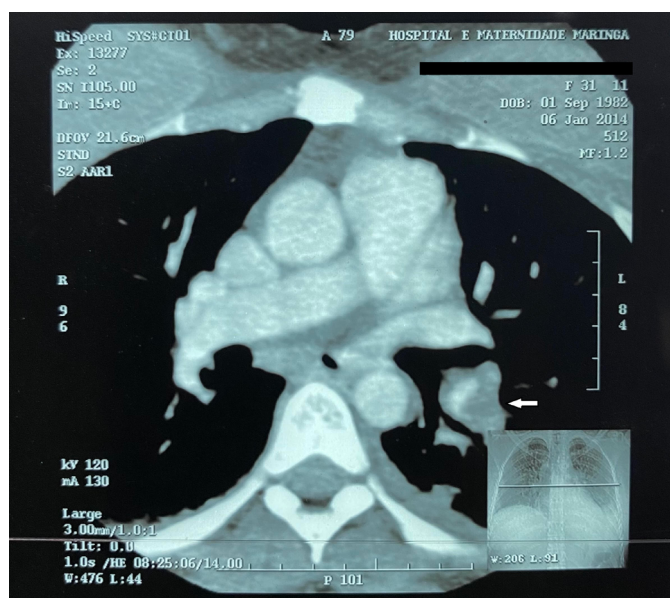

Figure 1. Case 1: Pulmonary Computed Tomography: Arrow indicating failure of filling in the left pulmonary artery.

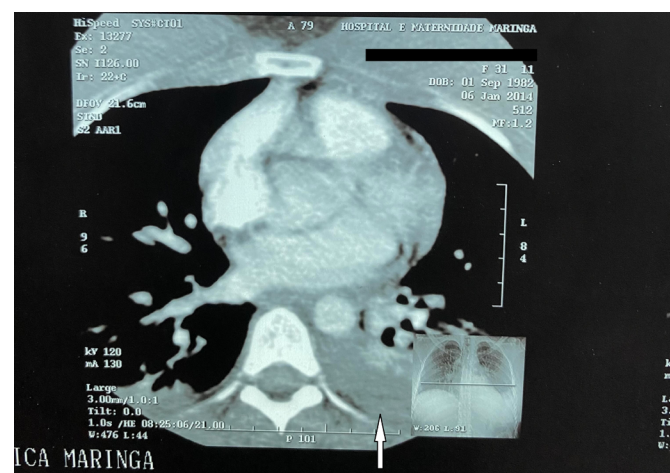


Figure 2. Case 1: Pulmonary Computed Tomography: Arrow indicating pleural effusion in left lower lobe

Case 2. A 35-year-old female patient with no comorbidities who underwent breast augmentation. She developed a sudden dyspneic condition with no complaints until the 10th postoperative day, confirming PTE (Figure 3). She was admitted for three days for observation, oxygen supplementation (without orotracheal intubation), and anticoagulation. It evolved without sequelae. Contraceptive suspension (BCP) only after surgery.

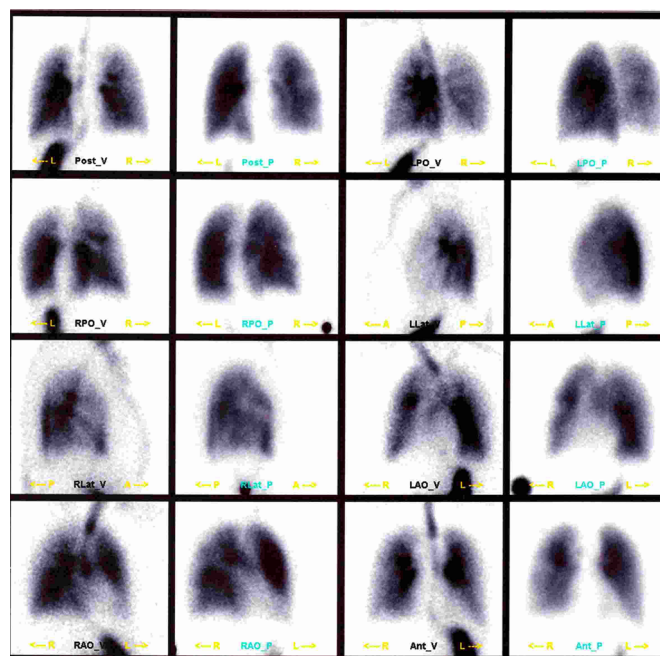


Figure 3. Case 2: pulmonary scintigraphy - presence of focal areas, with decreased blood perfusion, of a subsegmental pattern dispersed in the posterior segment of the right upper lobe, superior of the right lower lobe, lateral of the middle lobe and lateral of the left lower lobe, of subsegmental pattern, discordant with the pattern

Case 3. A 17-year-old female patient without comorbidities who underwent a breast augmentation. There were no complaints until the 6th postoperative day, when she developed sudden dyspnea, confirming PTE (Figure 4). She was hospitalized for five days, two in an intensive care unit, for observation, oxygen supplementation (without orotracheal intubation), and anticoagulation. It evolved without sequelae. Family history of postoperative embolism in grandfather and uncle.

DISCUSSION

PTE is especially feared after cosmetic surgery. In the cases described, it is surprising that the embolic source is from upper limbs (Figure 5).

SVT is a common disease, usually identifying a palpable cord (best sign with positive predictive value), hyperemic, painful, and hot in the course of the

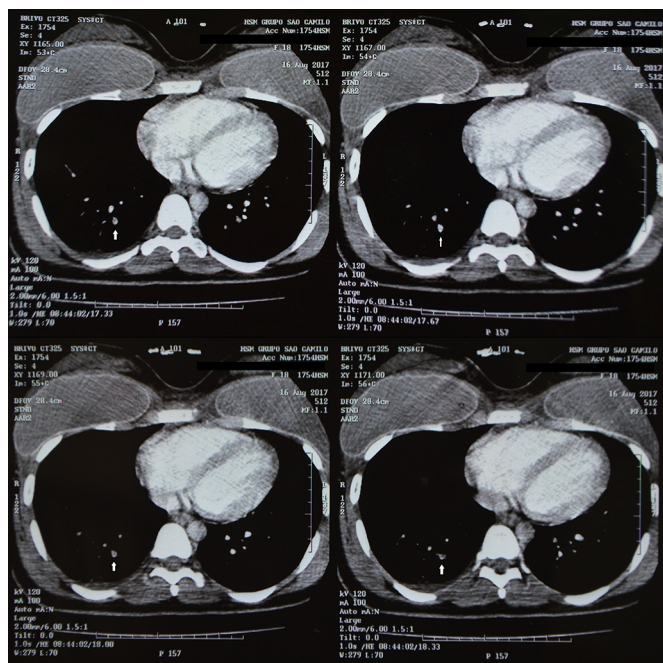


Figure 4. Case 3: pulmonary computed tomography - arrows indicating filling failure in segmental arteries of the right lower lobe.

superficial vein¹. In more severe cases of the upper limb, it can extend to axillary veins. In case 1, thrombosis reached brachial veins.

PTE secondary to SVT of the upper limbs is rare in the absence of DVT⁴. SVT is probably little detected and is at least 2 to 3 times more frequent than deep. It usually resolves spontaneously. In lower limbs, SVT evolves in 20 to 33% for asymptomatic PTE and 2 to 13% for symptomatic. There is no data for upper limbs.

In cases 1 and 3, computed tomography (CT) was compatible, and in case 2, pulmonary scintigraphy confirmed the diagnosis of PTE (inconclusive CT). Doppler ultrasonography of the upper limb was associated with the absence of thrombi in the lower limbs. Therefore, PTEs resulting from SVT of the upper limb (compatible clinic, positive D-dimer, and CT or pulmonary scintigraphy proving PTE) were confirmed⁸. Besides, patients improved after anticoagulation.

As a cause of upper limbs thromboembolic phenomena, the use of central venous catheters (chemotherapy, prolonged antibiotic therapy, or parenteral nutrition) is found, as well as peripheral venous catheters (often “trivialized” in conventional medicine)⁹. In cases 2 and 3, it is noteworthy that the SVT was contralateral to the punctured limb, and in case 1, bilateral.

Several studies suggest a predictive score for safety parameters in plastic surgery^{10,11}. However, only in case 1 did the surgery last for more than 4 hours, and in the others, it was close to 1 hour. Despite preventive measures for thromboembolism, patient 1 presented bilateral

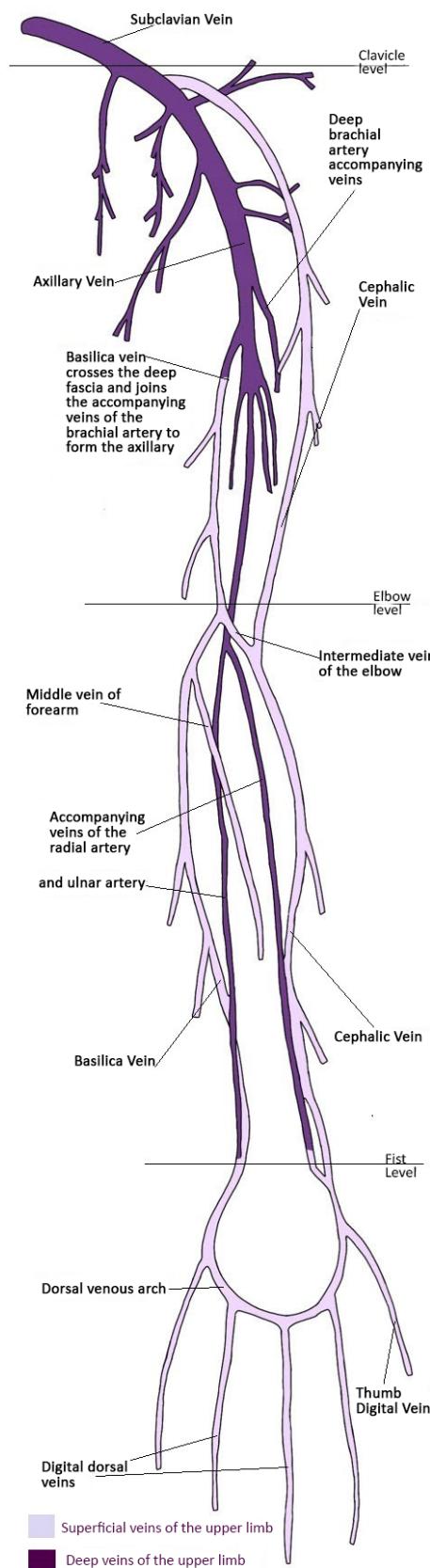


Figure 5. Schematic representation of the superficial and deep veins of the upper limb

upper limbs SVT that extended to deep, probably due to prolonged immobilization and delay in diagnosis.

The research for preoperative thrombophilia is questionable (rarity of these situations and high cost). It should only be performed in the case of unexplained thromboembolic phenomena^{9,12}.

Hereditary thrombophilia (Chart 2) and oral contraceptives have a higher risk of thromboembolism, about 2 to 20 times¹². Case 2 presented acquired thrombophilia (without a previous diagnosis) and use of oral contraception.

Chart 2. Classification of thrombophilias.

Classification of thrombophilias ¹³
Hereditary
Antithrombin deficiency protein deficiency C
Protein Deficiency Protein S Protein Deficiency Z
resistance APC (APCR)
Factor V Leiden mutation (R506Q)
Prothrombin G20210A gene Mutation
MTHFR mutation (variants 677C>T and 1298A>C)
PAI-1 675G>A mutation (4G/5G) and 844A>G
Dysfibrinogenemias High Factor IX
High Factor XI
Acquired
Antiphospholipid antibody syndrome (APLS)
Mixed/combined
Hyperhomocysteinemia high factor VIII activity increased fibrinogen
Other thrombophilias
ACE Ins/del fibrinogen (455G>A)
factor XIII (Val34Leu)
APOE (Cys112Arg and Arg158Cys)
EPCR (4678G/C)

APCR - Activated protein C resistance. ACE Ins / Del - Insertion/deletion of the angiotensin converting enzyme gene. MTHFR - Methylentetrahydrofolate reductase. PAI - Plasminogen activator inhibitor. APOE - Apolipoprotein E gene. EPCR - Endothelial cell protein C receptor gene.

There is a case description of PTE in the literature due to SVT in a patient using hormone therapy only⁴. Hormone therapy or oral contraception increases the chance of thromboembolism by up to four times. Thus, the importance of hormonal suspension, even in cases of lower risk¹⁰.

The most important chemoprophylaxis in venous thrombosis would be with fibrinolytic agents (heparin or low molecular weight heparin), while in arterial, it is based on the use of antiplatelet agents¹⁰.

Mechanical prophylaxis (elastic stockings, intermittent pneumatic devices) reduces venous stasis and distension. The pneumatic device has little fibrinolytic activity¹⁰. It is recommended to start it 30 minutes before anesthetic induction until the patient's discharge, in surgeries longer than one hour¹⁰.

There are no reports of post-plastic surgery PTE from upper limb SVT. Several factors could explain this fact, such as:

- the inadequate position of the upper limbs during the intraoperative period;
- postoperative immobilization, especially in cases of retromuscular breast implant (postoperative usually more painful);
- exaggerated immobilization of the limbs and/or inappropriate flexing of the limbs, for example, due to the excessive time of electronic devices (cell phones or computers), leading to an inadequate posture for drainage and consequent local stasis. In these cases, an elastic band (for non-displacement) above the prostheses was used.

CONCLUSION

Cosmetic breast augmentation surgery with implants, although usually not long, can also lead to non-local complications. Superficial thrombophlebitis, triggered by excessive rest and/or venipuncture, is often overlooked and can progress to thrombosis of larger vessels or even PTE.

Preoperatively, it is suggested to follow the prophylaxis protocols for thromboembolism. In the intraoperative period, it is recommended that the arms' position be constantly monitored and the use of elastic stockings, pneumatic apparatus in the lower limbs, and chemoprophylaxis. Postoperative surveillance of the upper limbs is also suggested to avoid excessive edema, and active research for thrombophlebitis.

COLLABORATIONS

MBLH

Aprovação final do manuscrito, Coleta de Dados, Conceitualização, Concepção e desenho do estudo, Gerenciamento do Projeto, Investigação, Metodologia, Realização das operações e/ou experimentos, Redação - Preparação do original, Redação - Revisão e Edição, Software, Supervisão, Validação, Visualização

REFERENCES

1. Sobreira ML. Complicações e tratamento da tromboflebite. *J Vasc Bras.* 2015 Jan/Mar;14(1):1-3.
2. Nagarsheth KH. Superficial thrombophlebitis: overview. *Medscape.* 2019.
3. Cascella M, Viscardi D, Bifulco F, Cuomo A. Postoperative massive pulmonary embolism due to superficial vein thrombosis of the upper limb. *J Clin Med Res.* 2016 Abr;8(4):338-41.
4. Manzana BJ, Tan RG, Tuason JP, Onf N. A case of pulmonary embolism from superficial venous thrombosis with an upper extremity source in a 35-years-old female on oral contraceptive pills. *Respirology.* 2018;23(Supl 2):90-334.

5. Sassu GP, Chisholm CD, Howell JM, Huang E. A rare etiology for pulmonary embolism: basilic vein thrombosis. *J Emerg Med.* 1990 Dez;8(1):45-9.
6. Barros FS, Sandri JL, Prezotti BB, Nofa DP, Cunha SXS, Barros SD. Pulmonary embolism in a rare association to a floating thrombus detected by ultrasound in the basilic vein at the distal arm. *Rev Bras Ecocardiogr Imagem Cardiovasc.* 2011;24(4):89-92.
7. Clement DL. Superficial vein thrombosis: more dangerous than anticipated. *Phlebology.* 2013;20(4):188.
8. Rivera-Lebron B, McDaniel M, Ahrar K, Alrifai A, Dudzinski DM, Fanola C, et al. Diagnosis, treatment and follow up of acute pulmonary embolism: consensus practice from the PERT Consortium. *Clin Appl Thromb Hemost.* 2019 Jan;25:1076029619853037.
9. Drouin L, Pistorius MA, Lafforgue A, N'Gohou C, Richard A, Connault J, et al. Épidémiologie des thromboses veineuses des membres supérieurs: étude rétrospective de 160 thromboses aiguës. *Rev Med Interne.* 2019 Jan;40(1):9-15.
10. Iorio ML, Venturi ML, Davison SP. Practical guidelines for venous thromboembolism chemoprophylaxis in elective plastic surgery. *Plast Reconstr Surg.* 2015 Fev;135(2):413-23.
11. Saldanha OR, Salles AG, Llaverias F, Saldanha Filho OR, Saldanha BC. Fatores preditivos de complicações em procedimentos da cirurgia plástica - sugestão de escore de segurança. *Rev Bras Cir Plást.* 2014 Jan/Mar;29(1):105-13.
12. Lima J, Borges A. Rastreo de trombofilias. *Bol SPHM.* 2012 Dez;27(4):5-11.

***Corresponding author:**

Márcia Balbina Lorenzo Hoyos

Avenida Doutor Luiz Teixeira Mendes, 2418, Zona 05, Maringá, PR, Brazil.

Zip Code: 87015-001

E-mail: mblhoyos@gmail.com