









# Reconstruction with a partial flap of the pectoralis major muscle, after complication of osteosynthesis of clavicle fracture

*Reconstrução com retalho parcial de músculo peitoral maior, após complicação de osteossíntese de fratura de clavícula*

FABIANE PINHEIRO<sup>1\*</sup>   
FABRICIO LUIS PINHEIRO<sup>1</sup>   
DIEGO LOUREIRO DOS SANTOS<sup>1</sup>   
CLAUDIO MESSIAS MORAES<sup>1</sup>   
RICARDO PORTELLA PERRONE<sup>1</sup>   
LEANDRO TUZUKI CAVALHEIRO<sup>1</sup> 

### ■ ABSTRACT

**Introduction:** The pectoralis major is a muscle that covers the upper portion of the anterior chest wall and is the first option for reconstruction of the chest wall and aesthetic purposes. **Case Report:** Male patient, 20 years old, presenting dehiscence of surgical wound, recurrent for three consecutive times, with exposure of the left clavicle osteosynthesis plate. Reconstruction was performed with the pectoralis major muscle to cover the plaque. **Conclusion:** This flap showed to be an excellent option for covering synthetic material exposure after multiple dehiscences of surgical wounds. The reconstruction was effective, with no complications and a satisfactory aesthetic result.

**Keywords:** Myocutaneous flap; Pectoral muscles; Surgical flaps; Internal fracture fixation; Chest wall.

### ■ RESUMO

**Introdução:** O peitoral maior é um músculo que recobre a porção superior da parede torácica anterior e é a primeira opção para reconstrução da parede torácica e fins estéticos. **Relato de Caso:** Paciente masculino de 20 anos, apresentando deiscência de ferida operatória, recidivante por três vezes consecutivas, com exposição de placa de osteossíntese de clavícula esquerda. Realizado reconstrução com o músculo peitoral maior para cobertura de placa. **Conclusão:** Este retalho mostrou excelente opção para cobertura de exposição de material de síntese após múltiplas deiscências de ferida operatória. A reconstrução foi efetiva, sem complicações e resultado estético satisfatório.

**Descritores:** Retalho miocutâneo; Músculos peitorais; Retalhos cirúrgicos; Fixação interna de fraturas; Parede torácica.

Institution: Santa Casa da Misericórdia de Santos, Plastic Surgery and Burns Service, Santos, SP, Brazil.

Article received: June 4, 2019.  
Article accepted: January 10, 2021.

Conflicts of interest: none

DOI: 10.5935/2177-1235.2021RBCP0015

<sup>1</sup> Santa Casa da Misericórdia de Santos, Plastic Surgery and Burns Service, Santos, SP, Brazil.

## INTRODUCTION

The pectoralis major is a muscle that covers the upper portion of the anterior chest wall and is the first option for reconstruction of the chest wall, especially for defects of the sternum and anterior chest. Based on the thoracoacromial blood supply, it can easily cover sternal and anterior chest wall defects as an island or advancement flap<sup>1</sup>.

The pectoralis major muscle flap has been widely used since the late 1970s when Ariyan described it in 1979<sup>2</sup>.

In the literature, there are not many descriptions regarding this flap in reconstruction to cover synthesis material in the supraclavicular region.

## OBJECTIVE

The work aims to report the partial applicability of the pectoralis major muscle to cover a clavicle osteosynthesis defect with synthesis material exposure.

## CASE REPORT

Male patient, 20 years old, victim of a motorcycle fall, presented a fracture of the left clavicle, progressing with pain, limited movement, and deformity at the fracture site.

In the initial care, he underwent a surgical procedure with the orthopedics team, osteosynthesis of the left clavicle using a blocked plaque. After 14 days, he evolved with surgical wound dehiscence and exposure of synthetic material (Figure 1). Soft tissue re-approach and dehiscence closure were unsuccessful, with new material exposure five days after surgery (Figure 2).

In the preoperative evaluation and study, the defect was 6 cm wide and 4 cm deep, with exposure of

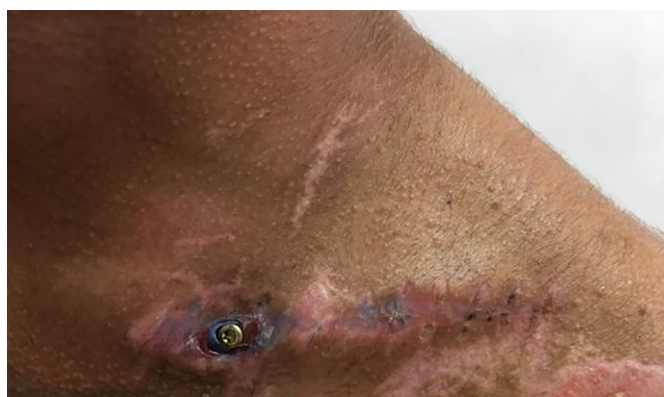

Figure 1. Dehiscence of the surgical wound and exposure of synthetic material.

synthesis material and absence of signs of infection. Reconstruction with muscle flap of the pectoralis was the best option for closure.

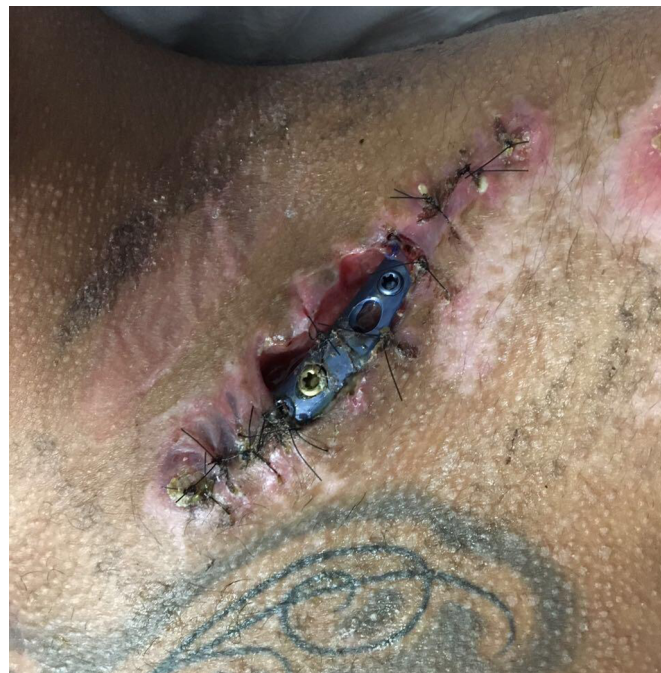

Figure 2. New surgical wound dehiscence five days after the surgical procedure.

In the intraoperative period, the upper portion of the pectoralis major muscle was exposed through dissection (Figure 3). A skin flap is elevated inferiorly, exposing the pectoralis major at the fourth intercostal space level and laterally towards the border of the deltoid. The muscle fibers were divided longitudinally towards the muscle's origin, and the muscle flap was dissected from the pectoralis minor muscle.

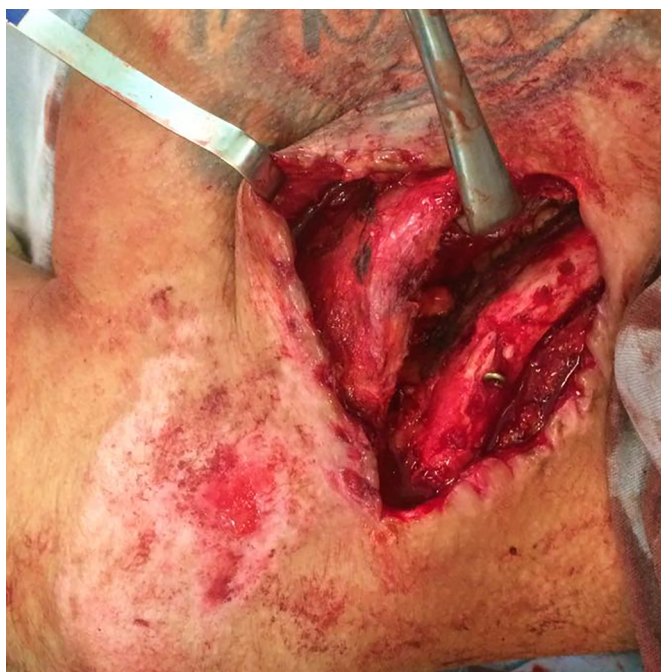

Figure 3. Exposure of the upper portion of the pectoralis major through dissection.

The medial dissection performed for the medial vascular perforators provided a divided pectoralis major flap, which can be easily rotated 45° to 60° degrees to fill the defect superiorly (Figure 4).

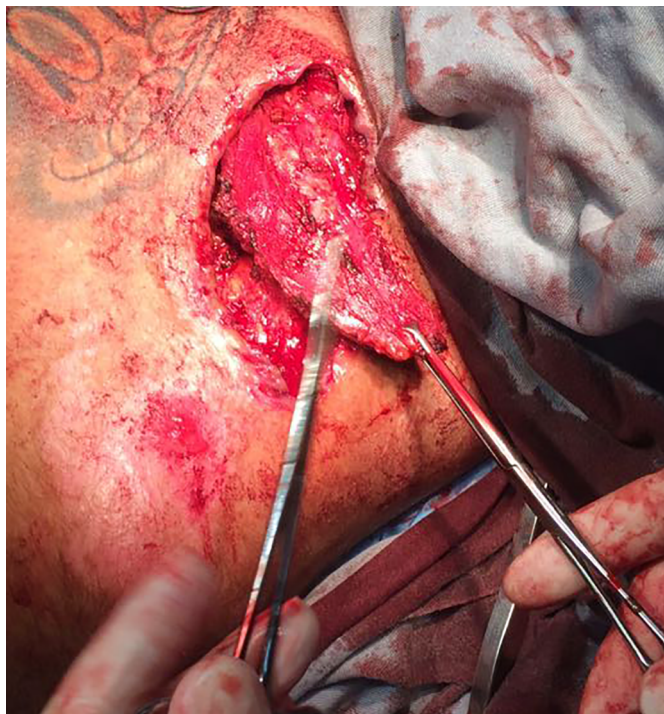


Figure 4. Divided major pectoral flap.

The flap was sutured superiorly to the platysma fascia and medially to the sternal fascia, maintaining good synthetic material coverage (Figure 5).

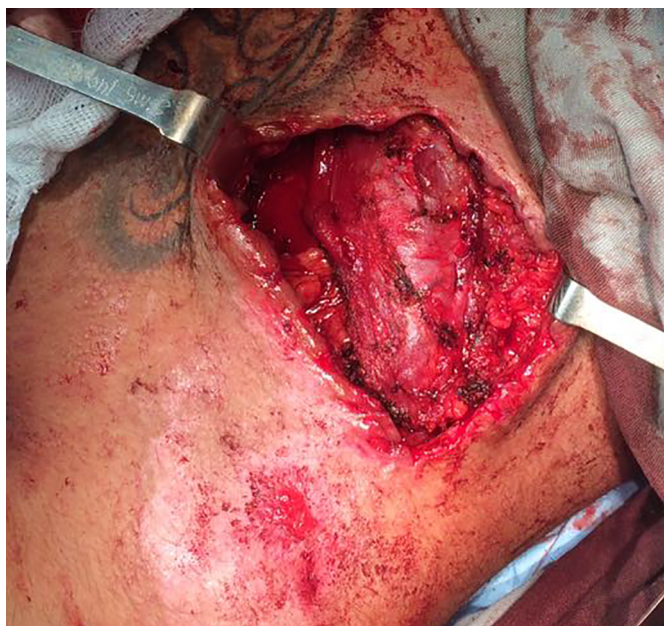

Figure 5. Flap sutured superior to the platysma fascia and medially to the sternal fascia.

The patient evolved uneventfully in the postoperative period; the coverage was effective, without bruising, with a satisfactory aesthetic result. He is currently undergoing late postoperative outpatient follow-up, with preserved upper limb mobility (Figures 6 and 7).



Figure 6. Postoperative.

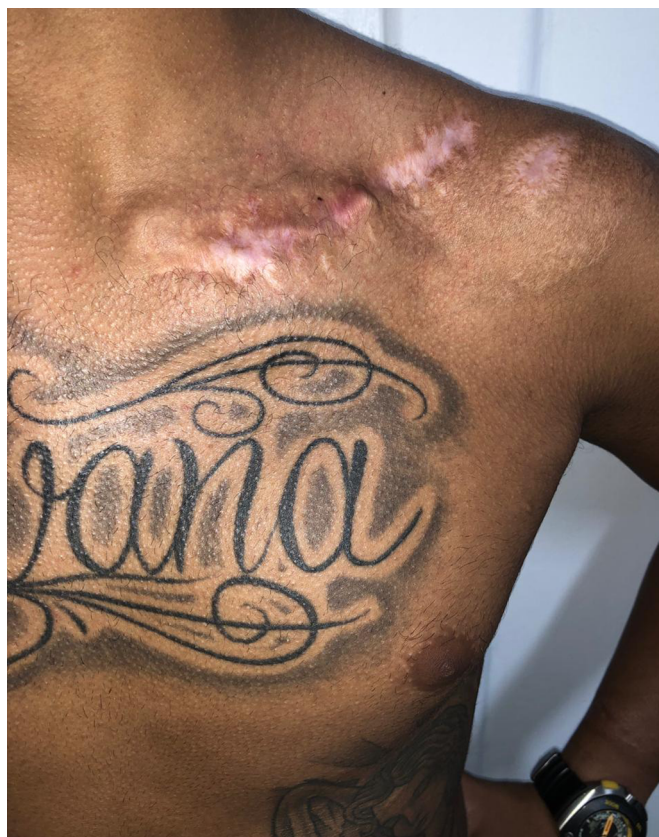

Figure 7. Postoperative.

## DISCUSSION

The pectoralis major muscle flap is the most widely used pedicled muscle flap to cover defects in the sternal region, anterosuperior chest, intrathoracic, and neck regions<sup>3</sup>.

The standard flap development technique is the complete lateral mobilization of the pectoralis major muscle close to its insertion. This provides a large vascularized muscle mass adequate to fill a significant defect but results in the complete loss of the pectoralis's main function.

In October 1982, Nahai et al.<sup>4</sup> described the technique that preserves the lateral third of the pectoralis major muscle with the dominant vascular pedicle and motor nerves, with the pectoralis's muscle reconstruction major for wound closure in sternotomy with preservation of form and function.

It is known that there is no extreme morbidity due to loss of the pectoralis major muscle since the pectoralis major, serratus anterior, and latissimus dorsi muscles can replace the function when working together—however, the loss of the pectoralis major muscle results in a significant decrease in humeral flexion strength.

According to the publication by Zehr et al., in 1999<sup>5</sup>, in limited resections, reconstruction can be performed with a fraction of the pectoralis major muscle, with the technique being used in two patients, the first being after resection of a malignant sarcoma involving the head of the clavicle and, in the second case, resection was necessary for chronic osteomyelitis caused by *Staphylococcus aureus* in an intravenous drug user. No functional deficit was observed because the lower half of the pectoralis muscle was preserved. The described technique preserves the function because half of the muscle remains intact, as we can see in our case report.

## CONCLUSION

The pectoralis major muscle flap proved to be an excellent option for reconstructing a clavicle osteosynthesis defect with material exposure, maintaining the upper limb mobility preserved, thus obtaining a satisfactory result.

## COLLABORATIONS

<b>FP</b>	Data Curation, Realization of operations and/or trials
<b>FLP</b>	Data Curation, Writing - Review & Editing
<b>DLS</b>	Realization of operations and/or trials
<b>CMM</b>	Realization of operations and/or trials
<b>RPP</b>	Final manuscript approval, Supervision
<b>LTC</b>	Realization of operations and/or trials, Supervision

## REFERENCES

1. Neligan PC. *Cirurgia plástica: extremidade inferior, tronco e queimaduras*. 3ª ed. Amsterdam: Elsevier; 2015. v. 4.
2. Ariyan S. The pectoralis major myocutaneous flap. A versatile flap for reconstruction in the head and neck. *Plast Reconstr Surg*. 1979 Jan;63(1):73-81.
3. Clemens MW, Evans KK, Mardini S, Arnold PG. Introduction to chest wall reconstruction: anatomy and physiology of the chest and indications for chest wall reconstruction. *Semin Plast Surg*. 2011 Feb;25(1):5-15.
4. Nahai F, Morales Junior L, Bone DK, Bostwick J. Pectoralis major muscle turnover flaps for closure of the infected sternotomy wound with preservation of form and function. *Plast Reconstr Surg*. 1982 Oct;70(4):471-4.
5. Zehr KJ, Reitmiller RF, Yang SC. Split pectoralis major muscle flap reconstruction after clavicular-manubrial resection. *Ann Thorac Surg*. 1999 May;67(5):1507-8.

\*Corresponding author:

**Fabiane Pinheiro**

Avenida Atlântica, 1144, Apto 2501, Centro, Balneário Camboriú, SC, Brazil.

Zip Code: 88330-009

E-mail: dra.fabi.pinheiro@gmail.com