








# Scalp reconstruction after wide resection of an angiosarcoma

## *Reconstrução de couro cabeludo após ampla ressecção de angiossarcoma*

MARIANA BRANDÃO MIQUELOTI<sup>1\*</sup>  
CARINE BARRETO GONZAGA<sup>1</sup>  
VANESSA DA SILVA AZAMBUJA RIBEIRO<sup>1</sup>  
ELMO GLÓRIA FILHO<sup>1</sup>  
RICARDO AGUIAR VILLANOVA FREIRE<sup>1</sup>

Institution: Hospital Central do Exército, Rio de Janeiro, RJ, Brazil.

Article received: January 22, 2019.  
Article accepted: July 8, 2019.

Conflicts of interest: none.

DOI: 10.5935/2177-1235.2019RBCP0239

### ■ ABSTRACT

**Introduction:** It is difficult to reconstruct the scalp due to its poor elasticity and presence of layers over a rigid convex structure. Different surgical techniques are used to repair defects that may develop due to several etiologies, such as trauma, deformities, and disease sequelae, especially cancer, as noted in the present case. Cutaneous angiosarcoma, a rare and extremely aggressive malignant vascular tumor that mainly develops in elderly individuals, is clinically characterized by the onset of rapidly evolving erythematous purple plaques. The treatment depends on disease extent. Most patients are treated with wide surgical resection and reconstruction. The objective is to report a case of reconstruction of a major scalp defect after an oncologic dissection performed at the Hospital Central do Exército in Rio de Janeiro. **Methods:** An autologous graft and dermal matrices were applied during two surgical periods till the damaged area was fully covered. **Results:** Satisfactory results were obtained after performing skin grafting surgery in the resected area. **Conclusion:** The autologous graft and dermal matrix proved to be a viable option for scalp reconstruction.

**Keywords:** Scalp; Reconstructive surgical procedures; Vascular tissue neoplasms; Cutaneous neoplasms; Rehabilitation

<sup>1</sup> Hospital Central do Exército, Rio de Janeiro, RJ, Brazil.

## ■ RESUMO

**Introdução:** O couro cabeludo é uma área de difícil reconstrução devido à sua pouca elasticidade e por sobrepor-se a uma estrutura rígida e convexa. Existem diferentes técnicas cirúrgicas para reparação dos defeitos, que podem ser produto de diversas etiologias, como: traumas, deformidades e consequência de doenças, principalmente oncológicas, como é o caso do paciente apresentada neste trabalho. O angiossarcoma cutâneo é um tumor vascular maligno raro e extremamente agressivo, que afeta principalmente idosos. É caracterizado clinicamente pelo aparecimento de placas eritemato-violáceas e de rápida evolução. O tratamento depende da extensão da doença. A maioria dos casos são tratados com ampla ressecção cirúrgica e reconstrução. O objetivo é relatar um caso de reconstrução de grande defeito do couro cabeludo depois de uma dissecação oncológica, realizado no Hospital Central do Exército (HCE) - RJ. **Métodos:** O caso foi tratado com enxerto autólogo e uso de matriz dérmica, em 2 tempos cirúrgicos, até a total cobertura da área lesionada. **Resultados:** Obteve-se resultado satisfatório após as cirurgias de enxertia de pele na área ressecada. **Conclusão:** O enxerto autólogo, juntamente a matriz dérmica mostrou-se uma opção viável na reconstrução do couro cabeludo. **Descritores:** Couro cabeludo; Procedimentos cirúrgicos reconstrutivos; Neoplasias de tecido vascular; Neoplasias cutâneas; Reabilitação.

## INTRODUCTION

One of the most important aspects of plastic surgery is reconstruction, and the treatment of major scalp defects after an oncologic dissection may present a considerable challenge for the plastic surgeon<sup>1,2</sup>. Factors such as major surgical resection with comorbidities lead to the emergence of such defects, thereby causing the need for reconstruction of the affected tissue.

Cutaneous angiosarcoma, a rare and extremely aggressive soft tissue sarcoma, is clinically characterized by the presence of erythematous purple, hemorrhagic and asymptomatic maculae, plaques, or nodules that resemble traumatic injuries that present rapid centrifugal growth and may show progressive infiltration and ulceration. Most affected patients have a history of pain and bleeding a few months after its onset<sup>3,4</sup>. Although the etiology of angiosarcoma is unknown, sun exposure is a proposed risk factor due to its low incidence in darker-skinned individuals<sup>5</sup>. Other associated factors are the occurrence of tumors at previous sites of shingles, telangiectatic nevi, other vascular and lymphatic abnormalities, arteriovenous fistulae, chronic osteomyelitis, and radiation and chemical exposure in addition to a history of trauma. However, most patients do not present these risk factors<sup>6,7</sup>.

Combining surgery and radiotherapy offers the best survival rate and is the most commonly applied treatment for this tumor. Surgery with wide margins (less than 2 cm according to the American Cancer Society) should be accompanied by assessment of biopsy samples from the lesion margins and at a distance due to the tumor's diffuse growth pattern<sup>11</sup>.

The need for wide margins generates extensive scalp defects and poses a challenge to the plastic surgeon considering the three-dimensional aspect of the skull, limited expansive capacity of the scalp tissue, and cosmetic aspect of the hair structure as well as demand for sufficient coverage of the cranial cavity in cases of concomitant cranial defects<sup>8</sup>.

A broad spectrum of reconstructive techniques is necessary. For this purpose, several reconstructive procedures have been described in the available literature, such as perforation of the outer table and use of skin grafts, local scalp flaps, pedicled flaps, and free flaps<sup>8</sup>.

An accurate assessment for determining treatment should also consider the risk of spreading neoplastic processes, patient comorbidities and age, defect size, number of anatomical planes involved, and, especially, the ability to preserve the periosteum and galea aponeurotica<sup>9</sup>.

## OBJECTIVE

We aimed to report a case of reconstruction of a major scalp defect after an oncologic dissection performed at the Hospital Central do Exército (HCE) in Rio de Janeiro, the technique applied, and the patient's progress thereafter.

## METHODS

This case was treated at the Plastic and Reparative Surgery Service/HCE in Rio de Janeiro. Patient V.A.S., a 71-year-old Caucasian male native of Rio de Janeiro, sought care at the Medical Clinic on February 27, 2018, for "lumps on the head" that had appeared six months prior to this visit.

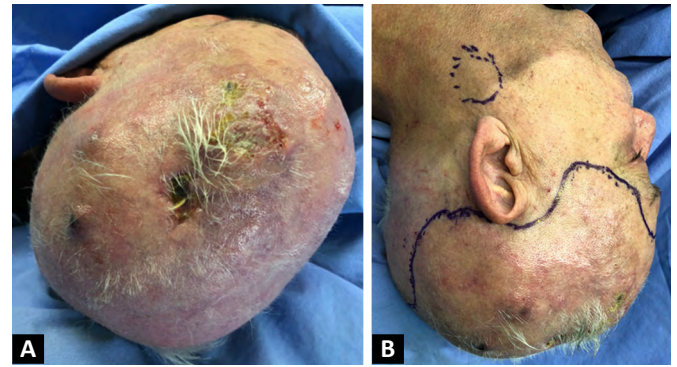
Upon examination, he presented with plaques on the scalp with infiltrative characteristics, some scaly eczema with normochromic nodules measuring about 1 cm in the left frontotemporal and right occipital regions, and no associated symptoms.

Myeloma was suggested as the diagnostic hypothesis, a cranial computed tomography (CT) scan and ultrasonography (USG) of the soft tissues were requested, and he was referred to the dermatology team.

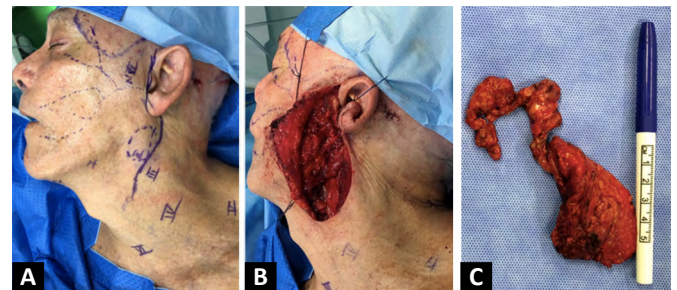
Two weeks later, the Dermatology and Head and Neck teams evaluated the case together. The cranial CT scan report evidenced contrast uptake throughout the entire lesion with no evidence of bone involvement, while the USG report suggested a hemangiomas lesion. A biopsy was scheduled, and preoperative examinations as well as the surgical risk of total excision of the lesion were requested.

The biopsy was performed on May 28, 2018, three months after the first consultation. The lesions had grown significantly by then. The largest measured approximately 4 cm at this time and had adhered to the deep plane. The report was released one month after the procedure with the diagnosis of angiosarcoma of the scalp.

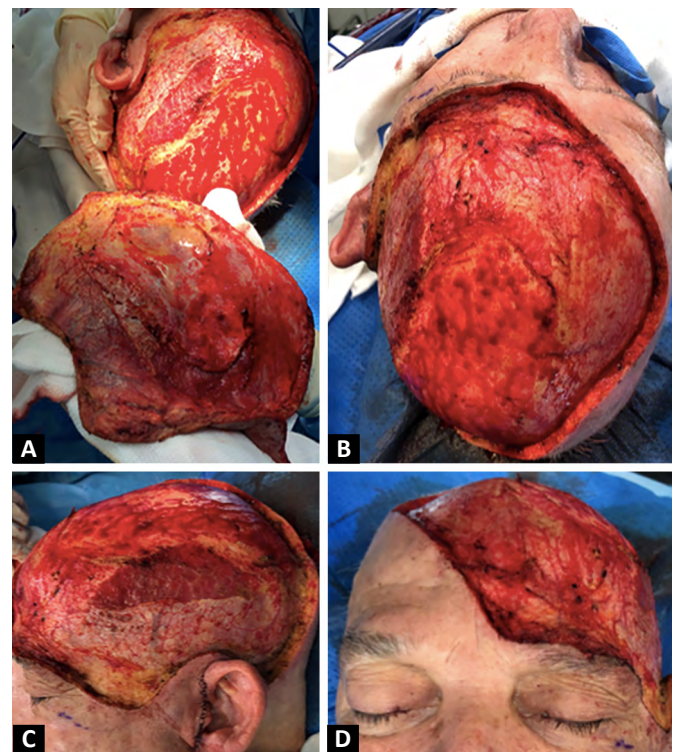
On July 5, 2018, the patient underwent the first surgical procedure (Figure 1) performed by the Head and Neck and Plastic Surgery teams consisting of draining the left cervicofacial region (Figure 2) and performing wide resection of the tumor (lesion and 2-cm margins of intact skin) in the left frontotemporoparietal scalp (Figure 3). A surgical specimen with uncompromised radial surgical margins and exiguous narrow margins was sent for frozen section. The neurosurgery team performed a left parietal resection of the outer table to define a safety margin at a depth given the possibility of bone involvement, thus generating a defect of the calvarium with an area of 12 cm × 8 cm without dural tearing (Figures 4A, 4B). The plastic surgery team performed the reconstruction with dermal matrices



**Figure 1.** Angiosarcoma of the scalp **A.** Nodular scalp lesions with an ulcerated area adherent to the deep plane; **B.** Demarcation of area to be resected and the cervical lymph node chain.

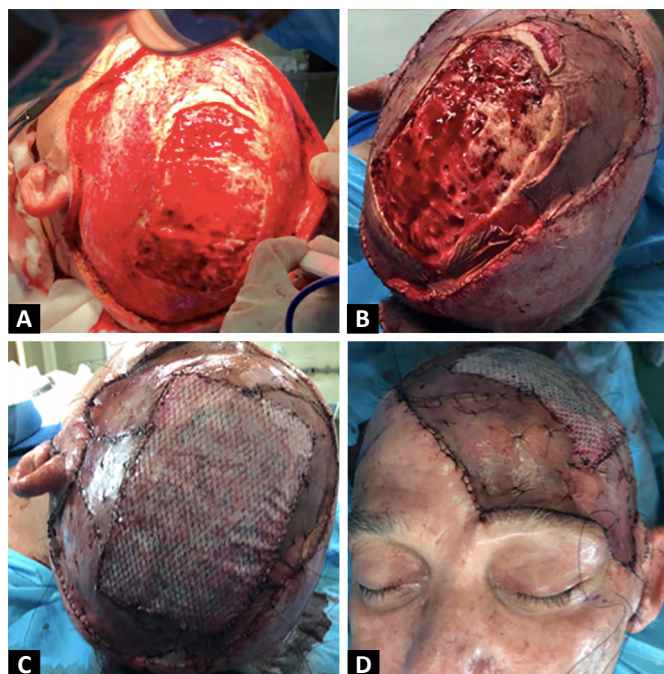


**Figure 2.** Cervicofacial drainage **A.** Layout of lymph node chains I-VI as well as facial nerve pathways and branches; **B.** Area of lymph node resection showing the preserved anatomical structures; **C.** Resected lymph nodes.



**Figure 3.** Resection of the surgical specimen **A.** Wide angiosarcoma specimen of the scalp with safety margins; **B.**, **C.**, and **D.** Top, left lateral, and frontal views, respectively, of the resected area.





**Figure 4.** Enlargement of the deep margin and graft + dermal matrix reconstruction **A.** Drilling of the outer table of the skull in a region where the lesion had adhered to the deep plane; **B.** Outer table with an area of 12 cm × 8 cm removed; **C.** Top view of reconstruction with partial-thickness skin autograft on the periphery and dermal matrix in the central region; **D.** Frontal view of the reconstruction.

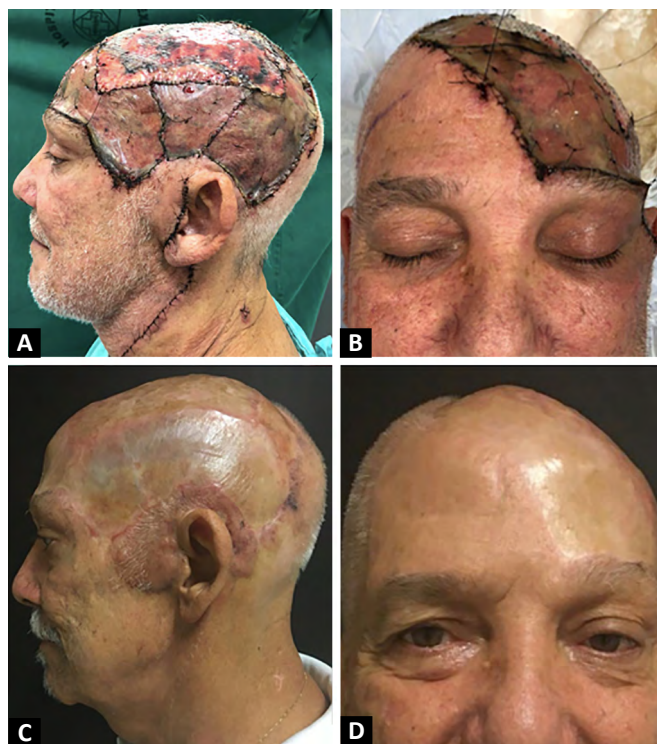on a region of bone exposure without the periosteum despite exposure of the diploë since the material was available, thereby optimizing healing time and graft acceptance in addition to providing a better post-reconstruction aesthetic appearance. In other areas of the defect, a partial-thickness skin autograft was placed (Figures 4C, 4D).

The graft was removed from a region of the left thigh with a dermatome and covered 70% of the exposed cranial area. Brown and turban dressings were applied to the grafted area. A drain was left in the region of cervical dissection. The patient was then referred to the postoperative intensive care unit.

## RESULTS

The patient showed good progress. The vesical delay probe and venous hydration were removed on the first postoperative day, and the patient was discharged to a room, with no restrictions on diet, and prophylactic clexane was prescribed.

On the second postoperative day, the cervical drain was removed. The patient remained in follow-up care by the Head and Neck, Neurology, and Plastic Surgery clinics until hospital discharge on the seventh postoperative day, when the dressings were removed and complete graft integration was evident (Figures 5A, 5B).



**Figure 5.** Results **A** and **B.** Left lateral and frontal views, respectively, of the postoperative reconstructed area in D7; **C** and **D.** Left lateral and frontal views, respectively, of the reconstructed area at 4 months after the second surgical period (partial-thickness skin graft in the dermal matrix area).

In early August, a histopathological report of the cervical lymphadenectomy and deep bone limits revealed five cervical lymph nodes, of which two were compromised by metastatic neoplasia. The deep bone limits presented no noteworthy histological changes.

The patient remained in outpatient follow-up care until August 22, 2018, when he underwent the second surgery for partial-thickness skin grafting in the dermal matrix area. The lower abdominal region was used as the donor area. The patient was discharged the same day and continues to receive follow-up care with the Plastic Surgery Service of the HCE; his scalp is healing well (Figures 5C, 5D).

Due to lymph node involvement, adjuvant radiotherapy was performed from October 1 to November 16, 2018.

## DISCUSSION

The clinical diagnosis of cutaneous angiosarcoma is challenging because it often presents as a bruise or a purple papule that can be mistaken for a benign lesion, such as a hemangioma.

In this case report, the location of the tumor on the scalp and the time between its onset and the moment that the patient sought medical attention made an early diagnosis difficult. The diagnosis

was confirmed by histopathological examination and an immunohistochemical panel. The main immunohistochemical markers were CD31, CD34, and the von Willebrand factor<sup>10</sup>.

Surgical resection with wide margins is the treatment of choice and usually associated with radiotherapy and/or chemotherapy with taxanes, ifosfamides, or anthracyclines. Antiangiogenic drug therapies (bevacizumab, sunitinib, and sorafenib) have exhibited promising results. A recent study reported that the use of propranolol associated with chemotherapy and radiotherapy exhibited good results<sup>10</sup>.

However, patient prognosis remains poor with a 5-year survival rate of less than 40%. Tumors smaller than 5 cm are associated with better prognosis; therefore, early diagnosis and effective treatment are essential<sup>10</sup>.

Due to the aggressive nature of the lesion, wide resection is performed, but it generates major defects with significant exposure of the calvarium, thus, posing a challenge to the plastic surgeons since local flap reconstruction is impossible<sup>8</sup>. There are several scalp closure procedures. Primary closure, which is used for defects smaller than 3 cm in diameter, is quick and results in limited alopecia. For larger defects, local, locoregional, and microsurgical flaps, local tissue expansion, and skin grafting may be used<sup>8</sup>. Regional flaps are increasingly less indicated, especially with the increased use of microsurgical flaps in recent years. The indications are restricted and include lack of hospital or professional infrastructure for making microsurgical flaps, need for large amounts of vascularized tissue for coverage, or patient undergoing palliative treatment<sup>9</sup>.

Free flaps are currently the main reconstruction procedure for medium or large defects in patients who are clinically able to tolerate a surgical procedure with a minimum duration of six hours. A great quantity of vascularized tissue for coverage is provided and allows for the correction of contour deformities. Negative factors include alopecia and changes in skin texture and color. The donor area should be chosen based on the defect type and skin characteristics. This requires the assistance of qualified professionals as well as availability of proper infrastructure<sup>9</sup>.

Controlled tissue expansion is an important reconstruction option for medium and large scalp defects. The sample should be positioned in the subgaleal plane and expanded until the flap is 20% larger than the defect to be corrected. The use of tissue expanders allows primary closure and less distortion of the capillary line in lesions that cover up to 50% of the scalp, which is not the best choice in this case due to the size of the defect to be covered<sup>9</sup>.

In this report, the skin graft was used because the healing time is short for the reconstruction of scalp defects larger than 9 cm as in the case described here since the compromised area was greater than 80%, which would make other surgical techniques difficult<sup>8</sup>. The graft is recommended for larger defects with a risk of flap infection and spread of neoplasia as well as those with an intact periosteum<sup>9</sup>.

The unwanted effects of graft reconstruction include alopecia, contour deformity with hypopigmentation, and donor site morbidity. When there is an exposed area wherein the periosteum is absent, there is an absolute contraindication for grafting as the bed is practically without vascularization. For this, we use the dermal matrix<sup>8</sup>.

In recent years, the use of acellular dermal matrices and other dermal substitutes has been used for patients who are unable to undergo long, complex treatments and in units that either have this material or the purchasing power for this material considering the high cost of dermal matrices. This new technology signals technical refinement in skin grafting cases, which usually occurs in two stages, dermal matrix inclusion and then skin grafting, once the bed has satisfactorily granulated<sup>9</sup>.

In this case report, although the area without periosteum presented diploë exposure, which would favor skin graft integration, we chose to apply the dermal matrix since it optimizes graft integration time and quality and favors the final aesthetic result.

## CONCLUSION

Here we demonstrated the study's clear objective by showing how scalp reconstructions remain a challenge for surgeons and that the techniques often used depend on both lesion size and unit experience.

In this study, we reported a case of a major scalp defect treated with an autologous graft and dermal matrices that achieved satisfactory results and good progress.

Due to the short postoperative period, it is not yet possible to assess the cancer prognosis.

## COLLABORATIONS

<b>MBM</b>	Writing - Original Draft Preparation, Writing - Review & Editing
<b>CBG</b>	Writing - Original Draft Preparation
<b>VSAR</b>	Writing - Original Draft Preparation
<b>EGF</b>	Supervision
<b>RAVF</b>	Realization of operations and/or trials, Supervision

## REFERENCES

1. Neligan PC, Gurtner GC. *Cirurgia Plástica. Princípios*. 3ª ed. Rio de Janeiro: Elsevier; 2013.
2. Marcondes CA, Pessoa SGP, Pessoa BBGP. Strategies in complex reconstructions of the scalp and forehead: a series of 22 cases. *Rev Bras Cir Plást*. 2016;31(2):229-34.
3. Morrison WH, Byers RM, Garden AS, Evans HL, Ang KK, Peter LJ. Cutaneous angiosarcoma of the head and neck: A therapeutic dilemma. *Cancer*. 1995 Jul;76(2):319-27.
4. García CM, González BT, Escobar SJ, Seco GAJ, Celorio PC, Rodríguez JR. Angiosarcoma pulmonar metastático. *An Med Interna*. 2004;21(1):27-30.
5. Glickstein J, Sebelik ME, Lu Q. Cutaneous angiosarcoma of the head and neck: a case presentation and review of the literature. *Ear Nose Throat J*. 2006 Oct;85(10):672-4.
6. Paulik TM, Paulino AF, McGinn CJ, Baker LH, Cohen DS, Morris JS, et al. Cutaneous angiosarcoma of the scalp: a multidisciplinary approach. *Cancer*. 2003 Oct;98(8):1716-26.
7. Cruz J, Popjristova-Popovaa E. Angiosarcoma de la cara y el cuero cabelludo. Estudio clínico-patológico. *Rev Cub Oncolog*. 1995;1:123-5.
8. Uliano EJM, Lucchese IC, Avila DFV, Brito MB, Vasconcelos ZAA, Ely JB. Reconstrução total de couro cabeludo: relato e experiência de dois casos. *Rev Bras Cir Plást*. 2018;33(0):53-55.
9. Romero RM, Arikat A, Machado Filho G, Aita CD, Oliveira MP, Jaeger MRO. Reconstrução de defeitos no couro cabeludo. *Rev Bras Cir Plást*. 2018;33(0):90-92.
10. Martinez DAS, Lyra MR, Cuzzi T, Macedo PM, Lima RB, Martins CJ. Angiossarcoma do couro cabeludo: relato de caso. *Medicina (Ribeirão Preto Online)*. 2017 Abr;50(2):134-138.
11. American Cancer Society (ACS). *Surgery for Soft Tissue Sarcomas*. New York: ACS; 2018. Disponível em: <https://www.cancer.org/cancer/soft-tissue-sarcoma/treating/surgery.html>

---

**\*Corresponding author:**

**Mariana Brandão Miqueloti**

Praia do Flamengo, 02 /603, Flamengo, Rio de Janeiro, RJ, Brazil.

Zip code: 22210-030

E-mail: miqueloti@gmail.com