







# Areolar reconstruction using eyelid skin

## *Reconstrução areolar com pele palpebral*

CARLOS ALBERTO JAIMOVICH<sup>1</sup>   
JOÃO PAULO FIGUEIREDO<sup>1\*</sup>   
WALTER MARROU<sup>1,2</sup>   
JOÃO PAULO VERBICARIO<sup>1</sup> 

Institution: Santa Casa de Misericórdia do  
Rio de Janeiro, RJ, Brazil.

Article received: May 2, 2019.  
Article accepted: October 21, 2019.

Conflicts of interest: none.

DOI: 10.5935/2177-1235.2019RBCP0227

### ■ ABSTRACT

**Introduction:** Breast cancer is currently the second most common neoplasm among women who undergo clinical treatments and breast-mutilating surgeries. Having beautiful and harmonious breasts is a legitimate right, so the concept of reconstructing the breast and nipple-areolar complex becomes important in female social reinsertion. This study aimed to present an effective technique of areolar reconstruction using free bilateral eyelid skin grafts and demonstrate its effectiveness through photographic results, comparison with previously described techniques, and patient satisfaction questionnaires. **Results:** The authors retrospectively evaluated 50 patients who underwent areolar reconstruction with eyelid skin grafts and other techniques performed by a single senior surgeon. Patients who underwent eyelid skin graft surgery did not achieve significantly different results from those who underwent other reconstruction techniques. Patients who underwent areola surgeries reported good satisfaction. **Conclusion:** The study revealed low complication rates and demonstrated that the use of eyelid skin is a good therapeutic option for areolar reconstruction.

**Keywords:** Nipples; Breast; Reconstruction; Eyelids; Skin .

<sup>1</sup> Santa Casa da Misericórdia, Rio de Janeiro, Rio de Janeiro, Brazil.

<sup>2</sup> Universidad Científica del Sur, Lima, Lima, Peru.

## ■ RESUMO

**Introdução:** Sabe-se que o câncer de mama é hoje a segunda neoplasia mais frequente entre as mulheres, as quais são submetidas desde a tratamentos clínicos até cirúrgicos mutilantes da mama. Ter mamas bonitas e harmoniosas é um direito legítimo, sendo assim o conceito de reconstrução mamária e do complexo areolopapilar, se torna importante na reinserção social feminina. Este estudo visa apresentar uma técnica eficaz de reconstrução areolar, utilizando enxerto cutâneo livre palpebral bilateral, demonstrando sua eficácia através de resultados fotográficos, comparação com outras técnicas já descritas e questionários de satisfação dos pacientes. **Resultados:** Foram avaliados, retrospectivamente, 50 pacientes operados de reconstrução areolar com enxerto de pele palpebral e outras técnicas já descritas, operados por um único cirurgião sênior. O grupo de pacientes operados com pele palpebral não obtiveram diferenças significativas dentro da análise de resultados, comparados com outras técnicas de reconstrução. Houve boa satisfação por parte dos pacientes, quanto ao resultado das cirurgias das aréolas. **Conclusão:** O estudo obteve baixos índices de complicações, apresentando-se como boa opção terapêutica, dentro do arsenal cirúrgico de reconstrução areolar.

**Descritores:** Mamilos; Mama; Reconstrução; Pálpebras; Pele.

## INTRODUCTION

Having beautiful and harmonious breasts is a legitimate right that cannot be overlooked<sup>1</sup>. Hence, the concept of breast reconstruction is within the scope of repair surgeries for a special group of patients, including those with breast cancer<sup>2</sup>.

Breast cancer remains among the most common cancers in women, trailing only non-melanoma skin cancer and representing about 25% of new cancer cases each year in the country<sup>3</sup>. International oncology, mastology, and plastic surgery entities combat breast cancer with the objective of restoring the patient's dignity and feminine identity<sup>4,5</sup>.

Among the various surgical breast reconstruction techniques, the following stand out: transverse rectus abdominis muscle (TRAM) flap developed by Hartrampf, Sheflan, and Black in 1982<sup>6</sup>; the large dorsal muscle flap (or latissimus dorsi) developed by Tanzini in 1906<sup>7</sup>; and breast expanders developed by Radovan in 1982<sup>8</sup>. Silicone implants and lipografting are surgical options with the same indications<sup>2</sup>.

Anatomically, it is important to note that the female breast has a conical shape with a circular base, and the apex is represented by a thinner skin structure, usually of a more hyperchromic color in relation to the rest of the body. The presence of the oral accommodation of the infant, called the nipple-areolar complex (NAC)<sup>1</sup>, is fundamental to a reconstructed

breast since it serves three functions: lactation, morphology (shape, size, and aesthetic proportions), and sexuality (sensitivity and sensuality). Therefore, when approaching the theme breast reconstruction, we must include that of the NAC<sup>2,9</sup>.

When approaching blepharoplasty, it is understood that the surgical procedure is an aesthetic and/or reparative resolution. This procedure consists of reconstruction of the tissues that cover the eyeball for numerous causes, such as congenital or tumor diseases, and flaccid disorders of eyelid structures related to age that affect or reduce the patient's visual field. However, in addition to functional repair, it also attenuates aging-related stigmas in the upper third of the face and is a cosmetic surgery in high demand by female patients, especially the elderly<sup>10,11,12,13,14</sup>.

Histologically, the eyelid skin is also similar to the areolar skin because it is thin and has an epithelium classified as stratified squamous keratinized with considerable melanin presence in the basal blade and the absence of hair, making it a good donating area for the creation of a "neo-areola"<sup>15</sup>.

Given such theoretical, statistical, and anato-histological concepts, the eyelid skin is an excellent graft option for areolar reconstruction, which we will demonstrate here by addressing aspects already mentioned in the literature, evaluating cases corrected using the proposed technique, and analyzing the psychological aspect of all patients studied.

## OBJECTIVE

### General Objective

To demonstrate a viable option for areolar reconstruction using bilateral total eyelid skin grafts.

### Specific Objectives

Analyze the applicability of the technique; and  
Compare its effectiveness to those of other reconstruction methods.

## METHODS

### Study Design

This retrospective descriptive clinical study included patients who underwent surgery performed by a male senior plastic surgeon and assistant professor of the plastic surgery service of the Santa Casa de Misericórdia of Rio de Janeiro, Brazil (former 38<sup>th</sup> ward).

### Data collection

We surveyed the data of operated patients from a databank of digitized medical records. All medical records with “breast reconstruction” or “reconstruction of the nipple-areolar complex” performed by the same senior surgeon in 1995–2015 were collected.

### Sample

The inclusion criteria were applied to the study sample, so our obtained data set included medical records of patients who underwent areolar reconstruction for whom complete pre- and postoperative color images (minimum 6 months of evolution) taken by the institution’s professional team of photographers or the senior surgeon, with surgical descriptions, medical evolution, and telephone contact information were available.

The exclusion criteria were incomplete medical records; black and white or absent photographs; absence of surgical descriptions or medical progress; absence of patients’ telephone contact; no areolar reconstruction during evolution; and different breast or areolar reconstruction after breast cancer.

### Photographic evaluation

Among the selected patients, 10 medical records from the “reconstructed with eyelid skin group” and

10 medical records from “reconstructed with other techniques group” were randomly chosen by digital drawing for a total 20 patients whose photographs (n = 20) were subjected to macroscopic analysis by professionals.

The digital cash program “*random.org – Random Integer Generator*” was used to make the random drawings of the study’s allocations.

The 20 photographs were presented to five male Brazilian plastic surgeons recognized as specialists by the Brazilian Society of Plastic Surgery (SBCP) with at least 10 years of experience in breast reconstruction. We queried their satisfaction with the neo-areolas without disclosing which were reconstructed using eyelid skin.

Among these images, photographs A, B, C, D, E, F, G, and H were used; I and J represented areolas reconstructed with eyelid skin; and L, M, N, O, P, Q, R, S, T, and U represented areolas reconstructed with skin of the upper internal region of the thigh and inguinal area. The evaluators graded each photographic result on a scale from 1 to 5 points in whole values for each photographic result considering three criteria: color; texture; and symmetry.

### Cases

In the results, five complete cases will be illustrated, showing pre- and postoperative photographic files (some perioperative) of patients who underwent treatment using the proposed technique of areolar reconstruction.

### Application of questionnaire

Telephone contact was made with the selected patients for the administration of a satisfaction questionnaire (Appendix 1) by the author. This questionnaire followed the SATIS-BR satisfaction scale.

The study included only patients for whom telephone number was available in the medical records. We did not attempt to call them more than five times in 24 hours. Patients for whom there was no longer a medical record or there was care of others due to absence did not participate in the study.

### Surgical description

The surgical descriptions of all studied patients were analyzed for safety. This sequence can be summarized as follows:

- 1) Dorsal decubitus;
- 2) Cushion under popliteus;
- 3) Calf electric scalpel plate;

- 4) Venoclysis in the contralateral upper limb to the mastectomized side;
- 5) General anesthesia;
- 6) Antisepsis with chlorhexidine;
- 7) Surgical drapes;
- 8) Infiltration with xylocaine 2% + adrenaline (1:200,000) + 0.9% saline solution + sodium bicarbonate;
- 9) NAC reconstruction as follows:  
 Resection of bilateral upper palpebral total skin band + hemostasis + running edge bearing suture with a 6-0 nylon;  
 Placement of resected skin in a solution of 0.9% saline solution;  
 Pitanguy's "Point A" marking in "neo-mama" + production of cutaneous flap for papilla reconstruction + decortication of areolar area;  
 Skin grafting of upper bilateral palpebral skin, filling of the entire decorticated circular area; and
- 10) Suturing with mononylon and monocryl + Brown dressing.

### RESULTS

Digital medical records were available for 74 patients; of them, 33 described areolar reconstruction using an eyelid skin graft and 41 described areolar reconstruction using other techniques, all performed by the senior surgeon as mentioned in the methodology.

Among the 74 related cases, 58 patients underwent post-mastectomy breast reconstruction, while 16 underwent NAC reconstructions due to total necrosis after reduction mammoplasties performed in the service and were, therefore, excluded.

After application of the exclusion criteria, 50 medical records were selected for the study; of them, 21 detailed reconstruction with palpebral skin and 29 involved reconstruction using other techniques.

Of the patients who underwent breast reconstruction (n = 50), 12 were treated with TRAM, 10 with pedicle flaps with large dorsal muscle (latissimus dorsi), and 28 with tissue expansion (Table 1).

**Table 1.** Number of cases by breast reconstruction type.

Técnicas de Rec. Mamária	Nº de casos
TRAM	12
L. Dorsi	10
Expansores	28

The results obtained in the macroscopic evaluation by five professionals were graded on a scale of 1 to 5 on 20 photographs (A to U) of areolar reconstructions (Table 2). Photos A to J, referring to the group of areolar reconstructions with palpebral skin, received scores of 3–5 points. Photos H to U, reconstructions using other techniques, also received scores of 3–5 points.

**Tabela 2.** Distribuição de notas de 1 a 5 pontos para resultados de reconstrução areolar com enxertos cutâneos de áreas doadoras variadas, através de fotografias

	Profes- sional 1	Profes- sional 2	Profes- sional 3	Profes- sional 4	Profes- sional 5
Photo A	4	4	3	4	4
Photo B	5	5	4	5	5
Photo C	5	4	4	3	5
Photo D	4	5	5	4	4
Photo E	4	4	5	5	4
Photo F	5	4	4	3	4
Photo G	4	4	5	4	4
Photo H	4	5	5	4	4
Photo I	5	3	3	4	3
Photo J	4	4	4	4	4
Photo L	3	3	3	3	4
Photo M	4	5	4	4	5
Photo N	5	4	4	5	4
Photo O	5	4	4	4	4
Photo P	4	4	3	3	3
Photo Q	4	4	3	3	3
Photo R	3	5	4	5	4
Photo S	4	4	4	5	4
Photo T	5	4	4	3	3
Photo U	3	4	3	3	4

The scores of the eyelid skin reconstruction group and the other graft techniques group compared the arithmetic mean of the groups and applied a parametric and non-paired test, Student's t-test, demonstrated that the evaluation values were equivalent between the eyelid skin reconstruction group and the other graft techniques group with no statistically significant intergroup difference (p = 0.1036) (Figure 1).

Among the results obtained from the evaluation of patient satisfaction, referring to the areolar results, of the 50 telephone numbers registered, only 32 patients

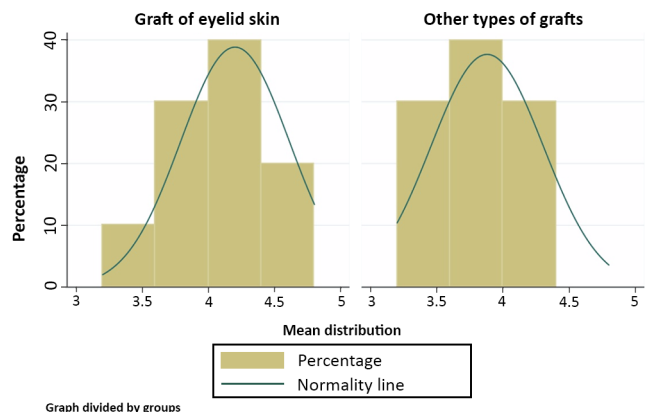


Figure 1. Distribution of mean graft assessment scores.

could be contacted. Of the contacted patients, 21 were “very satisfied,” 4 were “satisfied,” 4 were “indifferent,” and 3 were “dissatisfied.” None of the patients were “very dissatisfied.” All patients who were contacted and underwent reconstruction using eyelid skin answered “very satisfied” or “satisfied” (Figure 2).

### Satisfaction Questionnaire

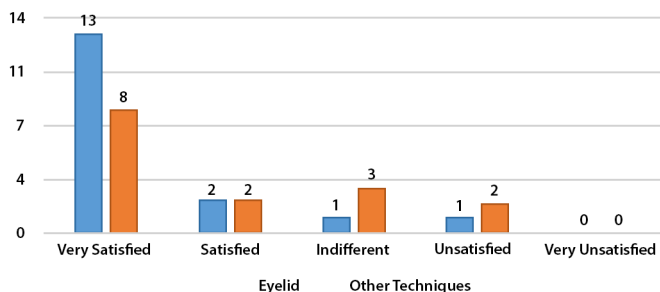


Figure 2. Distribution of patients by degree of satisfaction with areolar reconstruction result.

All surgery plans of breast reconstruction at the first surgery used one of the cited techniques; at the second surgery, symmetrization and reconstruction of the NAC were applied.

Among the complications, there were two cases of partial graft loss (less than 10% of the grafted area), one case of hypochromia, and one case of hyperchromia (Figure 3).

### Complications

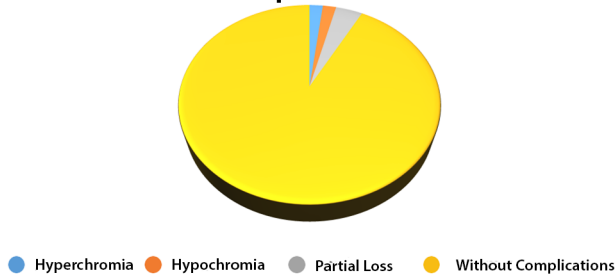


Figure 3. Distribution of complications of eyelid reconstructions.

Below are photos of five patients who underwent breast reconstruction and NAC reconstruction using total eyelid skin grafts (Figures 4–8).

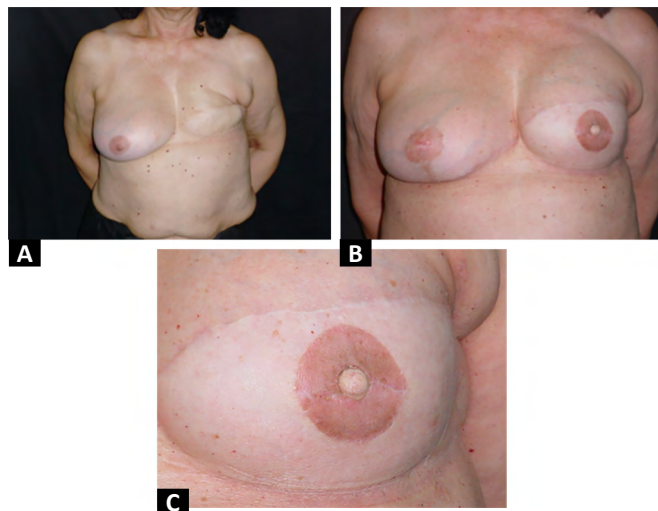


Figure 4A. Preoperative view of left breast planned for expander and nipple-areolar complex reconstruction. B Postoperative (5 months) view of left breast reconstruction with expander and nipple-areolar complex reconstruction using bilateral upper eyelid skin. C. Photo of nipple-areolar complex reconstruction using eyelid skin at 5 months postoperative showing assumed coloration.

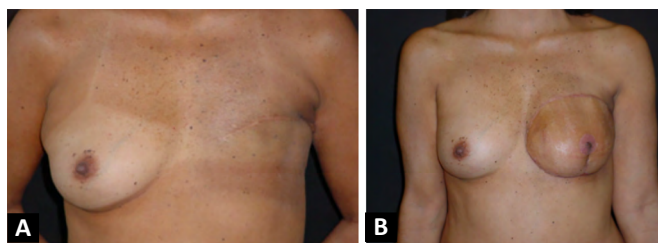


Figure 5A. Preoperative image of breast reconstruction of the left breast using a transverse rectus abdominis muscle flap. B. Postoperative image (3 months) of mammary reconstruction using an expander and nipple-areolar complex reconstruction.

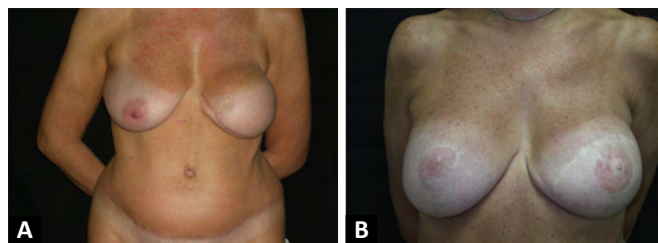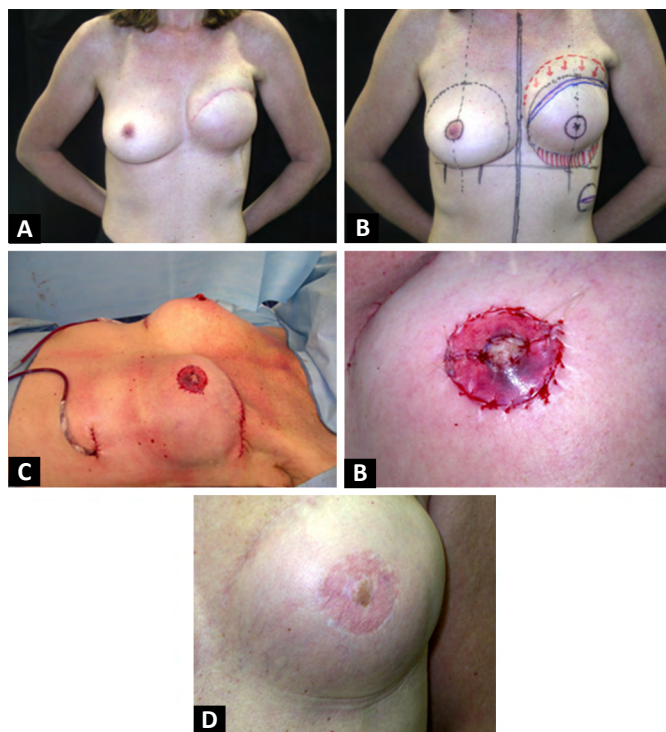


Figure 6. A. Preoperative image of second breast reconstruction using a left transverse rectus abdominis muscle flap. B. Postoperative image (4 years) of second breast reconstruction using a transverse rectus abdominis muscle flap on the left with nipple-areolar complex

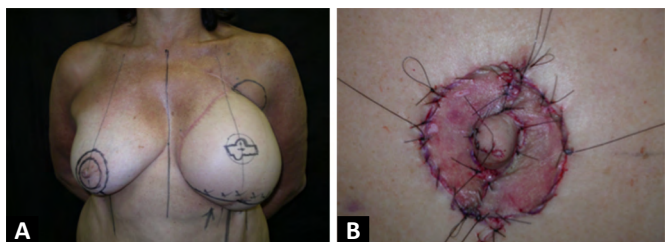
## DISCUSSION

With the evolution of studies on mastectomy surgical techniques, the great resections attributed by Halsted, gave rise to less radical surgeries associated with parallel therapies, such as chemotherapy and radiotherapy, saving the thoracic muscles, and several





**Figure 7.** A. Preoperative image of second breast reconstruction using a breast expander. B. Surgical plan of second breast reconstruction using an expander to achieve greater symmetry along with nipple-areolar complex reconstruction. C. Perioperative view of second time mammary gland reconstruction with an expander on the left demonstrating better symmetry and nipple-areolar complex reconstruction with eyelid skin. D. Perioperative image of nipple-areolar complex reconstruction using palpebral skin. E. Postoperative image (17 months) showing the nipple-areolar complex reconstruction using eyelid skin.



**Figure 8.** A. Surgical plan of second breast reconstruction using an expander to increase symmetry and reconstruct the nipple-areolar complex using left eyelid skin. B. Perioperative image demonstrating nipple-areolar complex reconstruction using eyelid skin.

times, mammary skin, as in the cases of subcutaneous skin saving adenomastectomy, when well indicated, and quadrantectomies<sup>16</sup>.

This evolution makes breast reconstruction surgeries using expanders comprise more space in the surgeon's arsenal of operative techniques, leaving the options of autogenic pedicle flaps as a second option due to the higher morbidity rate, which may explain the greater number of breast reconstructions using expanders<sup>8</sup>.

Although it is a topic of great discussion, it is clear that immediate or late post-mastectomy breast

reconstruction in two surgeries or a single surgery is performed in accordance with the surgeon's experience. The following factors are considered: 1) guarantee of a completely resected tumor; 2) guarantee of resolved cancer disease; 3) maximum gradual tissue expansion; 4) guarantee of rotated pedicle flap without suffering; and 5) surgical and anesthetic time. Of the patients evaluated for breast reconstruction, all underwent NAC reconstruction using eyelid skin in a second surgery. The senior surgeon who performed the procedures aimed to give volume to the breast-free area and then ensure NAC<sup>2</sup> symmetry and reconstruction.

The evaluations of photographs by professionals showed that areolar reconstructions with palpebral graft can present good morphological aspects compared to other reconstructions.

It cannot be said that this is a better surgical technique than the others since the results shown in the different photographs were equivalent. However, we can state that the proposed technique is capable of reproducing results as accepted as those of other areolar reconstruction techniques, making it one more option within the plastic surgeon's technical arsenal<sup>17</sup>.

Comparison of the scores assigned by professionals with the patients' answers in the satisfaction questionnaire revealed divergences in the results. One case achieved the highest score (5 points) by the professional and moderate satisfaction ("satisfied") from the patient. The same occurred inversely in two cases in which professionals assigned regular scores (i.e., 3 points) and the respective patients answered "very satisfied." These comparisons showed possible bias due to subjective analysis of the results, which may be linked to the professional's technical criteria and the patient's expectations.

Another important fact is the low complication rates, which remain at 2% for hyperchromia and hypochromia, or partial loss of less than 10% of the grafted area, seen in 4% of the studied cases. The proportions of skin grafts to total skin were compatible to those in the literature. It is also believed that after resection of the palpebral skin band resulting from superior blepharoplasty, refinement of the flap resecting connective tissue promotes better results in terms of texture and staining<sup>18,19</sup>. The psychological evaluation of selected patients revealed that the technique fills an important social function since it is directly linked to improved self-esteem and satisfaction with the results. Blepharoplasty performance, an aesthetic procedure, in favor of a final reconstruction of the female anatomy, enables the technique to provide an aesthetic improvement of its donor area, bringing signs of rejuvenation on the upper third of the face and achieving patient satisfaction<sup>11,19</sup>.

Blepharoplasty is considered one of the most common aesthetic plastic surgeries worldwide, with low rates of complications, most of which consist of hematomas and kemeses<sup>20</sup>. Nonetheless, Beier, Breuel, and Leffler, in 2009<sup>20</sup>, showed a very low rate of complications with good to very good aesthetic results for areolar reconstruction using compound flaps (local or contralateral nipple) with total grafts of eyelid skin<sup>21</sup>. In 2009, Kruavit<sup>21</sup> showed a complication rate of 3.8% post-blepharoplasty in 6215 patients over an 18-year period.

Among the study limitations, we cite the total sample number of medical records evaluated since it was not performed in a reference oncologic service for breast reconstruction surgeries and because only patients operated upon by a single professional were included. Photograph quality differed over 20 years (1995–2015) of follow-up. This is explained by technological advances and the existence of more modern resources, which can create a comparison bias among the professionals' grades. Another negative factor is the low number of specific studies on areolar reconstruction from its inception to the most commonly used techniques, hindering dissertations and subject development, unlike papillary reconstruction techniques.

The 16 records of areolar reconstruction with eyelid skin in patients with NAC necrosis, post-mammoplasty, were not included in the sample due to the possibility of bias of results considering graft receptor sites in different situations.

The satisfaction questionnaire was not applied to the entire sample number due to telephone contact being the methodology used, and some patients were not contacted because their telephone numbers were no longer valid. This may have influenced our results. This method is proposed for comparison of psychological characteristics before versus after procedures due to the high demand of this procedure, and we focused on social reinsertion<sup>22</sup>.

This study does not present itself as a pioneer in terms of technique description, but it proved to be more extensive with a greater number of cases and additional data than the study by Friedrich in 2013<sup>23</sup>.

## CONCLUSION

The results obtained in this study showed that the proposed technique is both feasible and effective with low complication rates and high satisfaction levels. Therefore, it provides another option in the surgeon's technical arsenal that can restore the physical integrity of women and proposes new studies for the presentation of an operative technique. In addition to

reconstructing an integral part of the breast, it produces aesthetic benefits in the donor area.

The proposed technique does not suffer interference, in terms of evolution, to any of the specific types of breast reconstruction and can be applied in any situation before surgical decision attributed by the professional.

Finally, this study concluded that, regardless of the theoretical division between aesthetic and reconstructive plastic surgeries, given the existence of scientific journals and specific international societies, these distances are dwindling. We note that in this technique, cosmetic and reparative principles were used to achieve better results.

## COLLABORATIONS

- CAJ** Analysis and/or data interpretation, Conception and design study, Final manuscript approval, Realization of operations and/or trials, Writing - Review & Editing
- JPF** Analysis and/or data interpretation, Conception and design study, Data Curation, Final manuscript approval, Formal Analysis, Realization of operations and/or trials, Writing - Original Draft Preparation
- WM** Analysis and/or data interpretation, Formal Analysis, Software, Writing - Review & Editing
- JPV** Conception and design study, Final manuscript approval, Supervision, Writing - Review & Editing

## REFERENCES

- Jaimovich CA. Mamillo hipertrófico – Contribuição ao estudo de sua reparação cirúrgica. A técnica em “W”. *Rev Bras Cir Plást.* 1982;72(2):123-130.
- Ribeiro RC, Saltz R. *Cirurgia da mama, estética e reconstrutora.* 2ª ed. São Paulo: Thieme Revinter; 2012.
- Ministério da Saúde (BR). Instituto Nacional de Câncer José Alencar Gomes da Silva (INCA). Estimativa 2016: incidência de câncer no Brasil [Internet]. Rio de Janeiro (RJ): INCA; 2015. Disponível em: <http://www2.inca.gov.br/wps/wcm/connect/tiposdecancer/site/home/mama>
- Silva LC. Câncer de mama e sofrimento psicológico: aspectos relacionados ao feminino. *Psicol Estud.* 2008 Abr/Jun;13(2):239-237.
- Cosac O, Camara Filho JPP, Barros APGSH, Borgatto MS, Esteves BF, Curado DMC, et al. Reconstruções mamárias: estudo retrospectivo de 10 anos. *Rev Bras Cir Plást.* 2013 Mar;28(1):59-64.
- Hartrampf CR, Schefflan M, Black PW. Breast reconstruction with a transverse abdominal island flap. *Plast Reconstr Surg.* 1982 Feb;69(2):216-25.
- Tanzini I. Spora il mio nuova processo di amputazione della mammella. *Riforma Medica.* 1906;22:757.
- Radovan C. Breast reconstruction after mastectomy using the temporary expander. *Plast Reconstr Surg.* 1982 Feb;69(2):195-208.

9. Cunha RJC, Jaimovich CA, Nogueira AJS, Lins DSMR, Nogueira CF. Reduced mastoplasty: modified Silveira Neto's tactical maneuver for ascension of the nippleareola complex. *Arq Bras Med Nav.* 1990 Sep/Dec;52(3):65-83.
10. Hahn S, Holds JB, Couch SM. Upper lid blepharoplasty. *Facial Plast Surg Clin North Am.* 2016 May;24(2):119-27.
11. Ishizuka CK. Autoestima em pacientes submetidas a blefaroplastia. *Rev Bras Cir Plást.* 2012 Mar;27(1):31-36.
12. Saito FL, Gemperli R, Hiraki PY, Ferreira MC. Cirurgia de ptose palpebral: análise de dois tipos de procedimentos cirúrgicos. *Rev Bras Cir Plást.* 2010;25(1):11-17.
13. Zanella PSM, Castro CC, Boechat CEJ, Aboudib JH. Tratamento de rugas glabellares por abordagem transpalpebral dos músculos corrugadores do supercílio. *Rev Bras Cir Plást.* 2006;21(2):97-101.
14. Lessa S, Sebastián R, Nanci M, Flores E, Sforza M. A síndrome do blefarocalásio e sua diferenciação com dermocalásio. *Rev Bras Cir Plást.* 2007;22(2):89-96.
15. Sand JP, Zhu BZ, Desai SC. Surgical anatomy of the eyelid. *Facial Plast Surg Clin North Am.* 2016 May;24(2):89-95.
16. Standring S. *Gray's Anatomia: A base anatômica da prática clínica.* 40a ed. Rio de Janeiro: Elsevier Ltda.; 2008.
17. Rosique MJF, Arantes HL. Reconstrução do Complexo Areolopapilar e refinamentos técnicos. In: Mélega JM, Viterbo F, Mendes FH, organizadores. *Cirurgia Plástica – os princípios e a atualidade.* Rio de Janeiro: Guanabara Koogan; 2011. p. 762-66.
18. Mélega JM, Viterbo F, Mendes FH. *Cirurgia Plástica – os princípios e a atualidade.* Rio de Janeiro: Guanabara Koogan; 2011.
19. Glavas IP. The diagnosis and management of blepharoplasty complications. *Otolaryngol Clin North Am.* 2005 Oct;38(5):1009-21.
20. Beier JP, Breuel C, Leffler M, Bani B, Beckmann MW, Horch RE, et al. Rekonstruktion des Mamillen-Areola-Komplexes durch lokale Lappenplastik oder "Nipple-sharing" in Kombination mit Vollhauttransplantation aus den Oberlidern. *Senologie.* 2009;6(2).
21. Kruavit A. Asian blepharoplasty: an 18-year experience in 6215 patients. *Aesthet Surg J.* 2009 Jul/Aug;29(4):272-83.
22. Morax S, Touitou V. Complications of blepharoplasty. *Orbit.* 2006;25:303-18.
23. Raaf CAL, Derks EAJ, Torensma B, Honig A, Vrounenraets BC. Breast reconstruction after mastectomy: does it decrease depression at a long-term?. *Gland Surg.* 2016 Aug;5(4):377-84.
24. Friedrich OL, Heil J, Golatta M, Domschke C, Sohn C, Blumstein M. Upper blepharoplasty for areola reconstruction. *Gerburshilfe Frauenheilkd.* 2013 Jul;73(7):720-23.

**\*Corresponding author:**

**João Paulo Figueiredo**

Avenida das Américas, 8585, Grupo 411, Barra da Tijuca, Rio de Janeiro, RJ, Brazil.

Zip code: 22793-081

E-mail: jpfigueiredo@gmail.com