






Increased nasal tip projection with “pseudo-flaps” using excess lateral cephalic alar cartilage

Aumento da projeção da ponta nasal com “pseudo-retalhos” obtidos dos excessos cefálicos laterais das cartilagens alares

ANTÔNIO ROBERTO BOZOLA^{1*} 
ALEXANDRE CARONI BOZOLA¹ 
CAMILA GARCIA SOMMER¹ 

Hospital de Base de São José do Rio Preto,
SP, Brazil.

Article received: October 23, 2018.
Article accepted: October 20, 2019.

Conflicts of interest: none

DOI: 10.5935/2177-1235.2019RBCP0223

■ ABSTRACT

Introduction: An increased nasal tip projection is sometimes necessary to achieve an appropriate proportion between nasal tip and dorsum. Numerous techniques and tactics have been described for this purpose using cartilaginous grafts obtained from the nasal septum, auricular concha, and costal cartilage. When this increased projection must be discrete, the use of excess lateral alar cartilage in the form of “pseudo-flaps” is proposed. **Methods:** In primary open rhinoplasty, excess alar cartilage, which is generally removed, was used to produce “pseudo-flaps”. The cartilages were folded over themselves in the form of a “French soldier’s suspender” over the domes of the alar cartilage and supported by interdomal soft tissue padding raised over the domus. It was kept detached, and relocated to the nasal tip and was contained by “pseudo-flaps” of the alar cartilages sutured there or covering the columella’s structural graft. Thirty-six patients underwent surgery using this technique. **Results:** Thirty-five had good results and one had a nasal tip abscess, caused by endonasal exposure to a non-absorbable suture, which was removed. A second intervention was then performed using a new auricular graft, but the result was still unsatisfactory. The “pseudo-flaps” method is relatively simple for those performing nasal surgery. **Conclusion:** The nasal tip can be projected discretely using the excess of alar cartilage “pedicled” in the domus.

Keywords: Nose; Rhinoplasty; Surgical flaps; Nasal cartilages; Nasal mucosa.

¹ Faculdade de Medicina de São José do Rio Preto, Hospital de Base, São José do Rio Preto, SP, Brazil.

■ RESUMO

Introdução: O aumento da projeção da ponta nasal às vezes se torna necessário para a obtenção de uma boa proporção entre ela e o dorso. Inúmeras técnicas e táticas são descritas com essa finalidade utilizando enxertos cartilagosos obtidos do septo nasal, concha auricular e cartilagem costal. Quando esse aumento deve ser discreto é proposto o uso dos excedentes de cartilagens alares laterais em forma de “pseudo-retalhos”.

Métodos: Em rinoplastias abertas primárias os excedentes das cartilagens alares, geralmente removidas, são utilizados como “pseudo-retalhos”, dobrados sobre si mesmos, em forma de “suspensório de soldado francês”, sobre o domus das cartilagens alares, tendo como acolchoamento de apoio os tecidos moles delas próprias, e o tecido mole interdomal, geralmente desprezado, que é liberado, e elevado para sobre os domus. Ele é mantido, descolado e deslocado para a ponta nasal, e fica contido pelos “pseudo-retalhos” das cartilagens alares ali suturados ou cobrindo o extremo do enxerto estrutural da columela. Foram operados com essa tática 36 pacientes. **Resultados:** 35 com bons resultados e um apresentou um abcesso de ponta nasal, provocado pela exposição endonasal de um fio de sutura não absorvível, que foi removido. Houve necessidade de uma segunda intervenção, utilizando novo enxerto auricular, ainda com resultado insatisfatório. **Discussão:** O método é relativamente simples para quem opera narizes. **Conclusão:** A ponta nasal pode ser discretamente mais projetada utilizando os excessos de cartilagens alares, “pediculadas” no domus.

Descritores: Nariz; Rinoplastia; Retalhos cirúrgicos; Cartilagens nasais; Mucosa nasal.

INTRODUCTION

For rhinoplasty, the treatment of the nasal tip and its proportion to the dorsum and columella are important aspects of facial esthetics. Open rhinoplasty, initially described by Rheti¹ in 1934 and Sperli² in 1988, which involved a trans-columellar incision and detachment of all of the dorsum's skin through an anterior incision into the alar cartilage as a continuation of the columella incision, has led to the development of new techniques for esthetic and functional treatment of the nose. Several strategies to further project the nasal tip have since been described, especially for bulbous tips, thick skin, and poorly defined globular tips³. Creating a new, esthetically appropriate nasal tip while protecting respiratory function^{4,5} should always be the goal of the surgeon.

Several techniques have been described, such as using the points between the domes of the alar cartilages⁶ and grafts that camouflage the appropriate tip^{7,8}. Stiffness⁹ of the nasal tip is also an important issue that concerns patients.

To create proportional harmony among the various nasal and facial segments, the nasal tip can be enlarged or reduced¹⁰. For increased projection, several procedures of columella structuring are described

using the nasal septum¹¹ or costal cartilage grafts¹² in secondary rhinoplasty when the septum is not present. Decisions regarding the incisions, resections, and cartilage grafts are of fundamental importance for the long-term end result of rhinoplasty¹³.

In cases where nasal tip projection is necessary without changes in the columella-labial angle, increased nasal tip projection is sometimes necessary to obtain a better dorsum-to-tip ratio. It is customary to use cartilaginous grafts taken from the nasal septum, the auricular concha, or leftover cartilage from the rhinoplasty. In cases where a greater projection is needed, costal cartilages, especially in the secondary nose, can be used. Several tactics have been proposed to achieve an increase in projection, depending on the need for graft volume and extension.

Sometimes, a slight increase in the projection of the tip without the need for other structural supports is necessary. Open rhinoplasty can be used if the lateral alar cartilage crosses¹⁴ and this excess alar cartilage can be used as crossed “pseudo-flaps” over the tip to increase its projection. Even if columella-structuring grafts are used, it is possible to cover the anterior end with this excess cartilage.

OBJECTIVE

The objective of this study was to present a technique for increased nasal tip projection using excess lateral cephalic alar cartilage shaped as “pseudo-flaps”.

METHODS

This was a retrospective analytical study done to present a new surgical technique to increase nasal tip projection.

Patients participating in the study came from a private practice and received clarification about the study and gave written informed consent. This work followed the principles of the Helsinki Declaration.

Surgical techniques

Rhinoplasty should always be an open technique (exo-rhinoplasty) in order to visualize and adequately expose the nasal tip and alar cartilages with their shapes, projections, surpluses, and asymmetries.

An adrenaline-containing anesthetic was administered at a concentration of 1: 80,000 throughout the nose and septum. A 90-degree V angled columella incision was made from the point where the pyramidal portion of the base transitions to the quadrangular portion, about half the height. The incision then extended along the anterior edge of the alar cartilages, following them through the medial and lateral parts up to near the bases of the lateral nasal wings (Figure 1).

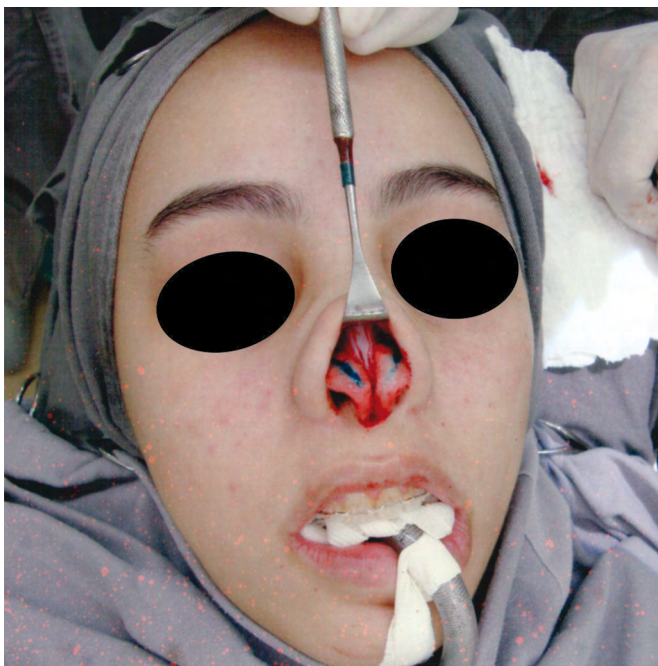


Figure 1. Incisions, detachment, exposition and marking of upper lateral alar cartilages excesses.

The nasal dorsum skin at the tip and laterally to the lateral segments of the alar cartilages were detached (Figure 1). The superior nasal dorsal bone along with the cartilage should be detached only as necessary according to the case.

Soft tissue in the space between the domes of the alar cartilage was removed from the bottom up, remaining a “pedicle” to the domus on either side. This can also be applied to one side or it can even be removed. The columellar segments of the alar cartilage (medial cross) were sutured together with non-absorbable thin threads or transfixated absorbable threads, including the skin and the columellar pseudo-mucosa on either side. The interdomal soft tissue on the domus, if not removed, can serve as a cushion to receive the excess alar cartilage.

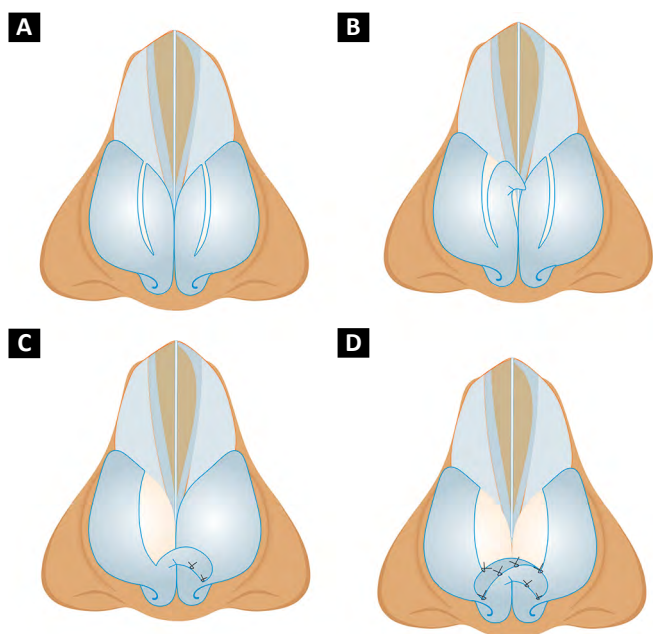
When there was a pending columella, a non-absorbable 6.0 thread suture was used to reduce the pen curvature of the alar cartilage domes on either side by transfixing them and approximating where the medial and lateral cartilage crossed. It is advisable to angle them with care so as not to transfix the nasal mucosa. This maneuver already slightly increased tip projection and corrected a pending columella.

The resection of excess cartilages was then marked (Figure 1). The incision went from the lateral to superior medial wall, until near the domus, detaching them from the nasal mucosa, and remained “pedicled” in the most cranial portion of the domus (Figure 2). This maneuver was facilitated by administering a subcutaneous anesthetic between the cartilages and nasal mucosa with a hypodermic needle.

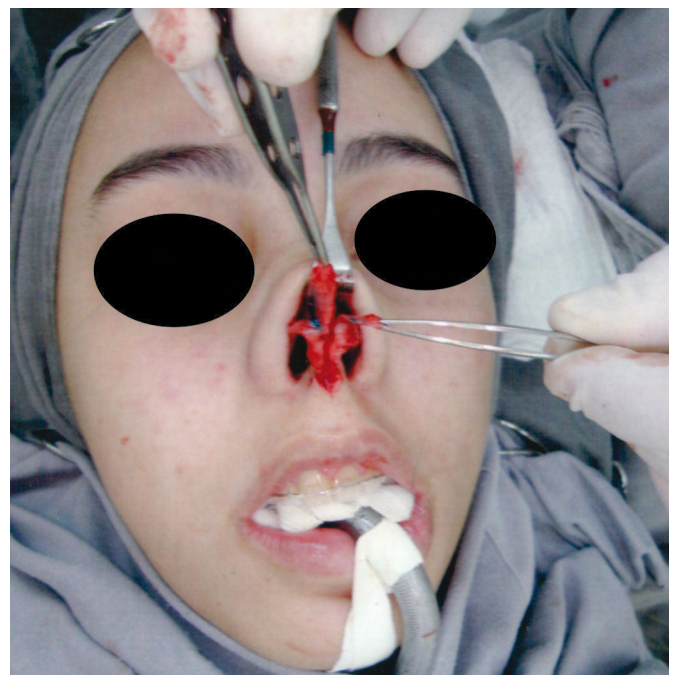

Figure 2. The “pseudo-flaps”.

The cartilage was then folded forward, crossed over the interdomal soft tissue present there, and sutured, or it was sutured freely if this had been removed. Thus, they made two loops in the form of a “French soldier’s suspender” (Figures 3 A, B, C, and D). Other reinforcing points with non-absorbable threads for projection and position suitability may be used when appropriate to achieve the desired shape. Cartilage should not be stripped of soft tissues and perichondrium, which support them as they fold, reinforce loops, and have greater resistance to stitches. In the end, the intersection and sutures resulted in the pseudo-flaps maintaining a quadrangular shape when viewed from the front, as proposed by Sheen⁷ in 1984.



Figures 3. A, B, C and D. Schemes of “pseudo-flaps”.

Care should be taken not to transfix the nasal mucosa and expose suture threads. Prior to suturing the domus, a useful maneuver to prevent transfixation is to apply a local anesthetic or saline solution between the nasal mucosa and alar cartilage under the region where the point will be given.

In cases requiring structural columella grafting, which is usually removed from the cartilaginous septum, the protrusion above the cartilage domes should be covered with “pseudo-flaps”, leaving the nasal tip more projected and with a more natural appearance (Figure 4).

The rest of the rhinoplasty is performed according to the needs of each case. Osseocartilaginous dorsum treatment has been previously done as well as osteotomies when necessary. To complete the

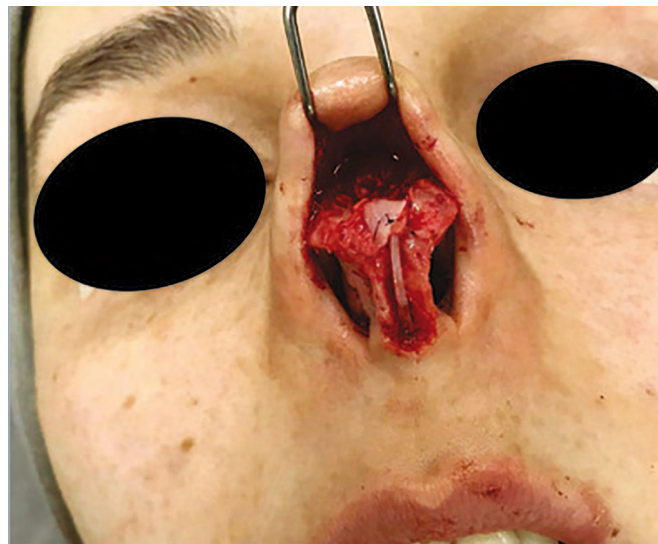


Figure 4. The “pseudo-flaps” sutured and crossed over the extremity of a structural columellar graft.

treatment, tampons, immobilization, and rhinoplasty dressings are used.

RESULTS

Thirty-six patients underwent rhinoplasty using the “pseudo-flap” technique, all of which required primary rhinoplasty. The surgeries were conducted between 2002 and 2017. Thirty-five patients were female and one was male, aged between 25 and 45 years. Patient follow-up occurred 5 years after surgery.

All patients underwent surgery using the technique described and only one of them did not show the desired increase in nasal tip projection due to abscess formation. This 50-year-old male patient underwent abscess drainage. Endonasal specular examination showed the nylon thread of the right alar cartilage end angulation suture had extruded into the nostril. The suture was removed and antibiotic therapy with abscess resolution was prescribed. However, the nasal tip projection was not adequate and remained asymmetrical, requiring further treatment with another graft was removed from the auricular concha, which was resorbed.

The remaining cases obtained adequate projection of the nasal tip and when questioned during the postoperative consultation, the patients considered their results esthetically satisfactory (Figures 5 A, B, C, D, E and F; Figures 6 A, B, C and D; Figures 7 A, B, C and D; Figures 8 A, B, C, D, E and F).

The results show postoperative noses with narrower bases, tapered and elevated nasal tips, and without bulbosity.

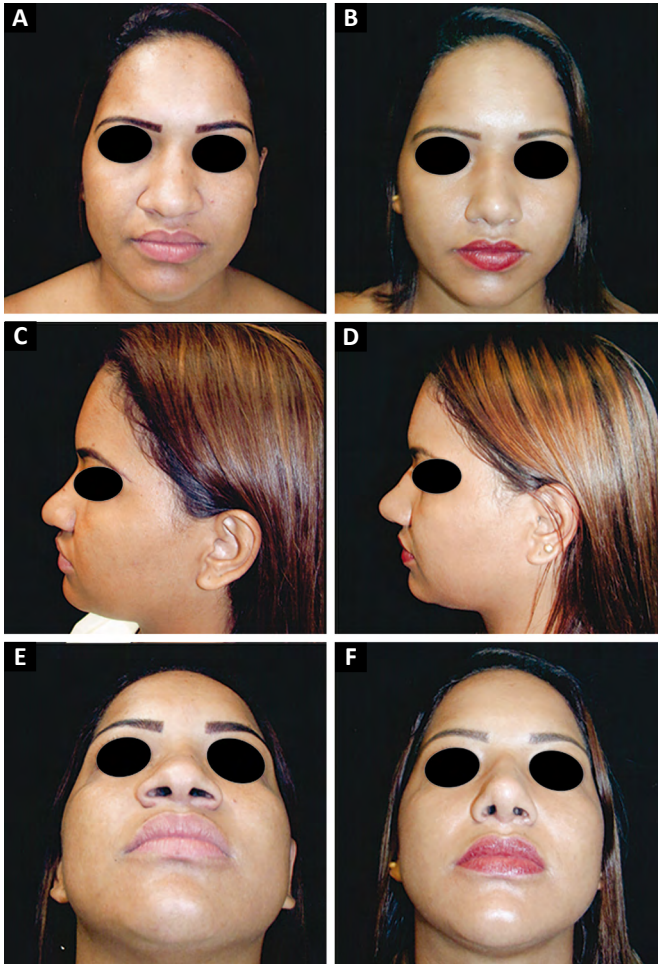


Figure 5. A. Preoperative. B. Postoperative. C. Preoperative. D. Postoperative. E. Preoperative. F. Postoperative.

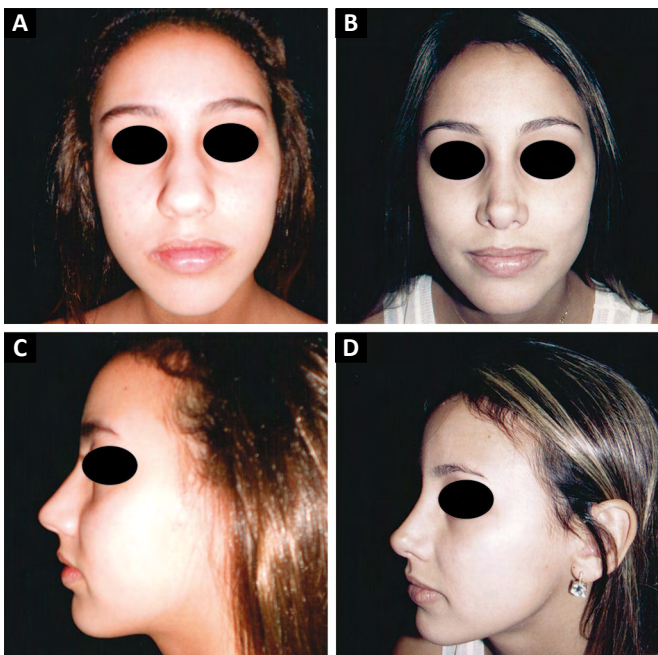


Figure 6. A. Preoperative. B. Postoperative. C. Preoperative. D. Postoperative.

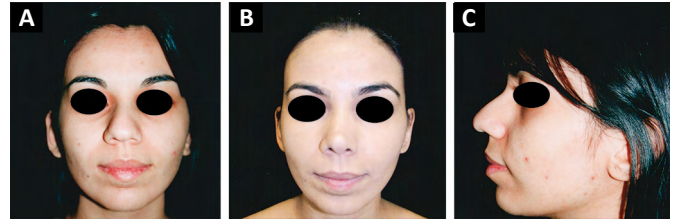


Figure 7. A. Preoperative. B. Postoperative. C. Preoperative.

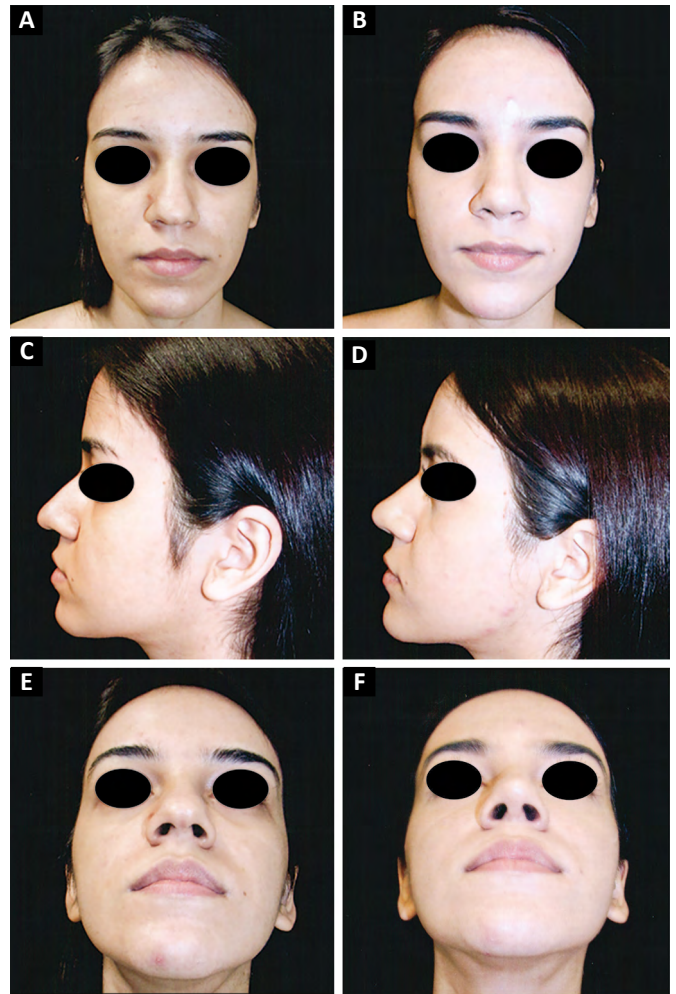


Figure 8. A. Preoperative. B. Postoperative. C. Preoperative. D. Postoperative. E. Preoperative. F. Postoperative.

DISCUSSION

One of the many aspects of an esthetically pleasing nose is a proper nasal tip position. While the cephalic tip creates a youthful appearance, the fallen tip is perceived as a sign of senescence. With aging, there is a loss of the nasal tip projection, which motivates patients to seek rhinoplasty¹⁵.

The literature defines the ideal nasolabial angle to be between 90 and 120 degrees and there are several techniques described to increase this angle and consequently increase nasal tip projection, which include modification of angles and alar cartilage dome

projections using sutures or cartilage grafts obtained from various sites¹⁵. The main disadvantages of using cartilage grafts compared to the method described when used alone, is the possibility of resorption, dislocation, and structural deformation without the guarantee of long-term preservation of the immediate positive postoperative results¹⁶.

However, even with the variety of resources available, this paper presents a new procedure that can be used in single tip projection or in combination with other procedures that have not achieved full projection as desired or planned¹⁷.

Loss of nasal tip projection, rotation, and length of the nose may be secondary to the loss of adequate nasal cartilage support. Irregularities of nasal tip, dorsal contour, and alar retraction are often caused by loss of cartilage¹⁷.

When the tip is not properly projected and shaped, and the alar cartilages are wide with excess soft tissue, they are almost always removed and discarded. In open rhinoplasty, reusing this excess cartilage without removing them from the site makes surgery simpler. The use of this excess should not affect their overlap with the triangular cartilage (second valves), since it uses only the excess that protrudes above the dorsum of the treated septum. With this methodology it is possible to design the nasal tip depending on the width, extension and thickness of the excess of the lateral alar cartilages.

If larger tip projections and/or a projection of the columellar base are needed, sometimes a structured graft preferably taken from the free nasal septum through septoplasty may be used, and its projection above the domes of the alar cartilages can be covered by “pseudo-flaps” (Figure 4).

The term “pseudo-flaps” was used because flaps are segments of vascularized tissues with a defined or random axial pedicle. In this case, the cartilage segment had no vascularization, but only a “pseudo pedicle”¹⁸.

The alar cartilage “pseudo-flaps” technique has the advantage of using local tissue, which allows for high-quality long-term shape and projection maintenance. The simplicity of the technique allows for a great deal of flexibility and creativity by the surgeon who, by obtaining “pseudo-flaps”, can rotate and fix them in the contralateral cartilage according to the needs of each case. This study reports on a simple, easy-to-perform and reliable technique that produces a nose with a natural look while maintaining long-term tip projection.

CONCLUSION

The technique described in the study was effective in improving nasal tip projection. A moderate increase in nasal tip projection was achieved using

the excess alar cartilage from the lateral portions, which would normally be removed and discarded. Satisfactory results were efficiently obtained for nasal tip projection.

This technique requires simple execution without major complications and is effective for nasal tip projection in select cases that do not require large volume increases. Additionally, for those requiring larger volumes, it can be added to other usual procedures with good results.

COLLABORATIONS

ARB	Analysis and/or data interpretation, Conceptualization, Data Curation, Investigation, Methodology, Project Administration, Realization of operations and/or trials, Supervision, Writing - Original Draft Preparation
ACB	Final manuscript approval, Realization of operations and/or trials
CGS	Analysis and/or data interpretation, Visualization, Writing - Review & Editing

REFERENCES

1. Rethi E. Operation to shorten an excessive long nose. *Rev Chir Plast.* 1934;2:85.
2. Sperli A. Exo-rhinoplastia: um novo conceito nas rinoplastias estéticas. *HFA Publ Téc Cient.* 1988 Jul/Set;3(3):261-84.
3. Costa LF, Muñoz AM, López D, Melo JC, Nahon MA. Exorhinoplastia para tratamento da ponta nasal bulbosa. *Rev Bras Cir Plást.* 2005;20(2):72-81.
4. Tugrul S, Dogan R, Koçak I, Eren SB, Ozturan O. Split cartilage resection of nasal dome: a solution to ptotic nasal tips. *J Craniofacial Surg.* 2015 Jul;26(5):e400-05.
5. Amali A, Sazgar AA, Jafari M. Assessment of nasal function after tip surgery with a cephalic hinged flap of the lateral crura: a randomized clinical trial. *Aesthet Surg J.* 2014 Jul;34(5):687-95.
6. Casanueva FL, Rosel P. Punto domal cefálico en rinoplastia: una nueva alternativa en contornos de punta nasal. *Rev Otorrinolaringol Cir Cabeza Cuello.* 2014;74(3):208-14.
7. Sheen JH. Spreader graft: a method of reconstructing the roof of the middle nasal vault following rhinoplasty. *Plast Reconstr Surg.* 1984 Feb;73(2):230-9.
8. Seneldir S, Nacar A, Kayabasoglu G. A novel method for smooth contouring of nasal tip: camouflaging alar tip graft. *J Craniofac Surg.* 2015 Oct;26(7):2171-3.
9. Aydogan F, Tastan E, Aydin E, Emir HK, Tuzuner A, Demirci S, et al. The effects of nasal base stabilization techniques on nasal tip rigidity. *Aesth Plast Surg.* 2014;38:288-94.
10. Apaydin F. Projection and deprojection techniques in rhinoplasty. *Clin Plastic Surg.* 2016 Jan;43(1):151-68.
11. Bitik O, Uzun H, Kamburoglu HO, Çalis M, Zins JE. Revisiting the role of columellar strut graft in primary open approach rhinoplasty. *Plast Reconstr Surg.* 2015 Apr;135(4):987-97.
12. Lopes DD, Andrade BGA, Vaena MLHT, Mota DSC. Enxerto de cartilagem costal em monobloco na rinoplastia. *Rev Bras Cir Plást.* 2011;26(3):453-60.

13. Abbou R, Bruant-Rodier C, Wilk A, Meningaud JP, Khan JL, Bosc R, et al. Open rhinoplasty: influence of incisions, alar resection, and columellar strut on final appearance of the tip. *Aesth Plast Surg.* 2014;38(6):4-9.
14. Patrocínio LG, Patrocínio TG, Barreto DM, Subhan YS, Patrocínio JA. Evaluation of lateral crural steal in nasal tip surgery. *JAMA Facial Plast Surg.* 2014 Nov/Dec;16(6):400-4.
15. Afroz PN, Carboy JA, Mendez BM, Rohrich RJ. Cephalic rotation of the nasal tip. *Plast Reconstr Surg.* 2019 Apr;143(4):734e-43e.
16. Kreutzer C, Hoehne J, Gubisch W, Rezaeian F, Haack S. Free diced cartilage: a new application of diced cartilage grafts in primary and secondary rhinoplasty. *Plast Reconstr Surg.* 2017 Sep;140(3):461-70.
17. Daniel RK. The nasal tip: anatomy and aesthetics. *Plast Reconstr Surg.* 1992 Feb;89(2):216-24.
18. Daher JC, Galdino MCA, Moura LG, Daher LMC, Ribeiro I, Santos GC, et al. Retalho de cartilagem alar para projeção da ponta nasal. *Rev Bras Cir Plást.* 2018 Jul/Set;33(3):374-381.

Corresponding author:*Antônio Roberto Bozola**

Avenida José Munia, 7075, São José do Rio Preto, SP, Brazil.

Zip code: 15085-893

E-mail: ceplastica@hotmail.com