




Single-stage nasolabial interpolation flap for reconstructing defects of the nose and inner corner of the eye

Retalho interpolado de sulco nasogeniano (RISN) em único estágio para reconstrução de defeitos nasais e de canto interno da órbita

JEFFERSON DI LAMARTINE GALDINO
AMARAL¹ 
RONAN CAPUTI SILVA DIAS^{1*}
AMANDA COSTA CAMPOS¹
RAFAEL SABINO CAETANO COSTA¹
SUELLEN VIEIRA DA-SILVA¹
ANDERSON DE AZEVEDO DAMASIO¹
JULDÁSIO GALDINO DE OLIVEIRA
JÚNIOR¹
JOSÉ CARLOS DAHER¹

■ ABSTRACT

Introduction: Interpolation flaps are effective surgical options for reconstructing skin defects in various areas of the body, including the face. The proposed flap does not require postoperative care with the pedicle exposed and can be performed in a single surgery. **Objective:** To evaluate the usefulness of the nasolabial interpolation island flap (NIF) for reconstructing nasal segments and the inner corner of the eye, as well as discuss improvements in its design and performance. **Methods:** In this retrospective study, medical records of patients with nasal defects that were repaired with a nasolabial interpolation flap were reviewed. All flaps were created with a subcutaneous tunnel to avoid pedicle exposure and prevent scar connection with the donor area and the defect. **Results:** Five patients aged 30–92 years were included. In all cases, intraoperative frozen biopsy revealed disease-free margins, indicating the extent of the resection. Basal cell carcinoma was found in four patients and squamous cell carcinoma in one. There were no complications such as postoperative bleeding or necrosis. Good functional and aesthetic results were achieved. **Discussion:** The NIF can help in the reconstruction of extensive defects of the nasal ala, tip, columella, and medial dorsum as well as the corner of the eye. We also highlight the more favorable aesthetic aspect of the pedicle in the interpolation island versus transposition flap. **Conclusion:** The single-stage NIF flap is a reliable option for reconstructing facial segments as it has good vascularization, can be performed in a single surgery, and can be used to cover places where few other reconstructive options are available. **Keywords:** Face; Surgical flaps; Skin diseases; Skin; Nose; Nose deformities; Acquired; Nose diseases; Eye socket.

Institution: Hospital Daher Lago Sul,
Brasília, DF, Brazil.

Article received: January 23, 2019.
Artigo aceito: June 22, 2019.

Conflicts of interest: none.

DOI: 10.5935/2177-1235.2019RBPC0000

¹ Hospital Daher Lago Sul, Brasília, DF, Brazil.

■ RESUMO

Introdução: Os retalhos interpolados são opções cirúrgicas eficazes para reconstruções de defeitos cutâneos em várias áreas do corpo, inclusive na face. O retalho proposto dispensa cuidados pós-operatórios com o pedículo exposto e pode ser realizado em tempo único. **Objetivo:** Avaliar a utilidade do retalho interpolado de sulco nasogeniano (RISN) em ilha, na reconstrução de segmentos nasais e do canto interno da órbita, bem como discutir refinamentos em seu design e execução. **Métodos:** Estudo retrospectivo de prontuários de pacientes com defeitos nasais ou de canto interno da órbita, e que foram reparados com retalho interpolado do sulco nasogeniano. Todos os retalhos foram confeccionados de maneira randômica, realizando-se túnel subcutâneo para evitar pedículo exposto e cicatriz que comunicasse a área doadora e o defeito. **Resultados:** cinco pacientes foram incluídos no estudo, com idade entre 30 e 92 anos. Em todos os casos foi realizada biópsia de congelação intraoperatória que revelou margens livres de doença, orientando a extensão da ressecção. O CBC foi encontrado em 4 pacientes e o CEC em um paciente. Não houve complicações como sangramento pós-operatório ou necrose. Bons resultados funcionais e estéticos foram alcançados em todos os pacientes. **Discussão:** Vale ressaltar a versatilidade do retalho nasogeniano interpolado, sendo capaz de auxiliar na reconstrução de defeitos extensos não apenas de asa, ponta e columela nasais, mas também de dorso e canto medial do olho. Destaca-se também o aspecto estético mais favorável do pedículo do retalho interpolado em ilha comparado ao de transposição. **Conclusão:** O RISN interpolado em único estágio é uma opção confiável na reconstrução de segmentos faciais. Apresenta boa vascularização, possibilidade de ser realizado em único tempo e pode ser utilizado para cobertura nos locais onde há poucas opções reconstrutivas disponíveis.

Descritores: Face; Retalho perfurante; Reconstrução; Sulco nasogeniano; Anormalidades da pele; Pele; Neoplasias; Órbita.

INTRODUCTION

Interpolation flaps are effective surgical options for reconstructing skin defects in various areas of the body, including the face, especially in cases in which graft use does not provide an acceptable aesthetic result¹.

The existence of different anatomical units with variable skin textures and thicknesses, the anatomical complexity of nasal structures and, in particular, the low mobility of the skin are the main factors that complicate the reconstruction of large nasal defects².

The nasolabial interpolation island flap (NIF) proposed in the present study is a versatile technique for facial reconstruction as the skin of the jugal region has characteristics similar to those of the nasal ala and dorsum, and it can be used in complex defects involving the inner corner of the eye with dimensions of up to 3 cm in diameter.

NIF is classified as an interpolation flap because it has a vascular pedicle based on a specific artery and/or its tributaries and distant donor area not adjacent to the

defect. Other interpolation flaps, such as the paramedian forehead flap (PFF), can repair distal nasal defects. An advantage of NIF over other nasal reconstruction flaps is that it preserves the alar groove, which is difficult to restore. A disadvantage of this flap is that hair can be transferred to the nasal ala in male patients in addition to posing a higher risk of young patients have more visible scars with less prominent nasolabial grooves. Although the scar of the donor area is generally tolerable but tends to improve over the years, nasolabial groove asymmetry may occur⁴.

The use of NIF requires significant anatomy knowledge, surgical planning, and skill. The pedicle is located close to the lateral portion of the alar groove and depends on the visibility of the myocutaneous surgical flaps and tributaries of the angular artery, which makes it a random flap¹.

OBJECTIVE

To evaluate the usefulness of the NIF performed in a single surgical session in the reconstruction of

nasal segments and the internal corner of the eye and discuss improvements in its design and performance.

METHODS

This retrospective study was conducted according to the principles of the Declaration of Helsinki and its amendments and involved medical record reviews of patients with defects of the nose or internal corner of the eye conducted at the Daher Lago Sul Hospital in Brasilia-DF between March 2017 and November 2018. Each patient underwent the surgical excision of skin tumors and repair with a single-stage NIF.

The following demographic and surgical data were evaluated: age, sex, tumor type, defect size and location, pedicle design, postoperative complications, and outcomes.

All patients signed an informed consent form. The flaps were randomly made based on the angular arteries, upper lip, infraorbital artery, and dorsal nasal artery. A subcutaneous tunnel (below the dermis) was created to avoid exposing the pedicle, prevent the scar from connecting with the donor area and the defect to be repaired (Figure 1), and create a skin island flap similar in size and shape to the defect in preparation for dissection of the pedicle (Figure 2).

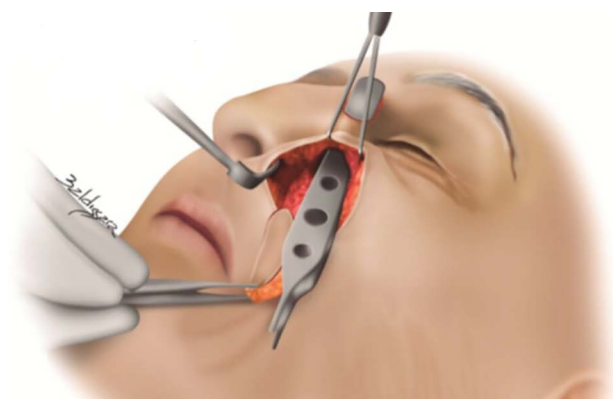


Figure 1. Creation of a subcutaneous tunnel (below the dermis) to avoid pedicle exposure and prevent the scar from connecting with the donor area and enable defect repair.

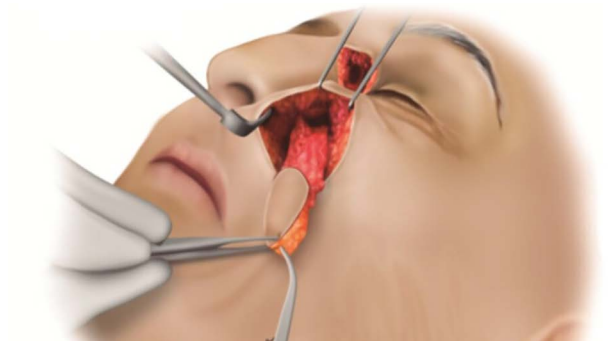


Figure 2: The creation of a skin island flap with a size and shape similar to the defect, followed by pedicle dissection.

RESULTS

Five patients (four women, one man) aged 30–92 years were included in the study. Two participants were smokers and two had a history of chronic sun exposure.

Local anesthesia was used in four patients, while general anesthesia was used in one patient. Two surgeries were performed in an outpatient setting, while three were performed in a hospital setting. All reconstructions occurred on the same day as the tumor removal, and an intraoperative frozen biopsy performed in all cases revealed margins free of neoplastic disease, indicating the extent of the resection. The size of the surgical defect ranged from 1.5 × 2.0 cm to 3.0 × 3.0 cm. Basal cell carcinoma was diagnosed in four patients and squamous cell carcinoma in one.

One patient had a defect located only in the nasal ala and underwent reconstruction with a single NIF, preserving at least 5 mm of tissue below the alar groove, which is an anatomical region of fundamental importance for nasal aesthetics; further, three patients had a defect in the inner corner of the eye and one had an extensive defect of the nasal dorsum, in which NIF was also performed.

There were no complications such as postoperative bleeding or necrosis. One patient, whose cellulite was treated with cefadroxil for 7 days and a dressing with essential fatty acids, ultimately had no aesthetic damage. One patient experienced epidermolysis of the flap and responded well to treatment with local massage and oral vasodilators (Figure 3). There were no cases of disease recurrence during the follow-up period.

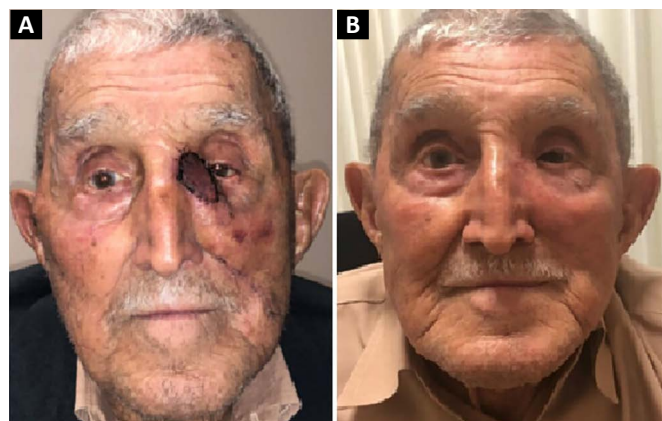

Figure 3: Epidermolysis of the flap that responded well to treatment with local massage and oral vasodilators. **A:** Postoperative day 7; **B:** Four-month postoperative follow-up.

Good functional and esthetic results were achieved in all patients, but the need for improvements was noteworthy, especially in one of the cases (Figure 4) in which liposuction and fat grafting were performed to correct skin relief irregularities. The follow-up time

was 1-18 months. Pre-, trans-, and postoperative photos are shown in Figures 5-9.

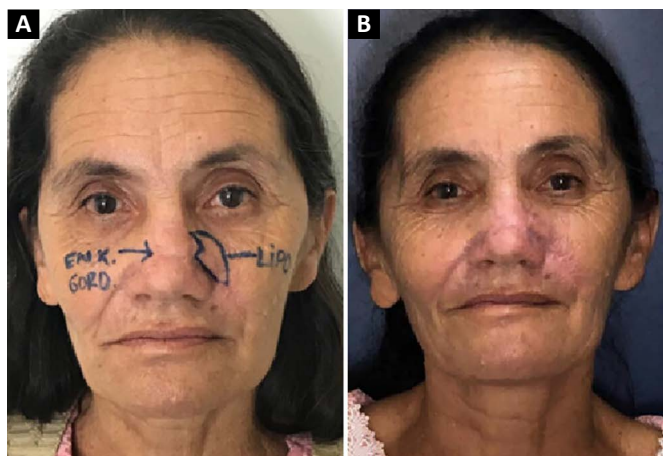

Figure 4: Patient underwent refinement with liposuction and fat grafting for correcting flap relief. **A:** Refinement planning in postoperative month 4; **B:** Postoperative month 7.

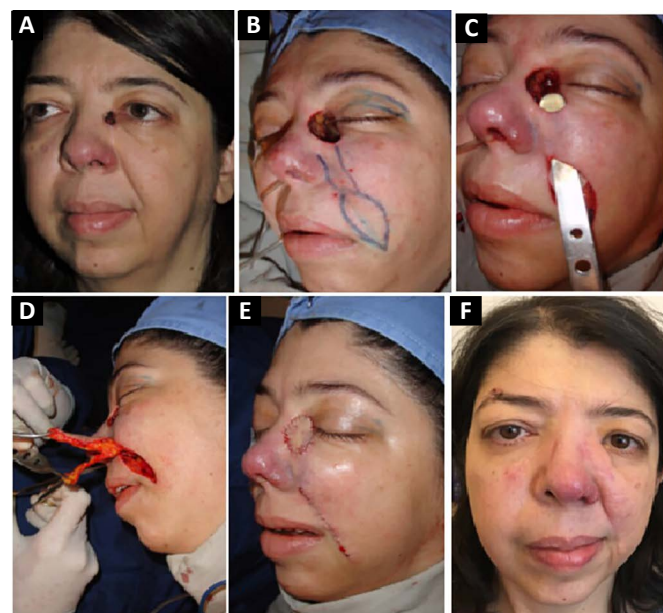

Figure 5: Case 1: 30-year-old patient with basal cell carcinoma in the medial corner of the left eye. **A:** Preoperative; **B:** Surgical planning; **C:** Subcutaneous tunneling; **D:** Flap dissection and refinement; **E:** Immediate postoperative result; **F:** Late 3-month postoperative period.

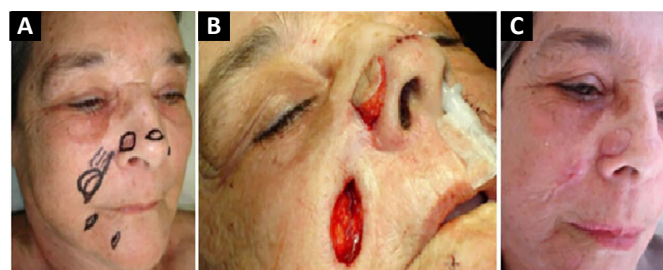

Figure 6: Case 2: 61-year-old patient with basal cell carcinoma in the right nasal ala. **A:** Surgical planning; **B:** Dissection and flap positioning; **C:** 45-day postoperative period with the flap still swollen.

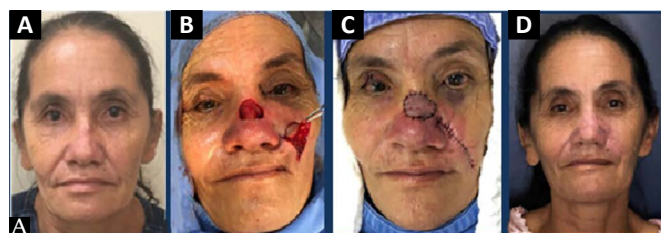

Figure 7: Case 3: 57-year-old patient with basal cell carcinoma in the nasal dorsum. **A:** Preoperative; **B:** Defect and flap creation; **C:** Immediate postoperative result; **D:** 7-month postoperative period and after refinement with liposuction and liposuction performed in the 4th postoperative month.

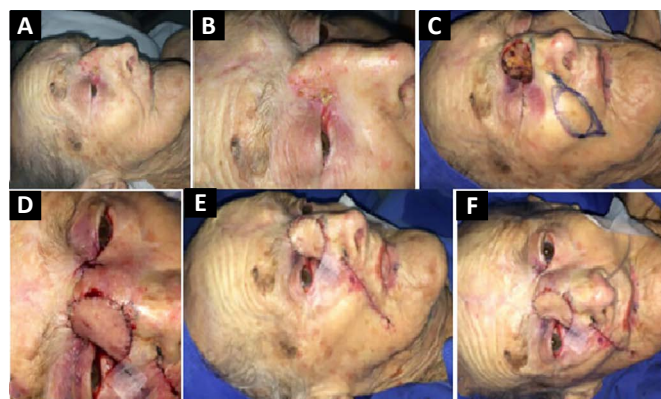


Figure 8: Case 4: 85-year-old patient with basal cell carcinoma in the medial corner of the right eye. **A and B:** Preoperative; **C:** Defect and flap planning; **C:** A significant defect is highlighted that may give rise to other ideas of more elaborate flaps such as the glabella and frontal median, but the nasolabial interpolation flap proved effective; **D, E and F:** Immediate postoperative.

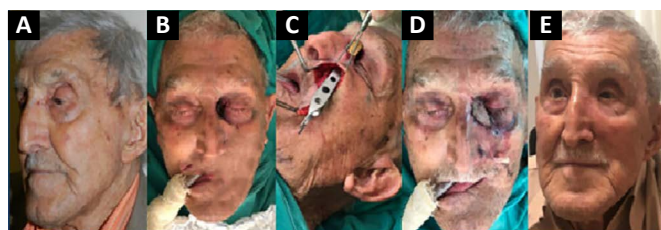

Figure 9: Case 5: 94-year-old patient with squamous cell carcinoma in the medial corner of the left eye. **A:** Preoperative; **B:** Defect and flap planning; **C:** Tunnel construction; **D:** Immediate postoperative period; **E:** 4-month postoperative period.

DISCUSSION

Interpolation flaps, by definition, are supported by donor skin areas that are not immediately adjacent to the surgical defect. They consist of pedicle skin flaps based on the rotation of a skin fragment around the axis of a vascular pedicle responsible for its irrigation. These flaps are viable surgical options for reconstructing surgical defects in areas without sufficient movable skin for primary closure or the preparation of conventional local flaps².

NIF irrigation invariably depends on different arterial vessels, such as the angular, superior lip, infraorbital, and dorsal nasal arteries. This arterial supply, in association with the great mobility of the jugal tissues, makes the nasolabial interpolation flap

a versatile procedure. Due to the rich vascularization provided, these flaps are associated with a very low risk of ischemia when they are used to close defects with diameters less than 3 cm¹.

These flaps can be used in association with local cartilage grafts to maintain the consistency and structure of the nasal pyramid and, consequently, airway permeability. The PFF is supplied by the supratrochlear artery and frequently used for reconstructing the nasal pyramid and alar defects; similarly, the retroauricular interpolation flap depends on multiple arterial branches and is a viable option for reconstructing hearing defects, particularly those located in the helix or anti-helix.

Nasal alae are common sites for skin cancer and often feature challenging surgical defects after resection. The repair options should be individualized for each patient and surgical defect. However, options promoting good functional and aesthetic results are limited for extensive and deep alar defects. Although there are other options for such defects, the NIF has the advantage of preserving the alar groove and camouflaging the scar in the nasolabial groove. The fibrofatty nature of the donor cheek area is another advantage of the NIF. The PFF, in turn, is thicker, more rigid, and less able to simulate the smooth and convex alar contour¹.

Functional preservation requires restoration of the inherent rigidity of the nasal ala with its aesthetic reconstruction being challenging due to the inelastic and sebaceous characteristics of the skin in this anatomical area. Skin grafts are often inefficient alternatives, even for small defects, and the lack of adequate adjacent tissue availability limits the success of skin flaps in alar reconstruction.

Better results can be achieved if the following principles are followed:

Respecting the anatomical limits and natural contours, the anatomical subunits should be individually reconstructed. Repair of the alar subunit is more appropriate when the primary surgical defect involves at least 50% of the alar surface. In such cases, surgical excision of all alar subunits and repair of the resulting defect may improve surgical outcomes, as the incisions are placed in areas of lower aesthetic prominence. In some cases, excision of the remaining alar skin may be problematic, particularly when the patient has sebum skin in the donor and recipient areas of the flap or when an additional excision of an alar subunit may increase the need for additional surgical procedures, such as a cartilage graft, to avoid the functional loss that results from deeper excision of the soft tissues.

When reconstructing a defect that involves the lateral ala and the medial cheek, the surgeon must realize that the visual distinction between these two

subunits must be ensured to maintain aesthetics and contours in the central region of the face.

In addition to respecting the anatomical limit between the lateral ala and the medial cheek, the concavity between these two anatomical units should be preserved. Pedicle flaps that cross the border between the cheek and the nose may be aesthetically inefficient. It is an inherent trend for many flaps to offer excessive volume restoration and eliminate shading in this transition area, subtly limiting aesthetics.

Special attention should be given to the full restoration of the soft tissues that characterize the insertion of the lateral ala in the apical corner of the upper lip. The ala is a somewhat cylindrical but a significantly curved unit at its insertion point in the apical corner of the upper lip. The restoration of this lateral curvature is particularly important in the previous evaluation of the patient.

A fundamental concept in alar reconstruction involves adequately sizing the pedicle flap during its creation. Alae that are a few millimeters too wide produce unsightly results. Flap thinning increases the probability of ischemic failure, so the surgeon must always balance the desire to offer a thin and malleable flap with the need to protect flap perfusion. Adherence points can be used to increase contact with the underlying wound bed, improving flap contour and reducing the need for further revision aimed at managing excessive volume.

It is desirable, but not always possible, to avoid intranasal manipulation consisting of making unnecessary resections. Several nasal and septal mucosa flaps can be used to replace the resected alar mucosa. However, skin from flaps folded on themselves is often used to reconstruct the nasal lining⁴.

The principle of anatomical subunits is a fundamental concept in reconstruction. If a defect involves more than half of the subunit, excising the rest and restoring the entire subunit can provide better results. However, this principle is not valid for all situations. With careful selection, some defects can be repaired without complete subunit resection. Burget and Menick (1994)⁵ revolutionized nasal reconstruction surgery by introducing the concept of aesthetic subunits of the nose based on differences in skin elasticity, color, contour, and texture, contributing to the improvements in nasal surgery. The subunits described included the roof, dorsum, lateral, tip, alae, and columella⁵.

When different subunits are affected, independent closure options should be considered. This is especially true for subunits separated by concavities such as the alar groove. The attempt to restore the nasal ala and medial cheek with the NIF may result in a larger nasal ala and blunt the alar groove. Small adjacent defects in these areas should be allowed to heal by second

intention, which contributes to the recreation of the alar groove concavity. A cheek advancement flap is a good option for medium to large defects. The NIF provides soft tissue thickness but not structural support. Nasal mucosa (lining) and cartilage are structures that must be intact or be restored before NIF use.

The NIF pedicle in this study is myosubcutaneous (the proximal epidermis and dermis of the pedicle are completely incised and released), which makes it an island flap, releases the restrictions caused by the epidermis and dermis, and reduces tension and torsion in the pedicle. Furthermore, the island design allows the dissection of wider pedicles with smaller proximal triangles, which increases mobility. Potential complications of NIF include postoperative bleeding, inadequate healing, infection, dehiscence, distortion of free margins, and necrosis².

It is worth highlighting the versatility of the interpolation nasolabial flap, which can aid in the reconstruction of extensive defects of the nasal alar, tip, and columella, its main indications, as well as the back and medial corner of the eye. In the nasal dorsum, the most commonly used flaps are the extended glabellar, bilobed, and rhomboid; that used in the medial corner of the eye and the nasal roof is the glabellar.

A disadvantage of the traditional interpolation flap is the need for two or three surgical sessions, the first for lesion removal and flap preparation, the second for pedicle sectioning, and the third for fine adjustments of the flap⁶. The flap in this study consists of a single stage (avoiding a bloody area) in which its pedicle is inserted into a tunnel created in the subcutaneous region. In the late postoperative period, improvements such as liposuctions/lipectomies or w-plasties/z-plasties may be necessary to reduce flap volume and correct retractions. The more favorable aesthetic aspect of the interpolation island flap pedicle versus the transposition pedicle is also worth mentioning.

CONCLUSION

Single-stage NIF is a reliable option for the reconstruction of facial segments (nasal and inner

corner of the eye) after oncologic surgery. It has good vascularization, can be performed in a single stage, and can be used in places where few reconstructive options are available. The proper surgical planning and meticulous technique can achieve good aesthetic and functional results.

COLLABORATIONS

JDLGA	Analysis and/or data interpretation, Final manuscript approval, Realization of operations and/or trials
RCSD	Analysis and/or data interpretation, Conception and design study, Data Curation, Writing - Review & Editing
ACC	Analysis and/or data interpretation
RSCC	Analysis and/or data interpretation
SVS	Analysis and/or data interpretation
AZD	Analysis and/or data interpretation
JGOJ	Analysis and/or data interpretation
JCD	Final manuscript approval

REFERENCES

1. Cook JL. The reconstruction of the nasal ala with interpolated flaps from the cheek and forehead: design and execution modifications to improve surgical outcomes. *Br J Dermatol.* 2014 Sep;171(Suppl 2):29-36. DOI: <https://doi.org/10.1111/bjd.13206>
2. Andrade P, Serra D, Cardoso JC, Vieira R, Figueiredo A. Melolabial fold interpolated flap for reconstruction of complex nasal defects. *An Bras Dermatol.* 2012 Sep/Oct;87(5):762-5. PMID: 23044572 DOI: <https://doi.org/10.1590/S0365-05962012000500016>
3. Ramos RFM, Spencer L, Girelli P, Meneguzzi K, Martinelli A, Uebel CO. Total nasal reconstruction: use of the "sandwich technique" during residency. *Rev Bras Cir Plást.* 2017;32(2):174-180. DOI: <https://doi.org/10.5935/2177-1235.2017RBCP0028>
4. Cerci FB, Nguyen TH. Nasolabial interpolation flap for alar reconstruction after Mohs micrographic surgery. *Surg Cosmet Dermatol.* 2014 Jan;6(2):113-20.
5. Burget GC, Menick FJ. Aesthetics, visual perception, and surgical judgment. In: Burget GC, Menick FJ, editors. *Aesthetic reconstruction of the nose.* St. Louis: Mosby; 1994. p. 1-55.
6. Sakai RL, Tavares Júnior LCV, Komatsu CA, Faiwchow L. Nasolabial interpolation flap for nasal alar reconstruction after skin tumor resection. *Rev Bras Cir Plást.* 2018;33(2):217-221.

*Corresponding author:

Ronan Caputi Silva Dias

SHTN, Trecho 2, Lote 3, Bloco E, Apartamento 206, Life Resort, Brasília, DF, Brazil.

Zip Code: 70800-230

E-mail: ronancaputidias8@gmail.com