

# Advances in Profilemetric Study Applied to Facial Rejuvenescence

Diomar Flores, MD<sup>1</sup>

Aymar Sperli, MD<sup>2</sup>

José Octávio Gonçalves de Freitas, MD<sup>3</sup>

Alael de Paiva Lino, MD<sup>4</sup>

- 1] Resident of the Integrated Plastic Surgery Services – MEC/SBCP - Hospital Ipiranga - São Paulo – Brazil.
- 2] Headmaster of the Integrated Plastic Surgery Services - MEC/SBCP – Hospital Ipiranga São Paulo – Brazil.
- 3] Teaching Coordinator of the Integrated Plastic Surgery Services - MEC/SBCP Hospital Ipiranga - São Paulo – Brazil.
- 4] Head Professor of Orthodontics of Universidade Camilo Castelo Branco.

Work performed at Serviços Integrados de Cirurgia Plástica – Official postgraduate course, MEC-SBCP, Hospital Ipiranga – São Paulo.

Address for correspondence:

Diomar Flores, MD

Av. Cidade Jardim, 993  
01453-000 – São Paulo – SP  
Brazil

Phone: (55 11) 3845-1279  
e-mail: sperli@imedical.com

**Keywords:** Profilemetry; profileplasty; cervical-mentonian angle.

## ABSTRACT

*The anterior region of the neck is an area in which Plastic Surgery has been showing advances in aesthetic studies, with several surgical techniques and approaching ways for its performance. In spite of its great importance, the topographic study and outlining analyses of the cervical region have rarely deserved special attention.*

*In this paper, the author presents a new focus in facial profilemetry. Upon radiological studies, points, angles and coordinates are outlined, which aids in the evaluation of patients with abnormalities at the submentonian, submandibular and anterior cervical regions, providing a new tool to successfully attain the profilemetry indicated. An abnormality degree classification in this region is also presented.*

## INTRODUCTION

Beauty and harmony, size and balance of the contours: in order to have a clear idea of these concepts, it is quite important that the plastic surgeon be furnished with a good sense of proportion.

For centuries, the stereotypes of beauty for the human body have motivated several researchers. The interest for the aesthetic facial aspects goes back to

the most ancient civilizations<sup>(1)</sup> – in all of them we may observe its importance, since the manifest in the beaux arts field (Figs. 1a, 1b, 1c, 1d and 1e). Leonardo Da Vinci<sup>(2)</sup> was the maximum exponent, and with his anatomical studies and detailed sketches he provided conclusions, some of them accepted worldwide up to date (Figs 2a, 2b and 2c). Other researchers disagreed with the universal facial measures application<sup>(3)</sup>, defending an individuality concept.



Fig. 1. (A, B, C, D, E) – Sculptures of different ages and civilizations are observed, in which the importance of the outline and profilemetric traces are appreciated.

Fig. 1. (A, B, C, D, E) – Observam-se esculturas de diferentes épocas e civilizações, nas quais se aprecia a importância da silhueta e traços perfilométricos em cada uma delas.

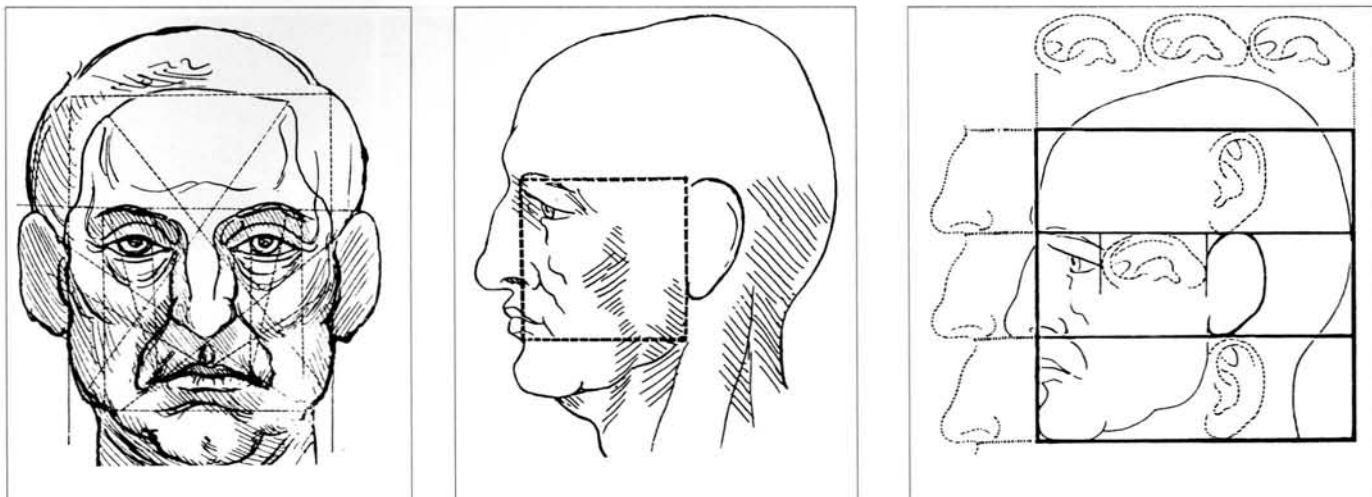


Fig. 2 – Drawings and traces made by Leonardo Da Vinci: A) Traces that relate, in a geometrical way, different facial structures. B) “Leonardo’s square”, which involves other anatomical points. C) Some facial profilemetry stereotypes.

Fig. 2 - Desenhos e traços realizados por Leonardo Da Vinci: A) Traços que relacionam de maneira geométrica diferentes estruturas faciais. B) “O quadrado de Leonardo”, que envolve outros pontos anatômicos. C) Alguns cânones de perfilometria facial.

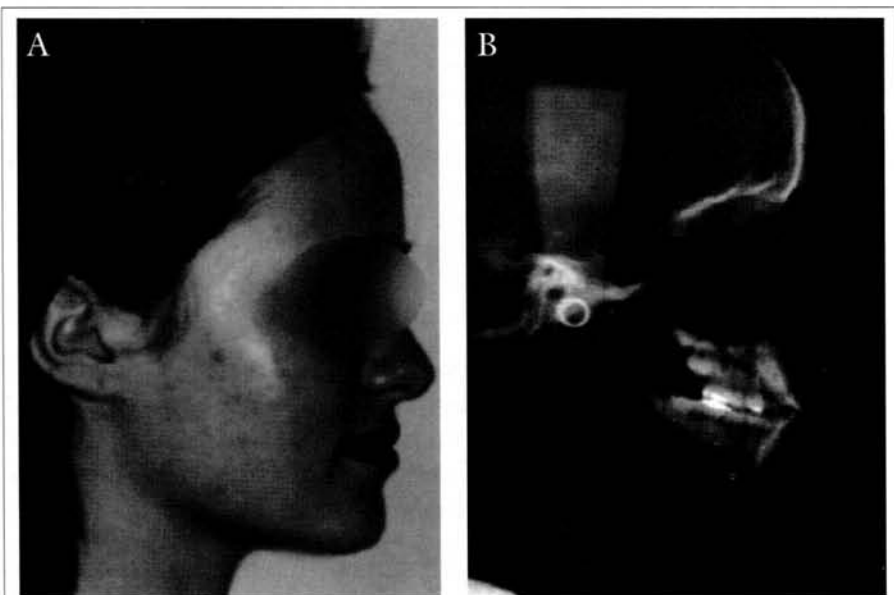
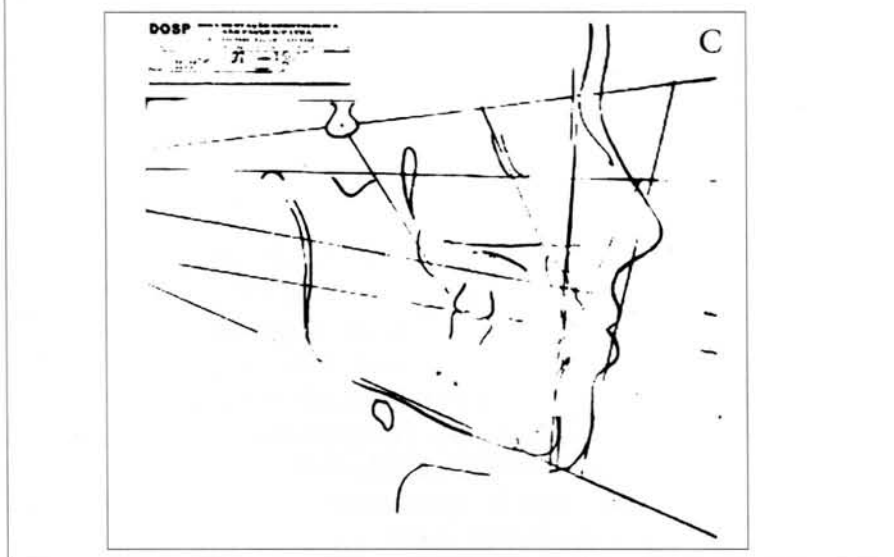


Fig. 3 – In this figure, we may observe the threesome of elements that comprise a cephalometric study to carry out a Profilemetry. A) Profile picture of a female patient; B) Lateral X-ray visualizing the facial outline. C) Points, planes and craniometrical lines identification.

Fig. 3 - Nesta figura podemos ver o trio de elementos que constituem um estudo cefalométrico para a realização de uma Perfilometria. A) Foto de perfil de paciente do sexo feminino; B) Radiografia em projeção lateral com visualização da silhueta facial. C) Identificação de pontos, planos e linhas craniométricas.



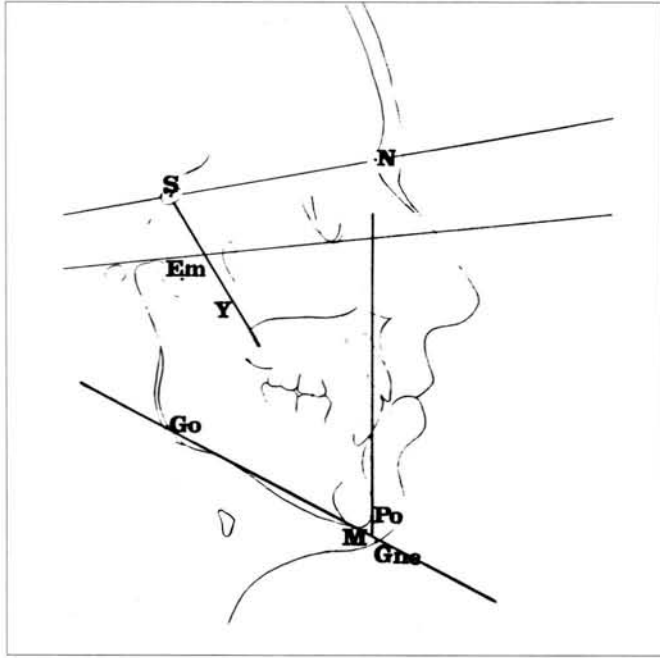


Fig. 4 - Determination of points, planes and craniometrical lines. S: Turcic saddle; N: Nasal; Po: Pogonian; Go: Gonian; M: Mento; Em: Articular prominence; Gnc: Cutaneous gnacio; Y: Growing axis (green line); mandibular plane (red line); Nasal-Pogonian line (blue line); Saddle-Nasal line; Frankfort plane.

Fig. 4 - Determinação de pontos, planos e linhas craniométricas. S: Sela Túrca; N: Nasio; Po: Pogônio; Go: Gônio; M: Mento; Em: Eminência articular; Gnc: Gnacio cutâneo; Y: Eixo de crescimento; plano mandibular; linha Naso-Pogônio; linha Sela-Naso; Plano de Frankfort.

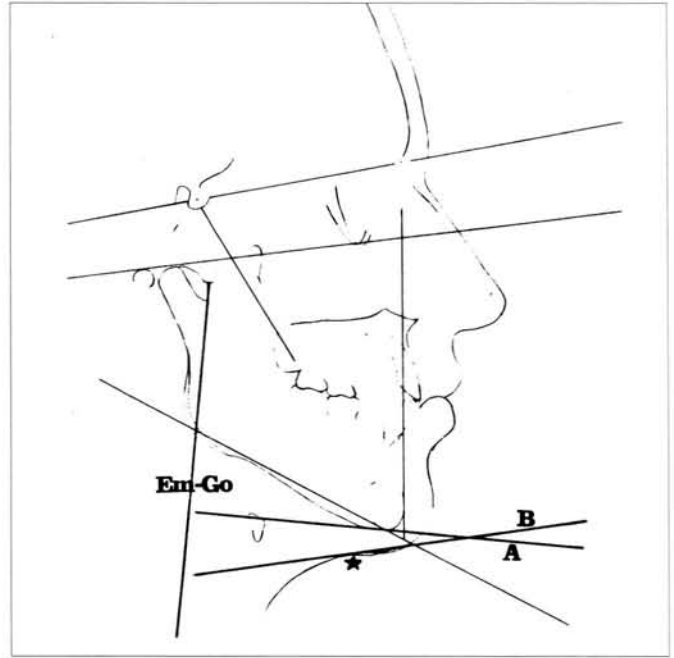


Fig. 5 - Figure showing the obtaining of the cervical-mentonian angle, upon the intersection of lines A and B. We may also observe, in green, the auxiliary line "Em Go", used to trace the perpendicular to "M" point. ★: Internal tangential point.

Fig. 5 - Figura mostrando a obtenção do ângulo Cérvico-Mentoniano mediante a interseção das linhas A e B. Observa-se a linha auxiliar "Em Go", utilizada para traçar a perpendicular ao ponto "M". ★: Ponto tangente interno.

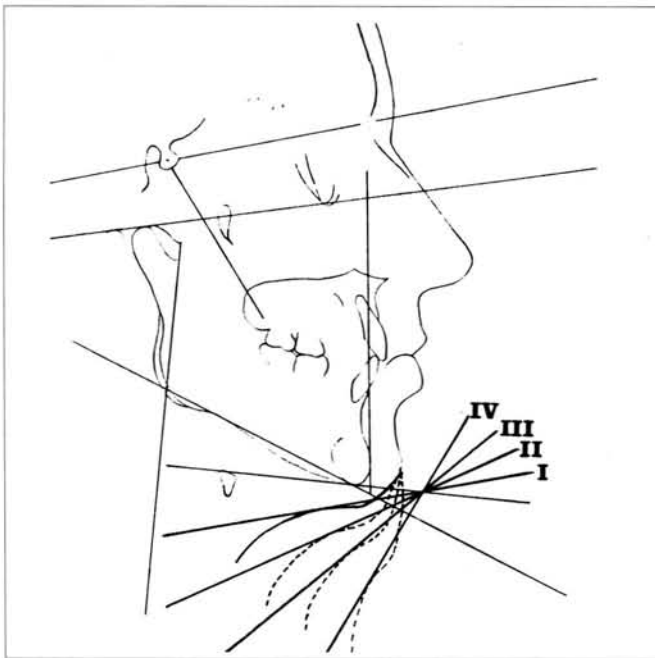


Fig. 6 - Cephalometric study where we observe the overlaid trace of the four Cervical-mentonian angle levels. Degree I: up to 20°, Degree II: 21°-40°, Degree III: 41°-60°, Degree IV: >60°.

Fig. 6 - Estudo cefalométrico em que observamos o traçado em superposição dos quatro níveis de Ângulos Cérvico-Mentonianos. Grau I: até 20°, Grau II: 21°-40°, Grau III: 41°-60°, Grau IV: >60°.

The facial outline correction is a daily challenge for the plastic surgeon, and the treatment of submentonian, submandibular and anterior cervical regions, is a frequent procedure that is part of profileplasty arsenal<sup>(4, 5)</sup>.

Not only the plastic surgeon has the facial aesthetic as an objective. We may observe other specialties, such as Odontology and Maxilo-Facial Surgery<sup>(6)</sup>, that are increasingly focusing their attention to the analysis and treatment of soft tissue areas in order to attain or complete the desired result. In several cases, we observe that the profileplasty aiming at the cervical region is the most simple and correct solution.

Despite being complex, cephalo-profilemetric studies (Figs. 3a, 3b and 3c) are quite important for the achievement of a definite diagnosis<sup>(7)</sup>. The cervical region segment focused in this paper is subject to changes by various factors: age, weight increase, metabolic changes, etc. Anatomically, it consists in well defined structures, in which the skin, fat tissue, superficial muscle aponeurotic system (SMAS) and platysma muscle stand out.

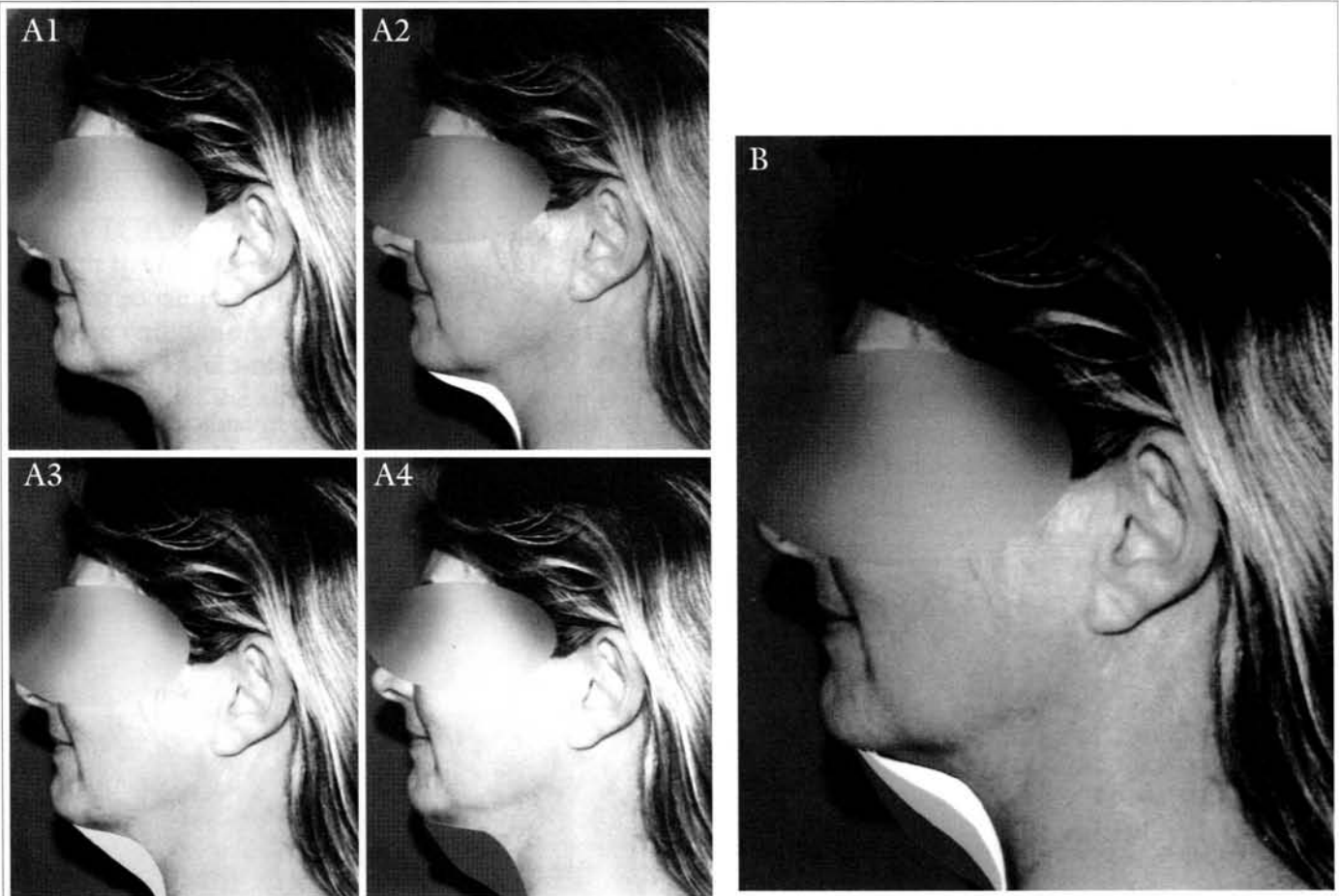


Fig. 7 (A1, A2, A3, A4) - Graphic changes in a female patient where we sequentially observe the four cervical-mentonian angle levels. B: Schematic overlay of the four degrees.

Fig. 7 (A1, A2, A3, A4) - Alterações gráficas em paciente do sexo feminino na qual observamos, em seqüência, os quatro níveis de ângulos cérvico-mentonianos. B: Superposição esquemática dos 4 graus.

Despite a number of papers on profileplasty at the cervical-facial region, the profilemetric study of the cervical region is probably the most overseen. Interventions such as ritidoplasty, liposuction, SMAS and platysma plication, etc. are the procedures most employed for this objective.

This subject is focused in the present paper, gathering a set of new points and coordinates, aiming at providing a new tool for the evaluation and treatment of this surgical regions, always clarifying that the correct diagnosis and the most adequate intervention are directly related with surgeon's common sense<sup>(8)</sup>.

## PATIENTS AND METHOD

A total number of 40 patients, 20 females and 20 males, with ages between 16 and 28 years old (average 19 years old) was evaluated.

Patients were selected according to a cephalometric protocol based on studies of Zide<sup>(9)</sup>, that determined the lack of craniofacial alterations and the presence of harmonious submentonian, submandibular and cervical regions<sup>(10)</sup>. This study was carried out using the standard anthropometrical trace DOSP<sup>(11)</sup>, lateral cranio-encephalic tele-X-rays made by a radiological Yoshida equipment, Pamoura 10-C, with the following specifications: mA=10, Time=0.4-5.0 sec, kV=70-90.

## SISTEMATICS

- a) Anatomical drawing of cranio-encephalic tele-X-ray structures (Fig. 3c).
- b) Points, planes and craniometrical lines (Fig. 4):
  1. Turcic Saddle Point (S).
  2. Nasal Point (N).

3. Pogonian Point (Po).
4. Gonian Point (Go).
5. Mentonian Point (M).
6. Anterior Articular Prominence Point of the Glenoid Cavity (Em).
7. Mandibular plane trace (union of "Go" point with the lower tangential of mentonian symphysis "M").
8. Nasal-Pogonian trace (N-Po), up to the mandibular plane, which determines Gnacio point (Gn).
9. "Y" growing axis, which is the union of point "S" with point "Gn".
10. Cutaneous Gnacio point (Gnc), which is the projection of Gn point at the skin surface, following the growing "Y" axis.
11. Trace of the auxiliary line of the anterior articular prominence point, which is traced from "Em" up to "Go" point (Em-Go) (Fig. 5).
12. Trace of the perpendicular line of the mentonian point (M) to the auxiliary line (Em-Go). Line "A" (Fig. 5).

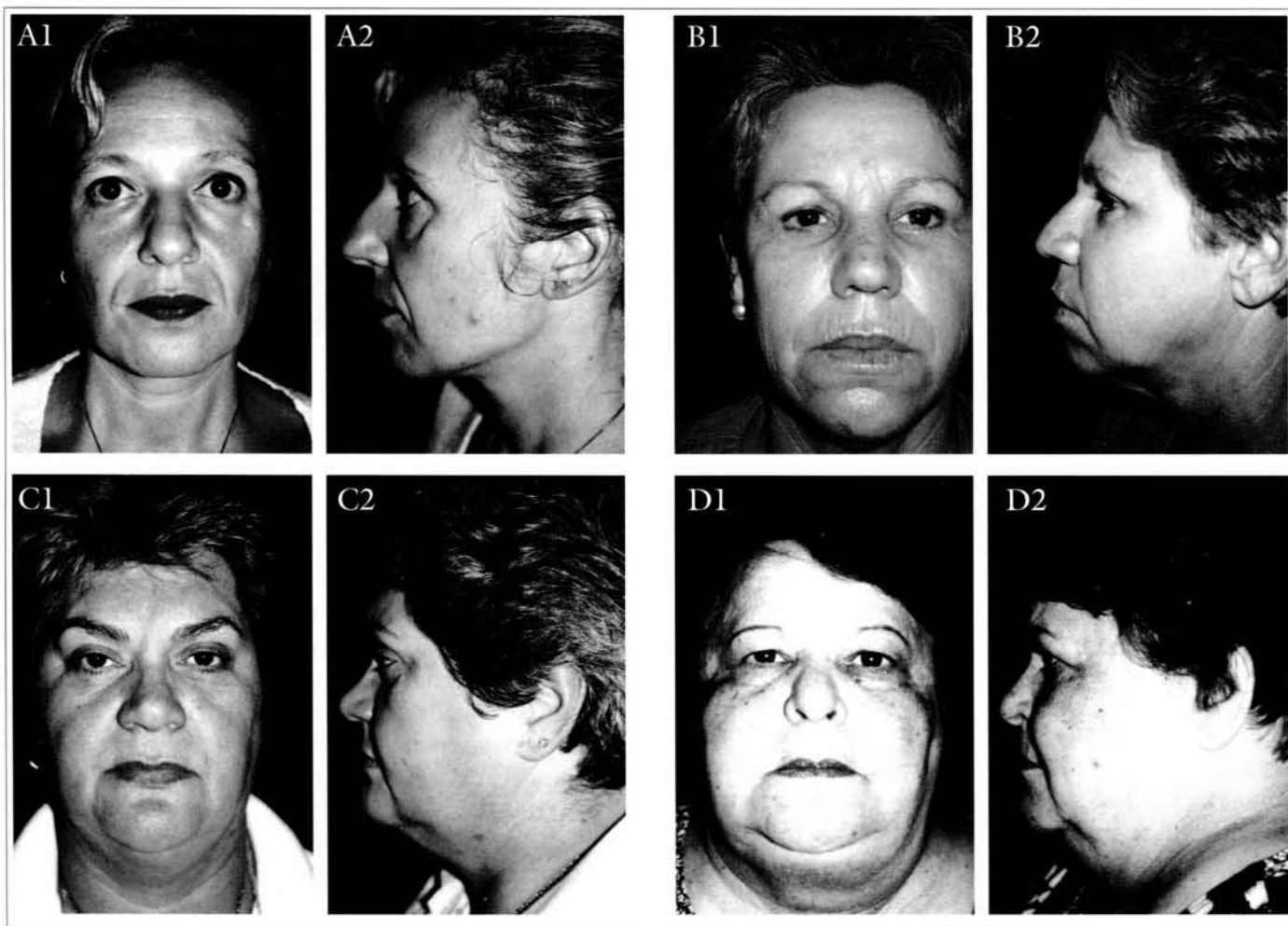

Fig. 8. Group of female patients where we observe examples of various cervical-mentonian angles.

A1, A2) Degree I: Patient presenting 18° of cervical-mentonian angle. B1, B2) Degree II: Patient presenting 36° of cervical-mentonian angle. C1, C2) Degree III: Patient presenting 47° of cervical-mentonian angle. D1, D2) Degree IV: Patient presenting 63° of cervical-mentonian angle.

*Fig. 8. Grupo de pacientes do sexo feminino em que observamos exemplos dos diversos ângulos cérvico-mentonianos.*

*A1, A2) = Grau I: Paciente apresentando 18° de ângulo cérvico-mentoniano. B1, B2) = Grau II: Paciente apresentando 36° de ângulo cérvico-mentoniano. C1, C2) = Grau III: Paciente apresentando 47° de ângulo cérvico-mentoniano. D1, D2) = Grau IV: Paciente apresentando 63° de ângulo cérvico-mentoniano.*

13. Trace of the Cervical-Mentonian line, which unites "Gnc" point with the most internal tangential point of the cervical outline. **LINE "B"** (Fig. 5).

## DETERMINATION OF THE CERVICAL MENTONIAN ANGLE ("DOUBLE CHIN")

Once the points are located and the lines and cephalometric planes are traced, we may proceed to the determination of the angle in focus. It is found at the intersection formed by lines **A** and **B** (Fig. 5).

We may highlight that during the performance of the present study other options to obtain line **A** and the measurement of the angle were analyzed. The mandibular plane was one of them. However, the angle result of the patients evaluated varied a lot, once it depended on the inclination degree of the mandible horizontal branch.

Other alternative considered for this line tracing was the hyoid bone line. This alternative was ruled out because this structure moves during deglutition.

## RESULTS

40 cephalometric studies were analyzed so as to determine the cervical-mentonian angle. The results obtained and patient data are shown in table I.

The study has shown that there are no marked differences when we compare both female and male groups, the results of the evaluation were quite homogenous instead.

The lowest angle found in the female group was 5° and the highest was 19°, with an average of 13.6°. 6° to 18.5°, respectively, were the angles found in the male group, with an average of 13.1°.

When we analyze the group as a whole, we find an average of 13.3° of the cervical-mentonian angle.

The age of our group was not a determining factor for the angle's increase or reduction.

## CLASSIFICATION OF THE CERVICAL-MENTONIAN ANGLE

A classification of the cervical-mentonian angle is pre-

sented below, based on the results obtained in the study (Figs. 6, 7a1, 7a2, 7a3, 7a4 and 7b).

- ◆ Degree I : (Normal) up to 20°.
- ◆ Degree II : 21° to 40°.
- ◆ Degree III : 41° to 60°.
- ◆ Degree IV : more than 60°.

Patient	Gender	Age	C-M Angle
CAC	Fem	18	15°
DTT	Fem	19	17°
AFV	Fem	28	19°
DDF	Masc	20	11,5°
AKS	Masc	22	17,5°
CHF	Masc	18	6°
RAB	Masc	19	9°
CNC	Fem	18	5°
MDT	Fem	28	11,5°
JCF	Masc	26	16°
SIP	Fem	18	16,5°
C.P.P	Fem	18	18,5°
AVE	Masc	19	12°
CML	Masc	18	13,5°
DAM	Fem	16	18,5°
CGF	Fem	18	17,5°
MCM	Fem	17	10°
AMR	Masc	17	18,5°
MCC	Fem	17	8°
APS	Fem	18	6,5°
AMR	Masc	18	14,5°
CAM	Masc	17	13°
MCV	Masc	17	12,5°
HVV	Masc	19	8°
COJ	Masc	20	12°
LMJ	Masc	18	16°
RLL	Masc	19	14,5°
FMB	Fem	18	13°
CRR	Fem	19	10,5°
RLT	Masc	19	13,5°
MHS	Masc	19	15,5°
SAP	Fem	18	15°
SLL	Fem	24	6,5°
HPL	Fem	22	18,5°
MML	Fem	18	18°
JRL	Masc	20	10,5°
CRA	Fem	25	14°
CCA	Masc	18	18,5°
RDA	Fem	21	14,5°
JOS	Masc	18	10°

Data and results of the cervical-mentonian study groups.

## DISCUSSION

**Profilemetry**, begun by Da Vinci, has been being ameliorated by other artists, who observed the need of studying humans proportions. It was noted that the perfection concept was not a convenience or something empirical being imposed; the curves and angles of a body were harmoniously detailed.

Currently, there is no information regarding the study of the cervical-mentonian angle, though there are techniques and tactics to repair it. The limit of beauty, in this anatomical set, has not had yet a scientific base. The performance of the present paper on the cervical-mentonian angle provides the plastic surgeon with the possibility to analyze the variations of this area, grouping patients in various degrees. This is important, specially nowadays, when legal-medical liability imposes us to perform more detailed studies.

The cephalometric orientation of normal cephalo-mentonian angle, with its different classification degrees, will aid in the technical choices and will provide inputs for a better surgical scheduling.

Considering this type of evaluation, the surgeon will have concrete arguments to indicate or not a double chin repair.

## CONCLUSION

The harmony of a face depends on an adequate and proportional balance of the structures that comprises it. Doubtlessly, the region of the neck and its cervical-mentonian angle are essential and fundamental elements in its total evaluation (Fig. 8 a1 up to d2). This segment may suffer significant variations. In this work, we show a contribution to the Profilemetry, to perform Profileplasty, providing, after a series of studies, in addition to its classification, the ideal cervical-mentonian angle variation, which should not exceed 20°.

## REFERENCES

1. HAMBLETON RS. The soft tissue covering of the skeletal face as related to orthodontic problems. *Amer. J. Orthodont.* 1964; 50 (6): 405-20.
2. McCARTHY JG. Introduction to Plastic Surgery. In MCCARTHY. *Plastic Surgery*. Vol. 1. Philadelphia : Saunders, 1990. p. 28-36.
2. ANGLE EH. Malocclusion of the teeth. 7<sup>th</sup> Edition. Philadelphia. SS White Dental Manufacturing Co. 1907.
3. ZANINI SA, SOUZA AM. Perfiloplastias. In: MÉLEGA, ZANINI, PSILLAKIS: *Cirurgia Plástica - Reparadora e Estética*. São Paulo : Medsi, 1992. p. 621-6.
4. PSILLAKIS JM. Perfiloplastias. Anais do XIII Congresso Brasileiro de Cirurgia Plástica. 1984.
5. SERAPHIM L. O perfil mole e sua importância como indicador das deformidades dentofaciais. São Paulo - Faculdade de Saúde Pública, 1973 (Trabalho de mestrado).
6. ZIDE B, GRAYSON B, McCARTHY JG. Cephalometric analysis: Part I. *Plast. Reconstr. Surg.* 1981;68:816.
7. SPIRA M. Malformaciones de la mandíbula y alteraciones de la articulación temporomandibular. In Grabb-Smith: *Cirurgía Plástica*. Barcelona : Salvat, 1984.p.159-187.
8. SPERLI AE. Perfil facial - Avaliação estética. In: ANAIS DO XIII CONGRESSO BRASILEIRO DE CIRURGIA PLÁSTICA, 1984.
9. ZIDE B, GRAYSON B, McCARTHY JG. Cephalometric analysis for upper and lower midface Surgery: Part II. *Plast. Reconstr. Surg.* 1981;68:961.
10. DE PAIVA LA. *Ortodontia Preventiva Básica*. São Paulo : Artes Médicas, 1994. p.142-59.