



Idiopathic scrotal calcinosis: an unusual skin disorder

Calcinose idiopática escrotal: uma inabitual desordem de pele

FERNANDO PASSOS DA-ROCHA^{1*}

MAURÍCIO ANDERSON BRUM¹

PEDRO HENRIQUE ONGARATTO

BARAZZETTI¹

FERNANDA SALIM TESTA DA-ROCHA²

Institution: Universidade Federal de Pelotas, Pelotas, RS, Brazil.

Article received: August 10, 2018.
Article accepted: November 11, 2018.

Conflicts of interest: none.

DOI: 10.5935/2177-1235.2019RBCP0149

■ ABSTRACT

Idiopathic scrotal calcinosis is a rare benign entity. Patients affected by scrotal calcinosis usually do not have other associated symptoms. We report the case of a 30-year-old man with several calcified nodules in the scrotal sac with onset at age 15 years. A complete surgical excision of the nodules was performed, and the patient recovered well with satisfactory aesthetic and functional results.

Keywords: Scrotum; Calcinosis; Epidermal cyst; Reconstructive surgical procedures; Surgical pathology.

■ RESUMO

A calcinose escrotal idiopática é uma entidade rara, benigna. Não costuma ter outros sintomas associados. O caso reportado se trata de um paciente de 30 anos com diversos nódulos calcificados em bolsa escrotal, com 15 anos de evolução. Como medida terapêutica, foi realizada excisão cirúrgica completa dos nódulos, apresentando boa evolução cirúrgica e resultados estético e funcional satisfatórios.

Descritores: Escroto; Calcinose; Cisto epidérmico; Procedimentos cirúrgicos reconstrutivos; Patologia cirúrgica.

¹ Universidade Federal de Pelotas, Departamento de Cirurgia Plástica, Pelotas, RS, Brazil.

² Hospital Ernesto Dornelles, Departamento de Cirurgia Geral, Porto Alegre, RS, Brazil.

INTRODUCTION

Idiopathic scrotal calcinosis (SC) is a rare condition with few cases reported in the literature. It consists of multiple stony calcified nodules on the scrotal skin. It generally affects young men and is not associated with symptoms (pain, edema, flushing etc.) or increase in serum calcium and phosphate levels. Although several hypotheses have been proposed, the pathophysiology of SC has not yet been established¹. Histopathologically, an SC is characterized by the presence of calcium deposits within the dermis surrounded by a foreign-body type granulomatous reaction². Currently, surgical excision is the treatment of choice and provides satisfactory results, despite the lack of knowledge and controversies surrounding the origin of this disease. We describe a case of idiopathic scrotal calcinosis treated at the Plastic Surgery Department of the Medical School of the Federal University of Pelotas-RS.

CASE REPORT

Patient

We report the case of a 30-year-old man with multiple hardened nodules in the scrotum, with slow and painless growth and onset at 15 years of age. (Figure 1). The patient mainly complained of local aesthetics as he had difficulty in maintaining intimate relationships due to the appearance of the lesions. He had no history of metabolic, autoimmune, or neoplastic disease. He did not have any associated symptoms and no history of trauma and/or previous scrotal lesions or any comorbidities.

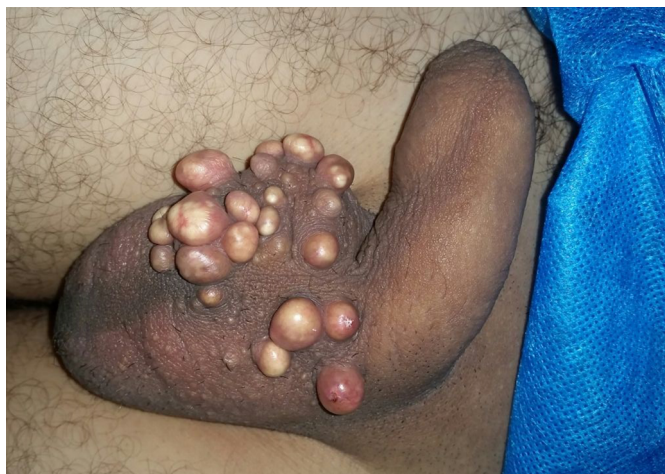

Figure 1. Presence of multiple calcified nodules in the anterior region of the scrotal sac with onset at age 15.

He used skin creams containing clobetasol and betamethasone (not simultaneously) several times, but without any effect. On physical examination, the scrotum

was normal in size and consistency, with several white/yellowish stony nodules of various sizes covered by epithelium.

Serum calcium and phosphorus levels were within normal limits.

Surgical Technique

The surgery was performed under local anesthesia with a thin incision in the plane between the dermis and the dartos muscle. The calcified nodules were not anatomically separate and a single-stage resection was performed along with the surrounding epidermis. The nodules were removed and preserved for pathologic analysis and the wound was closed by approximation of the edges by primary closure using a 3-0 nylon suture.

The patient recovered well after surgery, without any complications. He had satisfactory aesthetic results (Figure 2), without any functional changes.

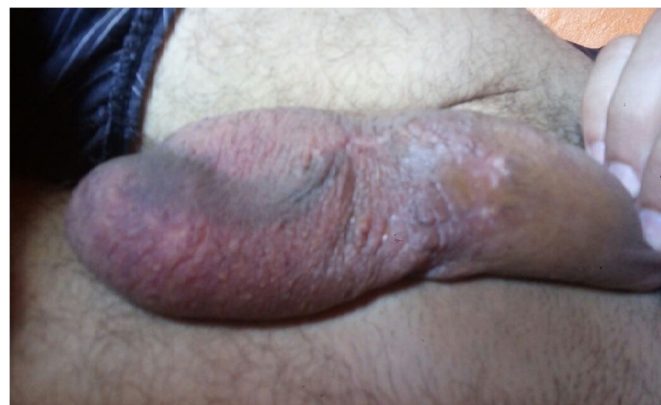

Figure 2. Result of resection with primary closure of the calcified nodules 6 months postoperatively.

DISCUSSION

SC is classified into 3 types: metastatic, dystrophic, and idiopathic. In metastatic SC, serum levels of calcium and phosphorus are increased. In dystrophic SC, the levels of phosphorus and calcium are normal, but local conditions such as inflammation are present that promote calcium deposition. Idiopathic SC is not associated with any laboratory findings or history of trauma. It is a rare condition, and about 200 cases have been described so far³.

Lewinski was the first to describe this condition in 1883. SC is a rare benign condition that causes multiple, asymptomatic, painless nodules on the scrotal skin surface⁴. SC mainly occurs in early adulthood with an insidious onset, without any systemic disturbance of calcium/phosphorus metabolism.

The nodules are typically yellowish-white or dark, consisting of grouped or individual nodules, varying in quantity, and appear as calcium and phosphate deposits

on the scrotal skin. Although the nodules are usually firm and asymptomatic, they may cause itching or pain, and the deposits may extrude through the skin as a white, chalk-like material after an episode of infection of the nodules².

The etiology of SC has been controversial for a long time. The first studies on this subject suggested that SC was caused by a pathogen. However, no cellular elements, lipids or organisms were found within the calcified nodules to justify this theory. Later studies suggested that it originates from the dystrophic calcification of epidermoid cysts⁵.

Recent studies have stated that scrotal calcinosis may result from inflammation of the epidermis, with formation of dermal cysts followed by dystrophic calcification within the nodule, with migration of keratin from the adjacent cyst or dermis to a ruptured cell wall. Other studies, state that epidermal inclusion cysts play an important role in the pathogenesis of the disease⁶.

Recently, Pabuccuoglu et al. reported that degeneration and necrosis of the dartos muscle are the most important factors in the pathogenesis of this disorder. Additionally, it has been suggested that low-impact trauma plays an important role in the etiology of dystrophic calcification³.

Histologically, an SC is characterized by the presence of variable calcium deposits within the dermis, and is commonly surrounded by a granulomatous foreign-body type reaction

Histopathologically, SC is characterized by the presence of calcium deposits of various sizes within the dermis, and usually surrounded by a foreign-body type granulomatous reaction² (Figure 3).

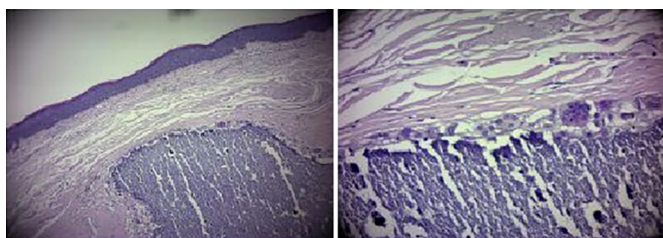


Figure 3. Histopathology of the resected nodule with hematoxylin and eosin stain, showing calcium within the nodule and absence of epithelial lining, which is characteristic of scrotal calcinosis. 10X magnification in image A and 100X magnification in image B.

Calcification of the keratin content is observed in some cysts, with little evidence of active inflammation. These lesions were variously described as sebaceous cysts, calcified steatocystoma, fibroma, atheroma, and xanthoma. Previous studies that reviewed histological data found no evidence of epithelial lining, residual cysts, and lipids and concluded that calcification was idiopathic, introducing the term idiopathic scrotal

calcinosis². Most cases are asymptomatic, and patients usually seek medical advice for aesthetic reasons, as in our case. Total excision is the treatment of choice, and primary closure is almost always possible because the scrotal skin is very flexible.

CONCLUSION

Although other etiologies are suspected, SC is still considered to be idiopathic; thus, further studies should continue investigating the cause for the development of idiopathic scrotal calcinosis. Moreover, good aesthetic results after resection and primary closure are factors that increase the indication for surgery, particularly when performed by an experienced surgeon that applies the concepts of plastic surgery in his/her routine.

COLLABORATIONS

FPR Analysis and/or data interpretation, conception and design study, conceptualization, data curation, final manuscript approval, formal analysis, investigation, methodology, project administration, realization of operations and/or trials, supervision, writing - review & editing.

MAB Analysis and/or data interpretation, conception and design study, conceptualization, data curation, final manuscript approval, investigation, methodology, project administration, realization of operations and/or trials, supervision, visualization, writing - review & editing.

PHOB Analysis and/or data interpretation, conception and design study, conceptualization, data curation, final manuscript approval, investigation, methodology, project administration, realization of operations and/or trials, supervision, visualization, writing - review & editing.

FSTR Analysis and/or data interpretation, conception and design study, conceptualization, data curation, final manuscript approval, investigation, methodology, project administration, realization of operations and/or trials, supervision, visualization, writing - review & editing.

REFERENCES

1. Solanki A, Narang S, Kathpalia R, Goel A. Scrotal calcinosis: pathogenetic link with epidermal cyst. *BMJ Case Rep.* 2015;2015:pil:ber2015211163. DOI: <https://doi.org/10.1136/ber-2015-211163>

2. Parlaktaş BS, Uluocak N, Köseoğlu RD, Erdemir F, Sezer E. Idiopathic scrotal calcinosis: A rare scrotal skin disorder. *J Ankara Univer Fac Med.* 2005;58(1):20-2.
3. Dubey S, Sharma R, Maheshwari V. Scrotal calcinosis: idiopathic or dystrophic? *Dermatol Online J.* 2010;16(2):5.
4. Akosa AB, Gilliland EA, Ali MH, Khoo CT. Idiopathic scrotal calcinosis: a possible aetiology reaffirmed. *Br J Plast Surg.* 1989;42(3):324-7. PMID: 2667677 DOI: [https://doi.org/10.1016/0007-1226\(89\)90155-0](https://doi.org/10.1016/0007-1226(89)90155-0)
5. Shah V, Shet T. Scrotal calcinosis results from calcification of cysts derived from hair follicles: a series of 20 cases evaluating the spectrum of changes resulting in scrotal calcinosis. *Am J Dermatopathol.* 2007;29(2):172-5. DOI: <https://doi.org/10.1097/01.dad.0000246465.25986.68>
6. Khallouk A, Yazami OE, Mellas S, Tazi MF, El Fassi J, Farih MH. Idiopathic scrotal calcinosis: a non-elucidated pathogenesis and its surgical treatment. *Rev Urol.* 2011;13(2):95-7.

***Corresponding author:**

Fernando Passos da Rocha

Praça Piratinino de Almeida, 13, Centro, Pelotas, Rio Grande do Sul, Brazil.

Zip Code 96015-360

E-mail: fprocha.sul@terra.com.br