

Facial Rejuvenation with CO₂ Laser — A Study of 200 Patients

Ruth Maria Graf, MD¹
Afrânio Bernardes, MD²
André Auerswald, MD²
Luiz Roberto de Araújo, MD³
Lúcia Noronha, MD⁴

- 1] Titular Member of the Brazilian Society of Plastic Surgery, Member of the Scientific Committee of the Brazilian Society of Plastic Surgery, Section of Paraná, Guest Professor of the Evangelic University of Curitiba.
- 2] Associate Member of the Brazilian Society of Plastic Surgery.
- 3] Resident, Plastic Surgery, Evangelic University of Curitiba.
- 4] Pathologist, Member of the Brazilian Society of Pathology.

Address for Correspondence:

Ruth Graf, MD

R. Solimões, 1184
80810-070 - Curitiba - Paraná
Brazil

Phone: (55 41) 335-7237 - Fax: (55 41) 335-9394
e-mail: hansgraf@bsi.com.br

Keywords: laser; resurfacing; facial rejuvenation.

ABSTRACT

CO₂ laser Ultrapulse (Coherent Inc.) was used in 200 patients, from March 1996 to December 1997. In 180 patients (90%) full face laser resurfacing was done, and in 87 patients (48,3%) this procedure was associated with face lifting surgery. On the remaining 20 patients, CO₂ laser was applied on other body areas, as dorsal hands, and for excision of warts and nevi.

All patients submitted to laser resurfacing were previously treated during 1 to 2 months with retinoic acid and hydroquinone. The procedures were done under local anesthesia supervised by an anesthesiologist. A clear film dressing impregnated with silicone gel (Silon TSR, Bio-Med Sciences, Bethlehem, PA, USA) was used for 6 to 7 days and complete healing was observed in 7 to 10 days. Complications were exclusively dermatological, without relation to surgery.

Ten consecutive patients have undergone skin biopsies for the study of the histological effects of the laser. Personal satisfaction, evaluated after 6 months to one year was excellent in 58%, good in 30%, regular in 10% and poor in 2%. In the last one, severe acne scars were observed, with indication to repeat the treatment.

INTRODUCTION

In the last years, many authors have been studying the applications of CO₂ laser, which led to a worldwide divulgation of this technology (3, 4, 10, 11, 13, 15).

The continuous evolution of the CO₂ laser technology — Computer Pattern Generator Scanner (CPG) — facilitated its use for procedures in the whole face^(1, 2, 12).

With the successful use of CO₂ laser in association with some minimal procedures of face surgery like superior blepharoplasty, inferior transconjunctival blepharoplasty and endoscopic browlift, we have begun to use CO₂ laser together with cervicofacial rhytidoplasty, even over the cutaneous flap. The flap is subcutaneously undermined and the residual thermal coagulation effect of the CO₂ laser reaches the dermis. The subdermal vascularization of the flap remains intact⁽⁹⁾.

MATERIAL & METHODS

From March 1996 to December 1997, 200 laser resurfacing procedures were performed. We used CO₂ laser Ultrapulse (Coherent, Inc., Palo Alto, CA). 190 patients were female and 10 were male. Patient's age ranged from 15 to 70 years old, predominating the patients aging 40-49 years (30%) and 50-59 (29%).

Patients were previously prepared. The treatment began 1 month before the resurfacing in patients with fair skin types (Fitzpatrick classification I and II) to two months in patients with darker skin types (Fitzpatrick classification III to V). The preparation consisted in using retinoic acid 0.025%, hydroquinone (2 to 4%) sunscreen SPF 25.

Every patient received acyclovir and antibiotics (cephalosporin) 48 hours before the procedure, which were maintained for 7 days after the laser procedures, as preconized by many authors⁽⁶⁾.

Patients who had full facial resurfacing received 4 mg of intravenous dexamethasone (Decadron) during the surgery and after that, the antibiotic was administered orally for 2 days.

The procedures were done under local anesthesia and sedation was controlled by an anesthesiologist. After antiseptis, all wrinkles and deep sulcus were marked with blue methylene. Anesthetic nerve blocks were performed (supra and infra-orbital, nasociliar, mentonian, maxillary at their origin and cutaneous branches of cervical plexus), and were complemented with local anesthesia where nerve blocks do not work. We used lidocaine 2% for the nerve block and lidocaine 2% associated with Marcaine 0.5% in epinephrine solution 1:400000. Tetracaine eyedrops were also used. During the laser resurfacing and the laser blepharoplasty the globe was protected using an eyeshield.

Full face laser resurfacing was done in 78 patients alone or associated with surgical procedures as: superior blepharoplasty, inferior transconjunctival blepharoplasty, canthopexy and facial lipoinjection. In 87 patients, the laser was associated with rhytidectomy at the same surgical time. In these cases, the rhytidectomy was done undermining the cutaneous flap associated with SMAS-platysma flap. Laser resurfacing was also applied over the neck with less energy and in one pass only. In 15 patients, laser was regional, mainly perioral and periorbital, and 20 patients had other pathologies treated, like nevi, warts, etc.

Laser Resurfacing - 180 Patients
March '96 - December '97

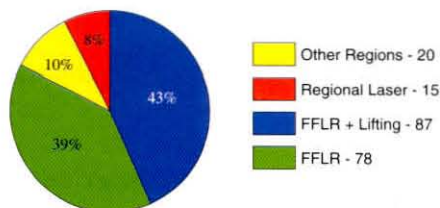


Fig. 1 - Patient's distribution according to the technique employed.

Fig. 1 - Distribuição dos pacientes de acordo com a técnica utilizada.

Laser — March '96 - December '97
200 Patients

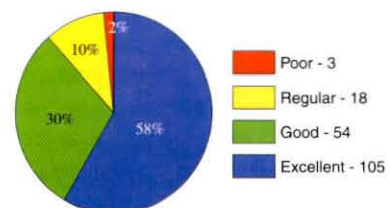


Fig. 2 - Personal satisfaction of patients submitted to laser resurfacing.

Fig. 2 - Índice de satisfação pessoal dos pacientes submetidos a laser de face.

All surgical procedures were done before resurfacing. The treatment started with laser on the wrinkle margins previously marked ("shoulders") with 500 mJ, 10 W, ultrapulse and CPG off. Then, the treated area was cleaned with saline solution, to remove the vaporized epidermis. After that, we did 2 passes with 300 mJ, 60 W, CPG 396 on nasal and frontal areas, lips and cheeks; 2 passes with 175 mJ, 30 W, CPG 366 on the eyelids. On the neck and undermined skin flap we used 175 mJ, 30 W, CPG 396, one pass. The area was cleaned after each pass.

All laser-treated areas were covered with a clear film dressing impregnated with silicone gel (Silon TSR, Bio-Med Sciences, Bethlehem, PA, USA) and changed whenever necessary, mostly on the third postoperative day and kept until the 7th or 8th postoperative day. On exposed areas, where Silon could not protect, as perioral or lower neck, vaseline was daily used.

After this time, patients used neutral hydrating creams, hydrocortisone creams for itching and erythema and sunscreen for sunlight protection and social exposure. In the first month, the skin was more sensitive and erythematous, followed by a hyperpigmentation that must be prevented and/or treated. For this reason clarifying topical treatment should begin in the first postoperative month. After 1 month, glycolic acid 8% and hydroquinone 2 to 4% was applied until the hyperpigmentation diminished. Association with kojic acid was done when necessary.

Patients were advised to avoid sun exposure for 3 to 4 months.

Biopsies were done in the upper eyelids and in the preauricular region in 10 consecutive patients for histological study.

On the upper eyelids we used 175 mJ, 30 W, CPG 366, 2 passes and on the preauricular region, 300 mJ, 60 W, CPG 396, 2 passes. We used these same parameters of the laser for all biopsies.

RESULTS

Figure 1 shows that among 200 patients, 78 (39%) were submitted to full face laser resurfacing (FFLR) associated to surgical procedures like blepharoplasty, canthopexy and endoscopic brow lift, face lipoinjection, rhinoplasty, etc; 87 patients (43%) had rhytidectomy with FFLR, also including the procedures above; 15 patients (8%) had regional laser re-

surfacing, mostly perioral and periorbital; and in 20 cases (10%) laser treatment was done over different areas like back of the hands, and also in nevi and warts of the face and in other areas of the body.

Table I shows each procedure done at the same surgical time as the laser. Out of 180 patients, 165 were submitted to FFLR and 15 were submitted to regional facial laser.

FACIAL CO ₂ LASER	
Associated procedures - 180 patients	
FULL FACE LASER RESURFACING	165 patients
Full face laser	78 patients
Superior blepharoplasty	55 patients
Inferior transconj. blepharoplasty	50 patients
Canthopexy	33 patients
Facial lipoinjection	50 patients
Endoscopic brow lift	10 patients
Full Face Laser+rhytidectomy with SMAS	87 patients
Superior blepharoplasty	75 patients
Inferior transconj. blepharoplasty	70 patients
Canthopexy	80 patients
Facial lipoinjection	66 patients
Endoscopic brow lift	08 patients
REGIONAL LASER	15 patients
TOTAL	180 patients

Table I

The surgical procedures were done isolated or in association with superior blepharoplasty plus lipoinjection or superior blepharoplasty plus inferior transconjunctival blepharoplasty, etc. Canthopexy with Flower's technique⁽⁵⁾ was mostly performed in association with face and neck lift because these patients were older than those submitted to laser only. When a light level of inferior eyelid flaccidity is present (positive SNAP test) it is an indication, from our point of view, of prophylactic or therapeutic canthopexy.

Figure 2 shows the personal satisfaction rate in 180 patients. It shows that in 105 patients (58%) the re-

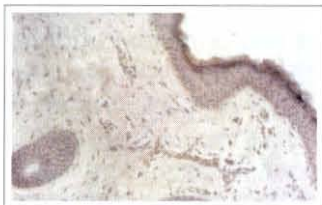


Fig. 3 - Eyelid skin histology with minimal collagen basophilic degeneration, in the papillary dermis. Applied 175 mJ, 2 passes.

Fig. 3 - Corte histológico de pele de pálpebra com área de degeneração basofílica do colágeno, mínima, localizada na derme papilar. Aplicado 175mJ, 2 passadas.

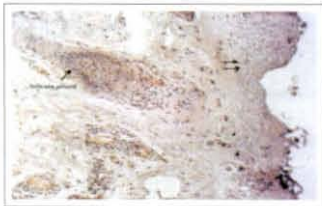


Fig. 4 - Eyelid skin histology after CO₂ laser with complete coagulation of the degenerated basophilic collagen area. The coagulation area extends until the papillary dermis/reticular dermis transition (double arrow).

Fig. 4 - Corte histológico de pele palpebral após aplicação do laser, com coagulação completa da área de degeneração basofílica do colágeno. A área de coagulação se estende até a transição derme papilar e derme reticular (seta dupla).

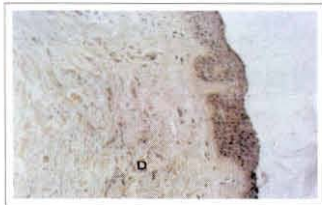

Fig. 5 - Preauricular skin histology with minimal collagen basophilic degeneration down to the papillary dermis/reticular dermis transition. Applied 300 mJ, 2 passes.

Fig. 5 - Corte histológico de pele de região pré-auricular, com mínima degeneração basofílica do colágeno até a transição derme papilar/derme reticular. Aplicado 300mJ, 2 passadas.



Fig. 6 - Preauricular skin histology after CO₂ laser application, with complete coagulation of the collagen basophilic degeneration area. The coagulation area extends to the superficial reticular dermis (double arrow).

Fig. 6 - Corte histológico de pele pré-auricular após aplicação do laser, com coagulação completa da área de degeneração basofílica do colágeno. A área de coagulação atinge até a derme reticular superficial (seta dupla).

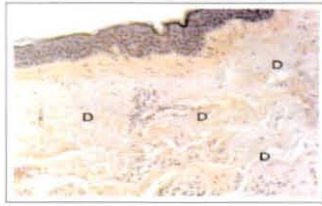


Fig. 7 - Preauricular skin histology with intense collagen basophilic degeneration (D), extending until the deep reticular dermis; applied 300 mJ, 2 passes.

Fig. 7 - Corte histológico de pele de região pré-auricular com acentuada degeneração basofílica do colágeno (D), atingindo até a derme reticular profunda. Aplicado 300mJ, 2 passadas.

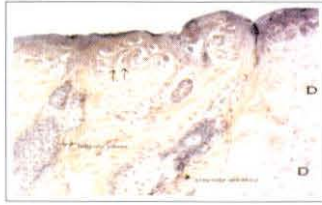

Fig. 8 - Preauricular skin histology after CO₂ laser application, with coagulation of only a part of the collagen basophilic degeneration. This area goes down to the superficial reticular dermis (double arrow), but the collagen actinic lesion area is deeper (D).

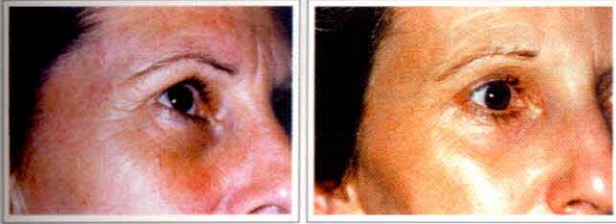Fig. 8 - Corte histológico de pele pré-auricular após aplicação do laser, com coagulação de apenas uma parte da área de degeneração basofílica do colágeno. A área atingida pelo laser vai até a derme reticular superficial (seta dupla), porém a área de lesão actínica do colágeno é mais profunda (D).

sults were beyond expectation, being these patients extremely glad with surgical outcome 6 months after the surgery. These cases were associated with face and neck lift or endoscopic browlift or other procedures; 54 patients (34%) had good results, with complaints of some wrinkles reappearance (expression wrinkles), treated later with botulinum toxin⁽⁷⁾. In 18 patients (10%) the results were considered regular, due to post-operative complications, return of some wrinkles, persistent localized hyperchromy and reappearance of some acne scars; 3 patients (2%) with severe acne scars considered their results poor and another lasertherapy was indicated.

Studies have been done to define the CO₂ laser histological action over the skin⁽¹⁴⁾

Biopsies were done in 10 patients, in two specific areas: superior eyelids and preauricular area. We used in all this patients the same laser parameters.

On the eyelids where there was minimal collagen basophilic degeneration in papillary dermis, right after the treatment (175 mJ, 30 W, CPG 366, 2 passes) a complete coagulation occurred until the transition level between papillary and reticular dermis, completely vanishing photoaging of this area (figs. 3 and 4).



Figs. 9 & 10 - Female patient, 48 years, with glabella and eyelid wrinkles (left). Same patient, 1 year after FFLR associated with endoscopic brow lifting, superior blepharoplasty and canthopexy (right).

Figs. 9 e 10 - Paciente com 48 anos, sexo feminino, apresentando rugas palpebrais e glabellares (esquerda). Mesma paciente, um ano após laser total de face associado a cirurgia endoscópica frontal, blefaroplastia superior e cantopexia (direita).



Figs. 11 & 12 - Female patient, 72 year, with full face flaccidity (left). Same patient, 1 year after FFLR associated with face and neck lifting, SMAS-platysma, superior blepharoplasty, inferior transconjunctival blepharoplasty, canthopexy and lipoinjection of the nasal sulcus (right).

Figs. 11 e 12 - Paciente com 72 anos, sexo feminino, apresentando flacidez pan-facial (esquerda). Mesma paciente, um ano após laser total de face associado a ritidoplastia cérvico-facial, SMAS-platysma, blefaroplastia superior, inferior transconjuntival, cantopexia e lipoenxertia de sulco nasogeniano (direita).

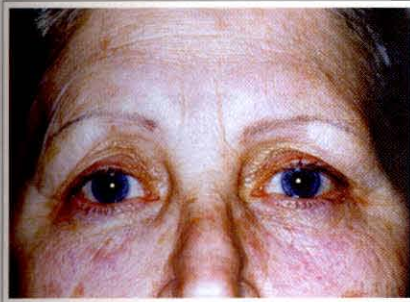

Fig. 13 - Same patient of fig. 11, close up of the eyelids.

Fig. 13 - Mesma paciente da fig. 11 com close das pálpebras.

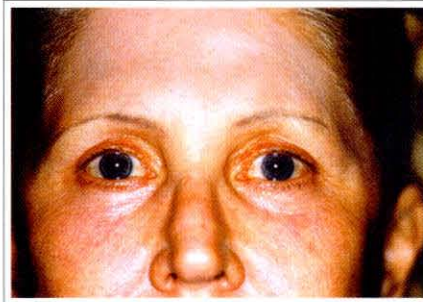

Fig. 14 - Same patient, 1 year after the treatment.

Fig. 14 - Mesma paciente, 1 ano após o tratamento.

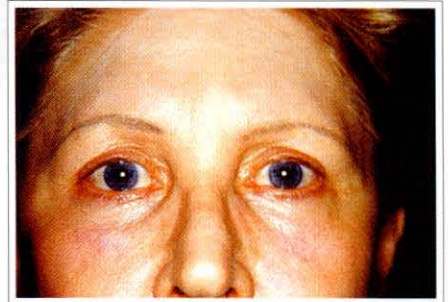

Fig. 15 - Same patient, 1 year and 10 months after the treatment.

Fig. 15 - Mesma paciente, 1 ano e 10 meses após o tratamento.

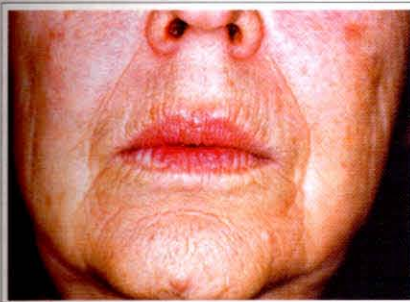

Fig. 16 - Patient of fig. 11, close up of perioral region.

Fig. 16 - Paciente da fig. 11 com close da região perioral.

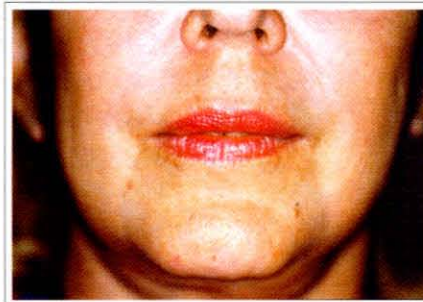

Fig. 17 - Same patient, 1 year after treatment, showing improvement of the facial flaccidity and perioral wrinkles.

Fig. 17 - Mesma paciente, 1 ano após o tratamento; observa-se redução da flacidez facial e das rugas periorais.

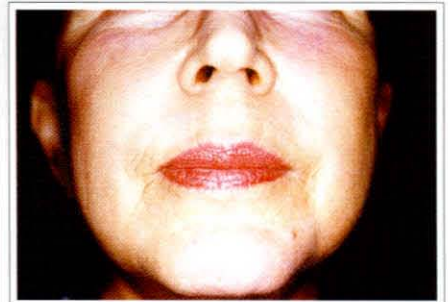

Fig. 18 - Same patient with maintained result, 1 year and 10 months after the treatment.

Fig. 18 - Manutenção do resultado, 1 ano e 10 meses após o tratamento.

Histology of preauricular area where collagen basophilic degeneration was shown down to the transition papillary/superficial reticular dermis, which means Fitzpatrick I and II or a previously well prepared skin, after 2 passes using 300 mJ, 60 W, CPG 396, there

was complete coagulation of collagen basophilic degeneration until superficial reticular dermis (figs. 5 and 6).

In cases where skin presented a collagen basophilic

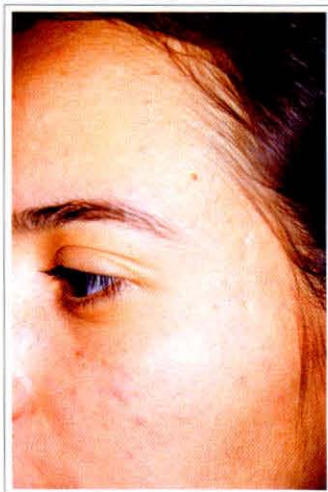

Fig. 19 - Female patient, 17 years, presenting acne scars.

Fig. 19 - Paciente com 17 anos, sexo feminino, com seqüela de acne.

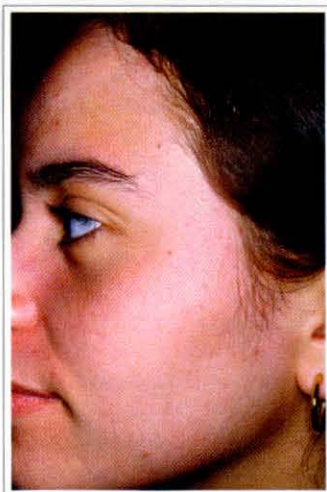


Fig. 20 - Same patient, 1 year later, after FFLR.

Fig. 20 - Mesma paciente, 1 ano após laser total de face.

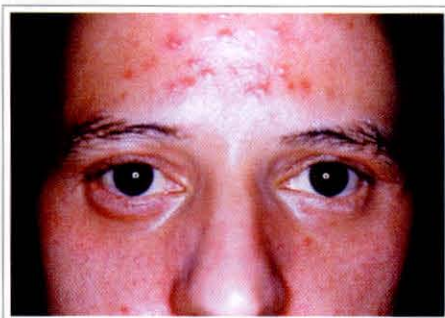

Fig. 21 - Complication after CO₂ laser. Patient 10 days PO, presenting local bacterial infection in the frontal region.

Fig. 21 - Complicação pós-laser CO₂. Paciente no 10º dia, apresentando infecção bacteriana localizada em região frontal.

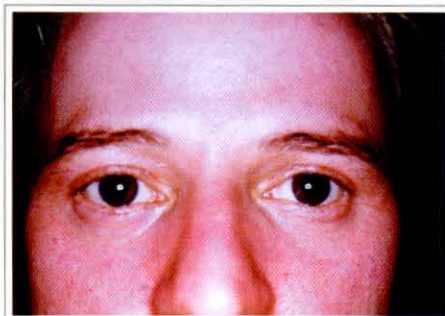

Fig. 22 - Same patient, 21 days after CO₂ laser, with total improvement of the lesions without sequelae.

Fig. 22 - Mesma paciente, no 21º dia pós-laser, com melhora de lesões, sem apresentar seqüelas.

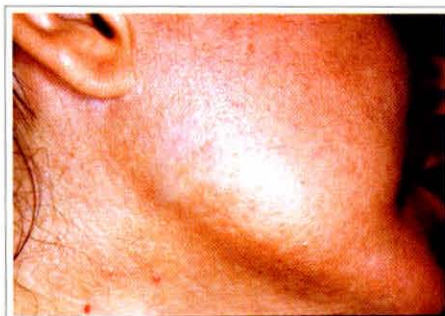

Fig. 23 - Patient with hyper and hypopigmentation on the mandibular area, 4 months after CO₂ laser.

Fig. 23 - Paciente apresentando faixa de hiper e hipocromia em região mandibular; 4 meses após laser de CO₂.

degeneration down to the deep reticular dermis; that is, severe photoaging, skin inadequately prepared or Fitzpatrick III to V, using the same parameters, baso-

philic degeneration was not completely treated. Only the superficial reticular dermis was reached, so that collagen basophilic degeneration still lasted (figs. 7 and 8).

DISCUSSION

We consider laser resurfacing an excellent method for facial rejuvenation. A good result depends on the right indication and adequate management.

The surgeon should always keep a good relationship with the patient, providing every possible explanations on the preoperative period, and all necessary team attention on the first postoperative month, when the patient is very vulnerable psychologically due to the aesthetic aspects. That is why the attentions must be reinforced.

We advise full face laser resurfacing (82%) for most patients rather than regional laser resurfacing (8%), in order to facilitate the postoperative clarifying treatment.

Undoubtedly, CO₂ laser⁽¹⁴⁾ presents great effect on elastic fiber and collagen at the reticular dermis level, offering good results in deep wrinkles.

In our histological studies we observed that the patients with Fitzpatrick skin type I and II did not present deep collagen basophilic degeneration and that treatment parameters were enough to obtain the total vanishing of the photoaged skin with CO₂ laser treatment. Patients with Fitzpatrick skin type III to V, who presented deep collagen basophilic degeneration, the usual parameters were not enough to completely eliminate the photoaged skin with CO₂ laser.

The collagen basophilic degeneration suffers complete coagulation down to the transition of papillary/reticular dermis on the eyelids and down to the superficial reticular dermis on the preauricular area, that is the coagulation process doesn't reach the appendage layer in the deep reticular dermis, completely vanishing the photoaged skin from the treated areas as far as the parameters above are observed.

The biopsy parameters observed show us that with 175 mJ the coagulation process reached the transition papillary dermis/superficial reticular dermis. With 300 mJ the coagulation process reached the superficial reticular dermis, without damaging the deep reticular dermis appendages.

We can conclude that in patients with higher degree of photoaged skin, we can go deeper with the laser or we must prepare their patients' skin for longer during the preoperative period so that best results are obtained.

It was also noticed that FFLR associated with other procedures as blepharoplasty, canthopexy, endoscopic browlift, face and neck lift, lipoinjections, lead to better results and personal satisfaction if compared to isolated or regional use of laser (figs. 9 to 20).

We had as complications 2 cases of localized bacterial infections treated with topic therapy (figs. 21 and 22); one case of fungic infection treated with fluconazole (100 mg, for 7 days) associated with topic therapy and 8 cases of contact dermatitis in the first postoperative month related to hypersensitivity to the chemical agent, or hydroquinone allergy, solved by changing active cream agents. The erythema disappeared in all cases in 3 or less months and hyperchromy was treated with clarifying creams for 3 to 5 months. There were no cases of intense hypochromy and clarifying creams were suspended as soon as the skin reached a natural color, because prolonged utilization can lead to unrecoverable hypochromy. Some patients presented strips of hyper and hypopigmentation on the mandibular area of difficult treatment (fig. 23).

All patients were previously treated with acyclovir and antibiotics (Cephalosporin) 48 hours before and 7 days after the procedure, to reduce complications like herpes and bacterial infections.

Before beginning practicing with CO₂ laser for facial rejuvenation, a plastic surgeon needs a good training period with laser experient teams. After that, a good patient selection is fundamental, starting with Fitzpatrick I to III, and also with no traces of psychological disturbs. In the first postoperative week all team attentions are necessary until the first and second postoperative month. The surgeon in charge of the patient should keep a close follow up of the dermatological reactions, changing products as needed.

REFERENCES

1. APFELBERG, DB. Ultrapulse Carbon Dioxide Laser with CPG Scanner for Full-Face Resurfacing for Rhytids, Photoaging and Acne Scars. *Plast. Reconstr. Surg.* 1997; 99(7):1817-25.
2. ALSTER, TS: Treatment of Facial Rhytides with a

High-Energy Pulsed Carbon Dioxide laser; *Plast. Reconstr. Surg.* 1996; 98(5):791-4.

3. FITZPATRICK, RE et al. The Depth of Thermal Necrosis Using the CO₂ laser. A Comparison of the Superpulsed Mode and Conventional Mode. *J. Dermatol. Surg. Oncol.* 1991; 17:340-9.
4. _____. Depth of Vaporization and Residual Thermal Damage Using Multiple Passes of the Ultrapulse CO₂ laser, lasers. *Surg. Med.* 1997;21(9):31-8.
5. FLOWERS, RS. Canthopexy with Aesthetic Blepharoplasty. In: ANNUAL MEETING OF THE AMERICAN SOCIETY FOR AESTHETIC PLASTIC SURGEONS, 1983.
6. HOEFFLIN, SM. Preoperative and Postoperative Care for laser Resurfacing Patients. *Aesthetic Surg.* 1996; 16(4):232-4.
7. MATSUDO, PK. Botulinum Toxin for Correction of Fronto-glabella Wrinkles: Preliminary Evaluation. *Aesth. Plast. Surg.* 1996; 20:439-441.
8. MC DANIEL, DH et al. The Erbium Yag Laser: A Review and Preliminary Report on Resurfacing of the Face, Neck and Hands. *Aesth. Surg.* 1997; 17(3):157-64.
9. NATHAN, M, FELDER, DS. CO₂ laser Resurfacing over Facial Flaps. *Aesth. Surg.* 1997; 17(5):285-92.
10. ROBERTS III, TL et al. CO₂ Laser Resurfacing: Recognizing and Minimizing Complications. *Aesth. Surg.* 1996; 16(2):142-8.
11. _____. Aesthetic CO₂ Laser Surgery: Evaluation of 907 Patients. *Aesth. Surg.* 1997; 17(5):293-303.
12. RONCATI, C and TUNDISI, M. "Resurfacing" com o Ultrapulse-Laser; Nova Arma no Rejuvenescimento Facial; *Rev. Bras. Cir. Plast.* 1996; 11(2):69-73.
13. ROSEMBERG, GJ et al. Treatment of Post Laser Resurfacing Complications - Panel Discussion. *Aesth. Surg.* 1997; 17(2):119-23.
14. STUZIN, JM. et al.: Histological Effects of the High-energy Pulsed CO₂ Laser on Photoaged Facial Skin. *Plast. Reconstr. Surg.* 1997; 99(7):2036-50.
15. WEINSTEIN, C and RAMIREZ, O. Complications of Carbon Dioxide Laser Resurfacing and the Prevention. *Aesth. Surg.* 1997; 17(4):216-25.