

# Microsurgical Reimplantation of Total Scalp Avulsion — Case Report

Carlos Augusto Cameschi, MD<sup>1</sup>  
Oswaldo Miura, MD<sup>2</sup>

- 1] Associate Member of the SBCP.  
Chief of the Plastic Surgery Department of Associação Hospitalar de Bauru - Brazil.
- 2] Titular Member of the SBCP.  
Titular Member of the Brazilian Society of Reconstructive Microsurgery.  
Medical chief of Centro Brasileiro de Cirurgia Plástica and Clínica Dandreira e Miura (Plastic Surgery Residency Program).

**Address for Correspondence:**

**Clínica de Cirurgia Plástica Dr. Carlos Augusto Cameschi**

R. Capitão Gomes Duarte 10-5  
Altos da Cidade - Bauru - SP  
17040-020

Phone: (55 14) 234-5550

**Keywords:** microsurgery; total scalp; microsurgical reimplantation.

---

## **ABSTRACT**

*A 25 year-old woman, victim of a total avulsion of the scalp including a large portion of the forehead, when the rotative machine caught her hair.*

*Successful reimplantation was carried out using microsurgery.*

*Reimplantation should be attempted in all scalp avulsions.*

## **INTRODUCTION**

In our society, where agricultural activities are predominant, the mechanization process came up with new kinds of accidents, moreover those caused by the rotative axes of plows.

When the axes used in agricultural equipment catch plowmen clothes or long hair they cut off certain body segments.

The mechanism of avulsion of the scalp in accidents caused by plows generally occurs in the subgalea region. In the total avulsion, many other structures may be evolved like the cutaneous portion of the face, eyelids and ears. In these regions, the frontal and occipital muscles present less resistance than the galea.

The resulting sequelae from the total avulsion of the

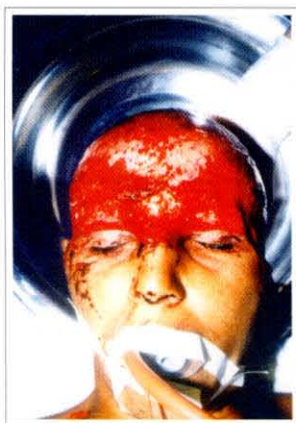


Fig. 1 - Preoperative frontal view 2 hours after the trauma.

Fig. 1 - Pré-operatório (vista anterior da paciente 2 horas após o trauma).

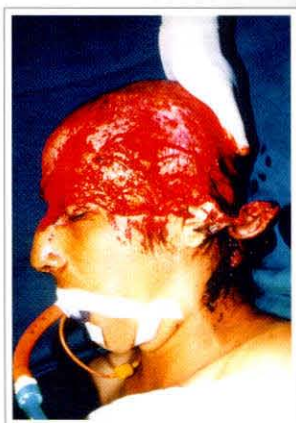

Fig. 2 - Preoperative profile view showing laceration of the left ear.

Fig. 2 - Pré-operatório (vista lateral esquerda mostrando a laceração da orelha esquerda).

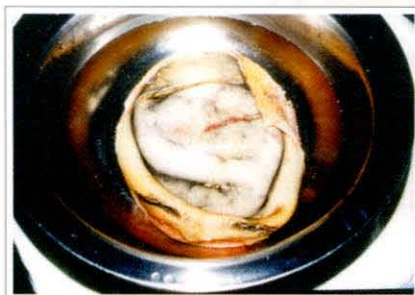

Fig. 3 - Preoperative view of the avulsed segment in saline solution after trichotomy and cleaning.

Fig. 3 - Pré-operatório (seguimento avulsionado, em solução salina após tricotomia e limpeza dos corpos estranhos).

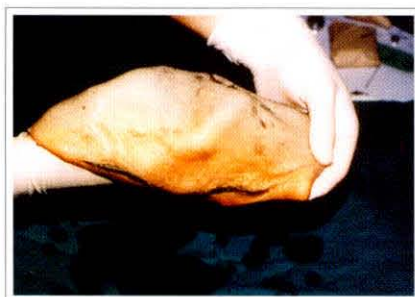

Fig. 4 - Preoperative frontal view of the avulsed segment where the eyebrows can be visualized.

Fig. 4 - Pré-operatório (seguimento avulsionado em posição anterior onde se visualizam as sobrancelhas).

scalp with exposure of the skull are very difficult to reconstruct and generally cause irreparable aesthetic deformities. It is known that in such case a microsurgical reimplantation is the best choice of treatment<sup>(1, 2, 3, 4, 5)</sup>.

The first reimplantation of the scalp was performed in 1974 and published in 1976 by Miller et cols<sup>(2)</sup>.

## CASE REPORT

Patient CGQ, 25 years old, female, white, single,

plowman, evangelical, entered the emergency room of Hospital de Base de Bauru (Bauru, SP, Brazil) two hours after the trauma, on October 28, 1990.

The rotative axis of a farm tractor caught the patient's hair, which led to the total avulsion of the scalp.

It was possible to observe a portion of the frontal region of the face, the eyebrows and part of the upper eyelids in the amputated segment, which was washed with saline solution, warped in gauze and placed then in a plastic bag to be cooled in an icebox.

Laboratorial and radiological tests (skull X-ray) were normal.

The patient was submitted to surgery under general anesthesia about one hour after the first aid. Cleaning with water and neutral soap and debridement were performed.

The scalp was trichotomized and washed once more in saline solution. Next, a wide artery and vein were identified for a surgical anastomosis.

The left superficial temporal artery was dissected as it presented better condition than all other vessels, which were very damaged.

A terminoterminal microsurgical anastomosis of the superficial temporal artery was performed using 10-0 nylon. After the release of the arterial flow, a little was waited for bleeding, in order to facilitate the identification of vessels. The distal stump of the superficial temporal vein was anastomosed with its proximal stump.

The scalp was sutured with 5-0 nylon and the skin of the face with nylon 6-0. Draining with Penrouse drains, cotton plaster and smooth binding were done. Antibiotics (cephalosporin, 3mg/day), platelet antiaggregative (acetylsalicylic acid, 1g/day) and anticoagulator (Liquemine) were used.

The surgery lasted about four hours and the postoperative did not have any interurrences. Hair growth was normal.

## DISCUSSION

Due to religious matters, the patient had very long hair. Besides that, she neglected warping her hair while working near the plow. These factors led to this kind of accident.

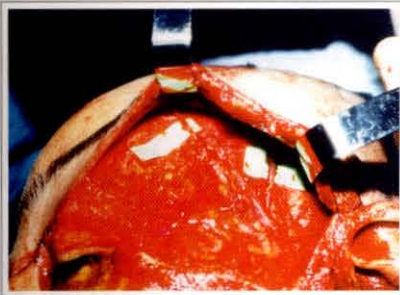


Fig. 5 - Transoperative view of the microanastomosis performed in the arteria and left superficial temporal vein.

Fig. 5 - *Trans-operatório (detalhes das microanastomoses, arterial e venosa (únicas) da artéria e da veia temporal superficial esquerda).*

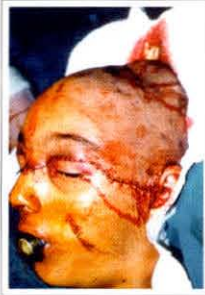

Fig. 6 - Transoperative view of the sutures after vascular reimplantation.

Fig. 6 - *Trans-operatório (detalhes das suturas após o reimplante vascular).*

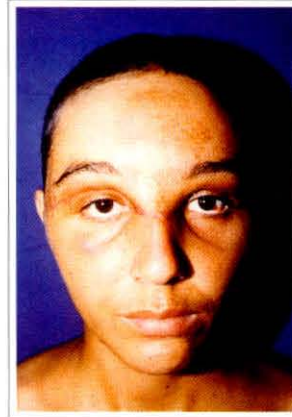

Fig. 7 - 30 days postoperative frontal view. Painless complete integration of the avulsed segment.

Fig. 7 - *Pós-operatório de 30 dias (vista anterior, mostrando integração total do seguimento avulsionado, sem sofrimentos).*

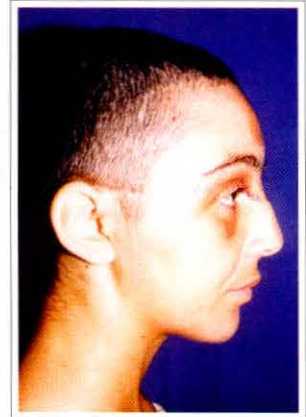

Fig. 8 - 30 days postoperative right profile view.

Fig. 8 - *Pós-operatório 30 dias (vista lateral direita).*

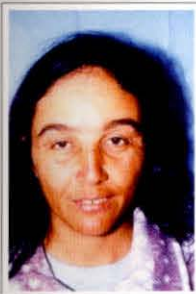

Fig. 9 - Postoperative view after 6 years and 10 months. Frontal view showing hair growth.

Fig. 9 - *Pós-operatório de 6 anos e 10 meses (vista anterior mostrando o crescimento dos cabelos).*

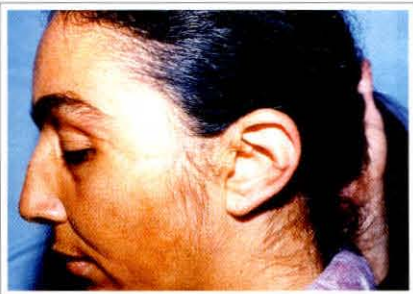

Fig. 10 - Postoperative view after 6 years and 10 months. Left profile view, showing face and ear scar sequelae.

Fig. 10 - *Pós-operatório de 6 anos e 10 meses (vista lateral esquerda mostrando seqüelas cicatriciais de orelha esquerda e face).*

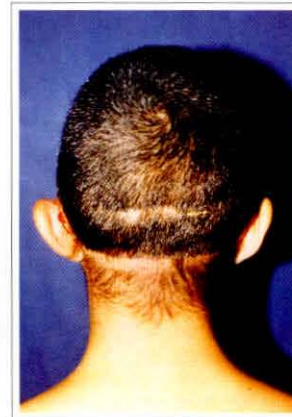

Fig. 11 - 30 days postoperative rear view.

Fig. 11 - *Pós-operatório de 30 dias (vista posterior).*



Fig. 12 - Postoperative view after 6 years and 10 months showing hair length, due to religious beliefs.

Fig. 12 - *Pós-operatório de 6 anos e 10 meses (mostrando o tamanho dos cabelos, devido à crença religiosa).*

The avulsion mechanism in these cases is generated by a continuous rotative movement causing a very intensive traction that results in the avulsion of the affected structure.

Using a hairnet would be an effective way to avoid this kind of accident and such procedure should be obligatory in agriculture.

Microsurgery has led to an adequate restoration (figs.

1, 2, 3, 4, 5) as it immediately reestablished the blood circulation. Generally, the anastomosis of a vein and an artery is enough to restore the circulation in scalp (fig. 3), but it is advisable to restore as many vessels as possible.

The great avulsions look more catastrophic, but they present better results due to the presence of wide remaining vessels in the amputated segments.

## REFERENCES

1. GATTI, JE and LAROSSA, D. Scalp Avulsions and Review of Successful Reimplantation. *Ann. Plast. Surg.* 1981; 6:127.
2. MILLER, GDH, AMSTEE, EJ, SNELL, JA. Successful Reimplantation of an Avulsed Scalp by Microvascular Anastomosis. *Plast. Reconst. Surg.* 1976; 58:133.
3. NAHAI, F, HURTEAU, J, VASCONES, LO. Reimplantation of an Entire Scalp and Ear by Microvascular Anastomosis of only one Artery and one Vein. *Br. J. Plast. Surg.* 1978; 31:339.
4. SAKAI, S, SOEDAS, S, ISHII, Y. Avulsion of the Scalp wich one is the best Artery for Anastomosis? *Ann. Plast. Surg.* 1990; 24:350.
5. STRATOUDAKIS, AC and SAVITSKY, LB. Microsurgical Reimplantation of Avulsed Scalp. *Ann. Plast. Surg.* 1981; 7:312.