

Condylar Reconstruction with Costochondral Graft after Osteosynthesis for Fracture Dislocation

Luiz Carlos Manganello-Souza, MD¹

1] Chief of Oral and Maxillofacial Surgery, Department of Surgery.

Work performed at the Medical School of Santa Casa,
São Paulo, Brazil.

Keywords: condylar fracture; condylar reconstruction; costochondral graft.

ABSTRACT

Condylar resorption after a fracture dislocation, treated by reduction and osteosynthesis, in a 14 year-old girl was treated by costochondral graft fixed with two screws. Restoration of good aesthetic and normal occlusion was achieved.

INTRODUCTION

Fractures of the mandibular condyle are still subject of controversy. In cases of fracture dislocation, authors^(1, 11) indicate an open reduction with osteosynthesis of the condyle. Other professionals do not indicate surgery at all⁽⁹⁾.

We indicate surgery on clinical basis, not roentgenographically. Malocclusion, with open bite, restriction in moving the mandible are the most striking symptoms that indicate surgery. Most times we see a fracture dislocation without any occlusal disturbance.

In cases of condylar resorption or even in surgeries for internal derangement of the temporomandibular joint, it is indicated to reconstruct the temporomandibular joint. Condyle may be replaced by osseous graft or implant material. Bone graft may be harvested from the skull or from the costal bone.

We present the case of a patient who had an open reduction of a fracture dislocation of the condyle and developed a total resorption of the condyle. In this case we made a costochondral graft.

CASE REPORT

A 14 year-old girl sustained a mental trauma. She complained of pain in the left TMJ region and malocclusion. Radiographically, we observed fracture dislocation of the left condyle. The condyle was attached to lateral pterigoid muscle with no contact with the mandible.

We performed a surgery for reduction and fixation of the condyle through a preauricular incision. A double steel wire was used to fix the condyle (Fig.1). The pa-

tient was put on intermaxillary fixation (IF) for 3 weeks.

After the release of IF the patient started a program of physiotherapy. Four months after the surgery the patient showed a deviation of the mandible towards the affected side on opening and a malocclusion (Figs. 2a & 2b) due to shortening of the left ramus and a facial asymmetry due to lack of tissue in the preauricular region. The patient was referred to an orthodontist but after 6 months he did not get a reestablishment of the occlusion. X-ray revealed a complete resorption of the left condyle at this time.

One year after the fracture and the first surgery, we reoperated to make a reconstruction of the TMJ with costochondral graft and a temporal muscle flap.

The graft was fixed with two titanium screws (Fig. 3) through a submandibular incision and a portion of the temporal muscle rotated through a preauricular incision to perform the disc. The patient remained in IF for one week and then on elastics for one month with restoration of the occlusion (Figs. 4a & 4b).

DISCUSSION

Despite an old discussion beginning at least 40 years ago (Becker-surgical⁽¹⁾ and Thoma-conservative⁽¹³⁾), treatment of fracture dislocation of the condyle is still controversial. Melmed⁽⁹⁾ emphasized 20 years ago that treatment in these fractures is conservative and Messer⁽¹⁰⁾, that it is surgical. Shwipper & Keutken⁽¹¹⁾ compared clinical and surgical treatment in fracture dislocation of the condyle and concluded that surgical stabilization with miniplates produces better results than conservative treatment.

We indicate surgery in cases where there is gross malocclusion and condylar displacement. Some patients with fracture dislocation do not show any malocclusion⁽⁷⁾.

Cases of condylar resorption after osteosynthesis have been reported in the literature⁽⁶⁾. Boyne⁽²⁾ published a technique of a free grafting of displaced condyles in 35 patients with no resorption using a titanium mesh.

Chen et al⁽³⁾ indicated costochondral graft in acute mandibular condylar fracture in which the condyle is severely cominuted.

Prosthetic reconstruction of the mandibular condyle has been performed using a variety of materials^(4, 5).

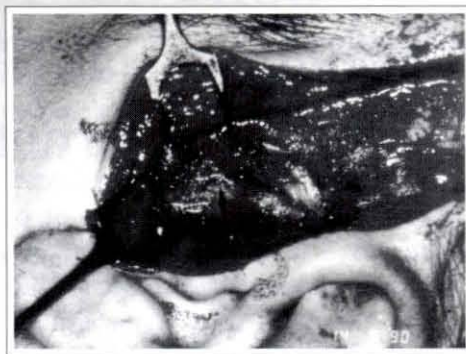


Fig. 1 - Steel wires fixing the condyle.

Fig. 1 - Fios de aço fixando o côndilo.

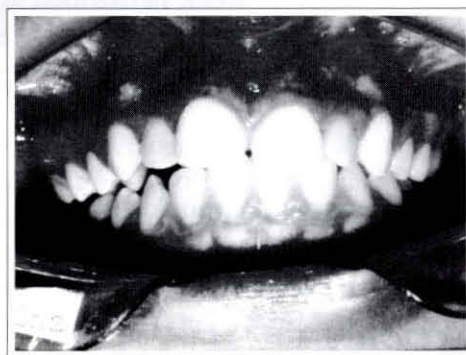

Fig. 2a - Malocclusion in the right side.

Fig. 2a - Má oclusão do lado direito.

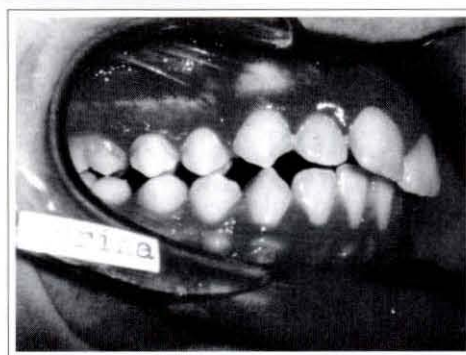


Fig. 2b - Malocclusion in the right side with open bite.

Fig. 2b - Má oclusão do lado direito durante a abertura bucal.

Markowitz et al⁽⁸⁾ idealized a sliding ramus osteotomy to replace the condyle. According to these authors the costochondral graft shows resorption or even undergoes an unpredictable growth. Simpson⁽¹²⁾ referred the use of costochondral graft to reconstruct the TMJ in a series of 11 patients with good results. Recon-

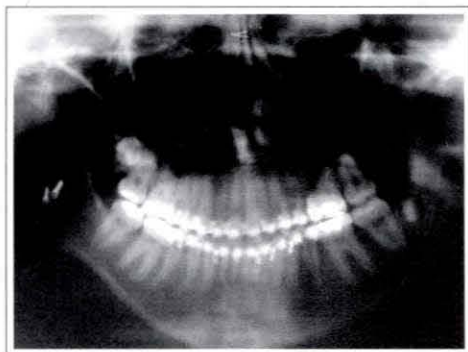


Fig. 3 - Panoramic X-ray showing screws fixing the costochondral graft.

Fig. 3 - Raio X panorâmico mostrando parafusos fixando o enxerto costochondral.

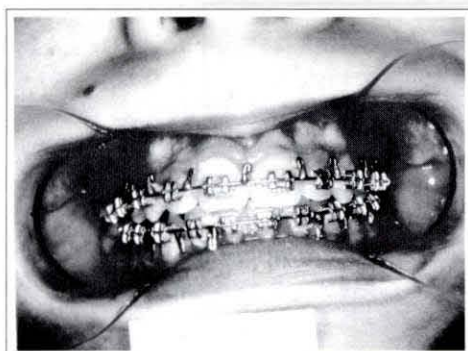


Fig. 4a - Occlusion after costochondral graft.

Fig. 4a - Oclusão após reconstrução com enxerto costochondral.

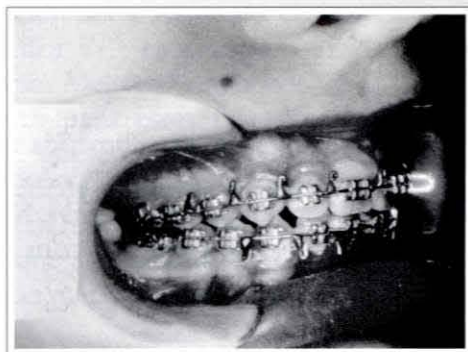


Fig. 4b - Right side with restoration of occlusion.

Fig. 4b - Lado direito com restabelecimento da oclusão.

struction of the condyle may be done with bone graft from the skull. In three patients we used this procedure.

Costochondral graft is indicated to reconstruct the condyle and to correct malocclusion due to resorptions in this area and that temporal muscle flap is appropri-

ate for disc replacement.

REFERENCES

1. BECKER AB. Condylar Fractures. *Oral Surg, Oral Med., Oral Path.* 1952; 5:1282-1286.
2. BOYNE PJ. Free grafting of traumatically displaced or resected mandibular condyles. *J. Oral Maxillofac. Surg.* 1989; 47:228-232.
3. CHEN C, LAI J, CHEN Y. Costochondral graft in acute mandibular condylar fracture. *Plast. Reconstr. Surg.* 1997; 100:1234-9.
4. GOTTLIEB O. Temporomandibular arthroplasty. *Oral Surg.* 1956; 9:362.
5. HARTWELL SW, HALL MD. Mandibular condylectomy with silicone rubber replacement. *Plast. Reconstr. Surg.* 1974; 53:440.
6. IIZA T, LINDQUIST C. Severe bone resorption after miniplate fixation of high condylar fractures. *Oral Surg., Oral Med., Oral Pathol.* 1991; 72:400-3.
7. MANGANELLO-SOUZA LC, VITA J, FISCHMAN R, SILVEIRA ME. Estudo de 32 casos de fraturas do côndilo mandibular. *Rev. A Folha Médica.* 1982; 85(1):825-830.
8. MARKOWITZ, NR, ALLAN, PG, DUFFY, MT. Reconstruction of the mandibular condyle using ramus osteotomies. *J. Oral Maxillofac. Surg.* 1989; 47:367-377.
9. MELMED EP. Fractures of the mandible. *Ann. Roy. Coll. Surgeons England.* 1972; 50:371-381.
10. MESSER EJ. A simplified method for fixation of the fractured mandibular condyle. *J. Oral Surg.* 1972; 30:442-443.
11. SCHWIPPER V, KEUTKEN K. Conservative or Surgical treatment of fractures of the condyle in adults. Proceedings from the 8th International Conference on Oral and Maxillofacial Surgery. Edited by E. Hjørtting-Hansen. Quintessence Publ. Co. 1985; 179-186.
12. SIMPSON W. The costochondral graft. Proceedings from the 8th International Conference on Oral and Maxillofacial Surgery. Edited by E. Hjørtting-Hansen. Quintessence Publ. Co. 1985; 531-536.
13. THOMA KH. Displacement of condyle in fracture-dislocations of the mandible. *Oral Surg., Oral Med., Oral Path.* 1955; 8:774-782.