

Radial Forearm Flap — Experience in 15 Cases of Microsurgical Face and Neck Reconstruction

Edgard Rocha Silva, MD¹
Roberto Zimmer Prados, MD²
Alberto Gonçalves Camargos, MD³
Diva Novy Barbosa Chaves, MD⁴
Lucília Brigato Paviato, MD⁵

- 1] Professor of the Faculty of Medicine of the UFMG.
- 2] Chief of the Plastic Surgery Division of the Hospital da Baleia, Fundação Benjamin Guimarães.
- 3] Professor of Plastic Surgery of the Faculty of Medical Sciences – Belo Horizonte - MG.
- 4] Resident in Plastic Surgery of the Hospital das Clínicas, UFMG.
- 5] Resident in Plastic Surgery of the Hospital das Clínicas, UFMG.

Address for correspondence:

Edgard Rocha Silva, MD

R. Paulo Freire de Araújo, 30
30450-600 - Belo Horizonte - MG
Brazil

Phone: (55 31) 344-9925 Fax: (55 31) 296-9076

Keywords: Forearm; surgical flaps; case report; head and neck reconstruction.

ABSTRACT

Due to its fair, fine texture and hairless skin, and its thin subcutaneous tissue, the radial forearm flap has been largely utilized in face and neck reconstructions. We analyzed retrospectively our patients who had been submitted to face and neck reconstructions with this flap. From 1994 to 1998, we operated on fourteen patients, including eight women and six men. Their ages ranged from 13 to 63 years old. One patient was operated on 2 times, totalizing 15 flaps. The facial vessels were utilized for 87% of the microvascular anastomosis. In all of the cases we set on a reverse flux. The donor site was covered with a thigh split thickness skin graft. The microvascular anastomosis was successful in 93% of the cases. There were only two complications (13%). In one case the venous anastomosis thrombosed and the flap suffered total necrosis. The area was successfully reconstructed with the contralateral flap. Another patient suffered a parcial necrosis of the split thickness skin graft at the donor site, which was closed by secondary intention. These results stress the choice of the radial forearm flap as one of the best in face and neck microsurgical reconstructions. The main shortcoming is the unpleasant scar in the donor site.

INTRODUCTION

The radial forearm flap was first described as a free flap by Yang et al. in 1978, in China^(1,2). Due to that, it is known as "the chinese flap". In 1982, Song et al. published their good results utilizing this flap in 31 patients with postburn scar contractures of the face and neck⁽³⁾. Since then, this flap has been largely utilized in the western world due to its several clinical applications. Nowadays, it is utilized in face and neck reconstructions, including the oral cavity, nose and pharynx and esophagus.

It has many advantages. Its vascular pedicle is long and its vessels have large caliber, facilitating the vascular anastomosis. The comitant veins together with the radial artery do not have valves, allowing the flux to be reversed. It can be utilized as a composite flap including nerve, bone or tendon⁽⁴⁾. Besides that, the forearm skin is similar to that of the face, since it is fair, with a fine texture, almost hairless, and the sub-jacent subcutaneous tissue is thin. These features make the radial forearm flap the ideal cover for the face and the neck.

We analyzed our patients retrospectively to show the results and complications associated to the use of this

flap in face and neck reconstructions.

PATIENTS AND METHODS

From 1994 to 1998, fourteen patients were submitted to extensive resections of lesions in the face or in the neck.

All of these patients underwent radial forearm flap reconstruction through microvascular anastomoses.

The surgical technique was the same described by Song et al.⁽¹⁾ (Fig. 1) despite some modifications. We always harvest the flap from the upper forearm end, in order to reduce the morbidity resulting from tendon exposure. In the lower forearm we have incised the skin longitudinally only to obtain a longer vascular pedicle, and we have sutured primarily the resulting linear incision. That is why all of the related cases were anastomosed with a reverse blood supply.

The end to end vascular anastomosis were carried out with the facial artery or the temporal superficialis artery and the venae comitantes. The choice has been made according to the site of the resection and the extension of the flap pedicle. We do prefer the facial artery due to its larger caliber and lesser tortuosity. The cephalic vein has not been utilized in any of our anastomosis.

The donor site in the forearm was covered with a split-thickness skin graft from the thigh. Above the graft we made a tie-over dressing and the extremity was immobilized with a plaster cast.

RESULTS

The cases are described in Table I. Figures 2 to 7 are

Diagnostic	Age	Sex	Flap	Anastomosis	Complications
1. Lower lip ecc*	48	m	composite	facial a.	total necrosis
2. Lower lip ecc*	48	m	composite	facial a.	absent
3. Frontal pigmented nevus	32	f	simple	temporal a.	absent
4. Upper lip hemangioma	19	m	simple	facial a.	absent
5. Mentual bcc* recidive	63	f	simple	facial a.	absent
6. Frontal flap hemangioma	46	f	simple	temporal a.	parcial graft loss in the donor site
7. Chronic mandible osteomielitis	28	m	simple	facial a.	absent
8. Nasal eccrine sweat gland carcinoma	32	f	simple	facial a.	absent
9. Mandible osteossarcoma	48	m	simple	facial a.	absent
10. Cervical contracture	18	f	simple	facial a.	absent
11. Mento-thoracic contracture	13	f	simple	facial a.	absent
12. Cervical contracture	19	m	simple	facial a.	absent
13. Mento-thoracic contracture	13	f	simple	facial a.	absent
14. Cervical contracture	15	f	simple	facial a.	absent
15. Cervical contracture	25	m	simple	facial a.	absent

Patients submitted to face and neck microsurgical reconstruction, from 1994 to 1998.
* ecc: escamous cell carcinoma; bcc: basal cell carcinoma.




Fig. 1 - Radial forearm flap as described by Yang et al. in 1978, draining through the cephalic vein.

Fig. 1 - Retalho radial do antebraço conforme descrito por Yang e cols. em 1978, com drenagem através da veia cefálica.

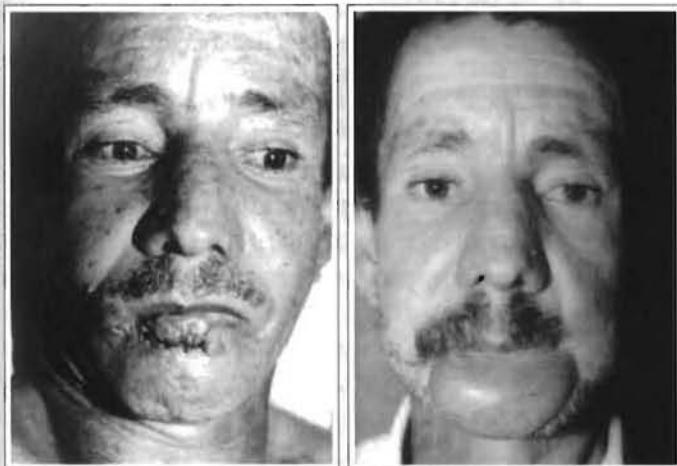

Fig. 2 - Cases 1 and 2: Lower lip escamous cell carcinoma. A. Preoperative view. B. Three months after the second surgery.

Fig. 2 - Casos 1 e 2: Carcinoma espinocelular do lábio inferior. A. Pré-operatório. B. Três meses após a segunda intervenção cirúrgica.

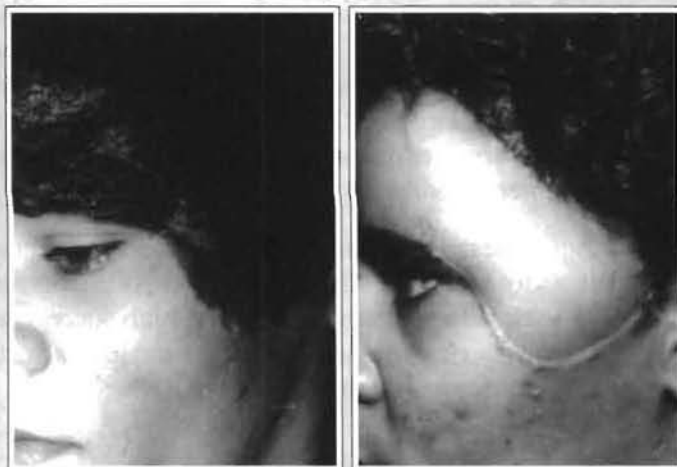

Fig. 3 - Case 3: Frontal pigmented pilous nevus. A. Preoperative view. B. Final result after three months.

Fig. 3 - Caso 3: Nevus pigmentado piloso na frente. A. Pré-operatório. B. Resultado final após três meses.

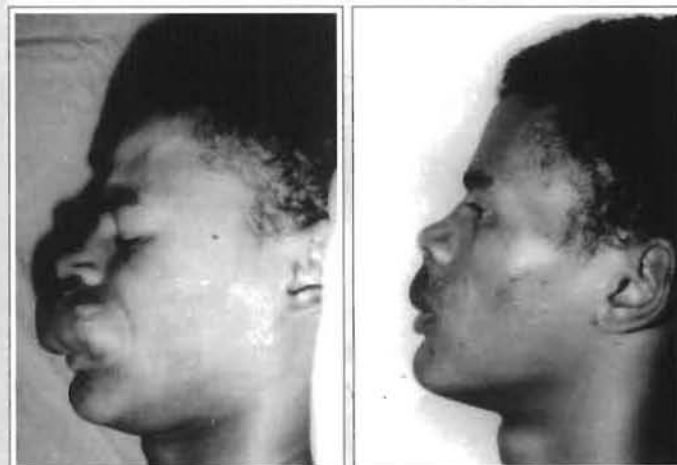


Fig. 4 - Case 4: Upper lip hemangioma, recidive. A. Preoperative view. B. Postoperative view after six months.

Fig. 4 - Caso 4: Hemangioma de lábio superior, recidivado. A. Pré-operatório. B. Pós-operatório após seis meses.

related to pre and postoperative aspects of some patients. We operated on fourteen patients, performing fifteen flaps. They were 13 to 63 years old, six males and eight females. The microvascular anastomosis was carried on with the facial artery and its venae comitantes in 13 of 15 patients (87%). In two patients only we utilized the temporalis superficialis artery and its venae comitantes. In all of our patients we established a reverse blood flow.

All of the patients were satisfied with the cosmetic appearance of the reconstruction, except for two women who complained about the thickness of the adjacent skin. One of them was submitted to a partial resection and stretching of the flap, and she is now satisfied with the final result. The other one will be submitted to the same surgery. One patient considered the resulting scar at the donor site as unpleasant.

One male patient presented a venous thrombosis and consequent total necrosis of the flap. He has been submitted to another microsurgical reconstruction with the opposite radial forearm flap, which was successful. In both cases, we have made a composite flap, including the tendon of the palmaris longus muscle. It has been fixed on the orbicularis oris muscle, assuring better oral continence. Cases 1 and 2 of Table I corresponds to this patient.

One female patient suffered a parcial loss of the graft in the forearm, with a consequent exposure of the tendon of the flexor carpi radialis in a 2x2 cm area. The granulating tissue has grown in this area and it was closed by secondary intention. In the other patients we reached a good result in the donor area of the upper forearm (Fig. 7c).

DISCUSSION

Microvascular surgery has progressed, and success rates of 96 to 98 percent have been reported⁽⁵⁾. Our experience with the radial forearm flap has shown the confiability of this flap, since we succeeded in 93 percent of the cases. These results increase the popularity of microsurgical flaps, and their indications have become less restricted. Nowadays, in many circumstances, free tissue transfer is the preferred

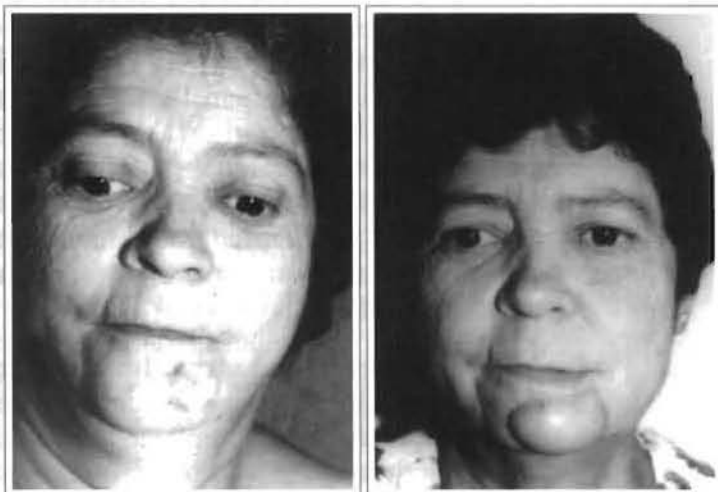

Fig. 5 - Case 5: Mental basal cell carcinoma, recidive. A. Preoperative view. B. Three months after operation.

Fig. 5 - Caso 5: Carcinoma basocelular recidivado em mento. A. Pré-operatório. B. Três meses após a cirurgia.

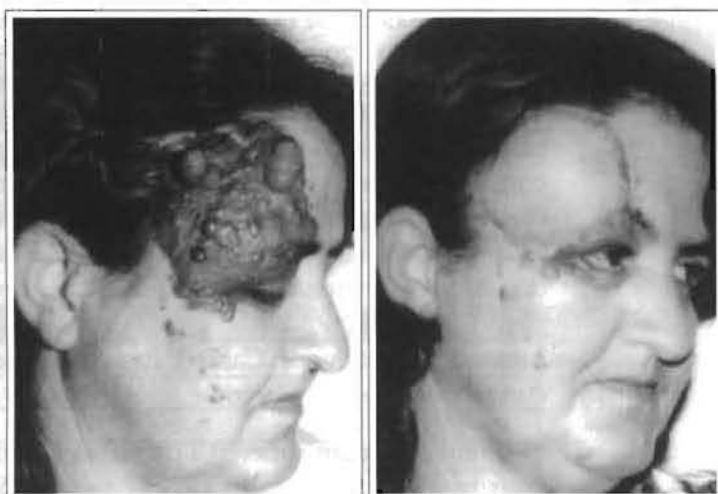

Fig. 6 - Case 6: Ulcerated frontal flat hemangioma. A. Preoperative view. B. Postoperative view after three months.

Fig. 6 - Caso 6: Hemangioma plano ulcerado na frente. A. Pré-operatório. B. Pós-operatório aos três meses.

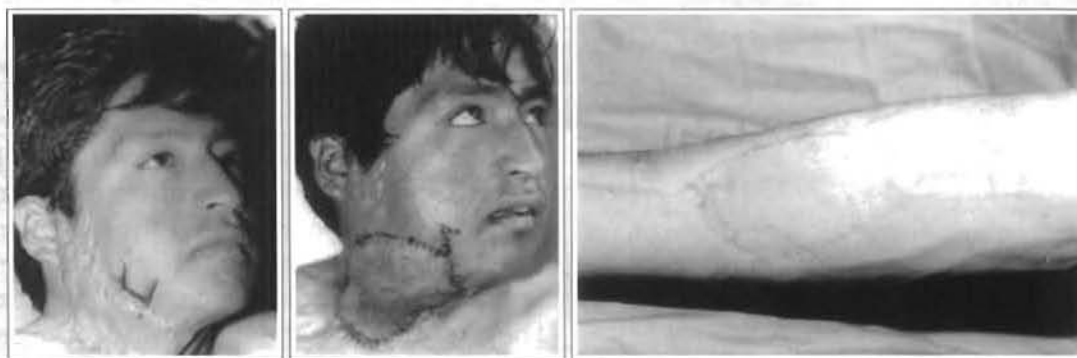

Fig. 7 - Case 12: Postburn cervical contracture. A. Preoperative view. B. Recent postoperative view. C. Postoperative view of the donor area in the forearm after six months.

Fig. 7 - Caso 12: Contratura cervical pós-queimadura. A. Pré-operatório. B. Pós-operatório recente. C. Aspecto da área doadora no antebraço aos seis meses de pós-operatório.

method of treatment, even though conventional local or distant flaps are available.

The donor-site morbidity is the main shortcoming of this flap^(6,7). Tendon exposure, mainly in the lower forearm, prevents the "take" of the graft, since the peritendinous tissue is frequently removed together with the flap. In our patients this happened only once (7%), but the reported rate can reach 79%⁽⁸⁾. This problem can be avoided through careful dissection, preserving peritendinous tissue, or protecting the tendons with the adjacent muscle bellies. Other procedures described are full-thickness skin grafts harvested from the abdomen, preexpansion of the forearm skin⁽⁶⁾ or prefabrication of fascial split-thickness skin graft, preserving forearm skin⁽⁹⁾.

Partial graft loss may be treated conservatively with dressings and debridements of exposed tendons, and they heal by secondary intention. Alternatively, this area can be grafted again. Therefore partial graft loss does not bring long-term morbidity.

The radial forearm flap is one of the best choices for face and neck reconstructions, due to its functional and aesthetic features, high success rates of microvascular anastomosis and low incidence of donor site morbidity.

REFERENCES

1. YANG G, BAOQUI C, YUZHIG. Free forearm skin transplantation. *Natl. Med. J. China* 1981; 61:139-41.

2. YANG GF, CHEN PJ, GAO YZ, LIU XY, LI J, JIANG SX, HESP. Forearm free skin flap transplantation. *Br. J. Plast. Surg.* 1997; 50:162-5.
3. SONG R, GAO Y, SONG Y, YU Y, SONGY. The forearm flap. *Clin. Plast. Surg.* 1982;9:21-6.
4. SERLETTI JM, TAVIN E, MORAN SL, CONIGLIO JU. Total lower lip reconstruction with a sensate composite radial forearm-palmaris longus free flap and a tongue flap. *Plast. Reconstr. Surg.* 1997; 99:559-61.
5. KROLL SS, SCHUSTERMAN MA, REECE GP, MILLER MJ, EVANS GR, ROBB GL, BALDWIN BJ. Choice of flap and incidence of free flap success. *Plast. Reconstr. Surg.* 1996; 98:459-63.
6. SHOELLER T, OTTO A, WECHSELBERGER G, LILLE S. Radial forearm flap donor-site complications and morbidity. *Plast. Reconstr. Surg.* 1998; 101:874-5.
7. SUOMINEN S, SHOYUO J, ASKOSELJAVAARA S. Donor site morbidity of radial forearm flap. *Scand. J. Plast. Reconstr. Hand Surg.* 1996; 30:57-61.
8. RICHARDSON D, FISHER SE, VAUGHAN ED, BROWN JS. Radial forearm flap donor-site complications and morbidity. *Plast. Reconstr. Surg.* 1997; 99:109-15.
9. WOLFF KD, ERVENS J, HOFFMEISTER B. Improvement of the radial forearm donor site by prefabrication of fascial-split-thickness skin grafts. *Plast. Reconstr. Surg.* 1996; 98:358-61.