

Evaluation of the Nipple-areola Complex Sensibility after Reduction Mammoplasty by Superior Vertical Dermal Pedicle

Antonio Carlos Abramo, MD¹
Lytza Mara Ferreira Oliveira, MD²
Renato Chiavegati Milan, MD²
Silmara Mateus, MD²

- 1] Doctor in Plastic Surgery by Escola Paulista de Medicina, UNIFESP.
Head Professor of ACA - Grupo Integrado de Assistência em Cirurgia Plástica at Beneficência Portuguesa.
- 2] Resident doctors of ACA - Grupo Integrado de Assistência em Cirurgia Plástica.

Address for correspondence:

Antonio Carlos Abramo, MD

R. Afonso de Freitas, 641
04006-052 - São Paulo - SP
Brazil

Keywords: Nipple-areola complex; superior vertical dermal pedicle; sensuality; sensation.

ABSTRACT

Light touch by cotton wool and needle test were employed to evaluate nipple-areola complex sensibility, either sensuality or sensation, after reduction mammoplasty using a superior vertical dermal pedicle for the nipple-areola complex. Sensuality was expressed by nipple erectility and sensation by areola contraction. Non parametric tests were used to analyze data concerning the return of sensibility for the nipple-areola complex. Return of sensibility for the nipple-areola complex, amount of the mammary tissue removed and elevation of the nipple-areola complex to its new position were compared.

INTRODUCTION

Although many types of reduction mammoplasty have been described, few references concerning return of the sensation and sensuality of the nipple-areola complex after surgery have been reported⁽⁴⁾. The nipple-areola complex receives its main nerve supply through intercostal nerves. Sensation is supplied laterally by the lateral cutaneous branch of the III, IV, and V intercostal

nerves and medially by the anterior cutaneous branch of the III, IV, V, and VI intercostal nerves⁽⁹⁾. The anterior and lateral branches of the cutaneous rami of the IV intercostal nerve pass through the subcutaneous tissue from the mammary circumference to the nipple-areola complex, being specific to it⁽⁸⁾. Sensation provided by supraclavicular branches of the cervical plexus

has also been described for the nipple-areola complex⁽¹⁰⁾. Sensuality is supplied by the sympathetic nervous system⁽¹²⁾. It is realized through the fibers from the paravertebral ganglia to the second through the sixth intercostal nerves, to their final distribution to the smooth muscle present in the nipple⁽¹²⁾. Light pressure and crude touch were used for the qualitative measure of the nipple-areola complex sensibility⁽⁵⁾. Needle test has also been employed to analyze the nipple-areola complex sensation⁽³⁾. Another clinical evaluation concerning nipple-areola complex sensation has been performed comparing information related by the patients before and after the surgery⁽¹⁾. Schwarzmann⁽¹¹⁾ was the first to emphasize the importance of a dermal network for nipple-areola complex viability. Thereafter, many authors have developed dermal pedicles containing the nipple-areola

complex as superior^(2, 14), lateral⁽¹³⁾ or inferior⁽⁶⁾ for reduction mammoplasty.

Evaluation of the return of the nipple-areola complex sensibility, either sensation or sensuality, after reduction mammoplasty using a dermal flap with superior vertical pedicle for the nipple-areola complex is described.

MATERIALS AND METHOD

Reduction mammoplasty employing a pattern previously described⁽²⁾ was used on thirty patients with ages ranging from 22 to 56 presenting asymmetrical hypertrophic breasts with a variable degree of ptosis. Table I summarizes patient preoperative conditions and outcomes. The pattern creates a dermal flap with superior vertical pedicle for the nipple-areola com-

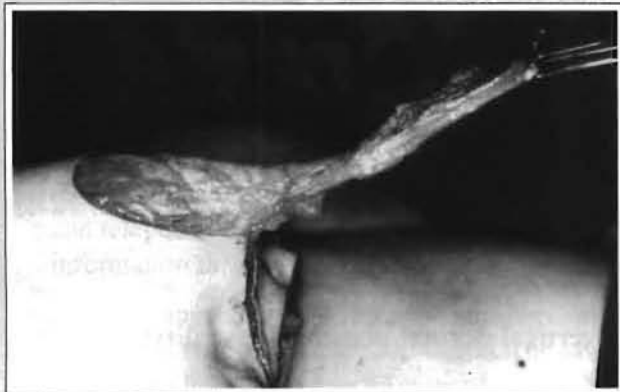

Fig. 1a - Dermal flap to the nipple-areola complex.

Fig. 1a - Retalho do CAM.

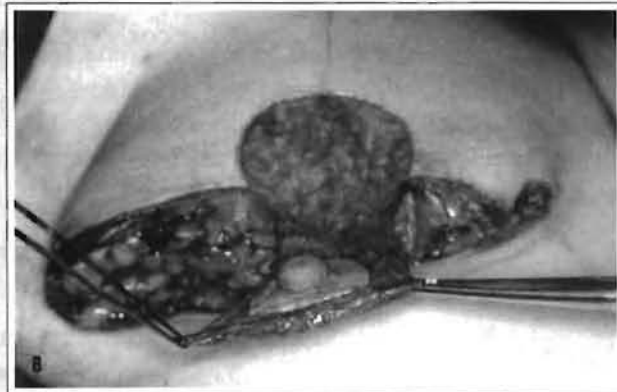


Fig. 1b - The pattern creates a superior vertical pedicle to the nipple-areola complex.

Fig. 1b - O "molde" cria um retalho superior vertical em relação à aréola.

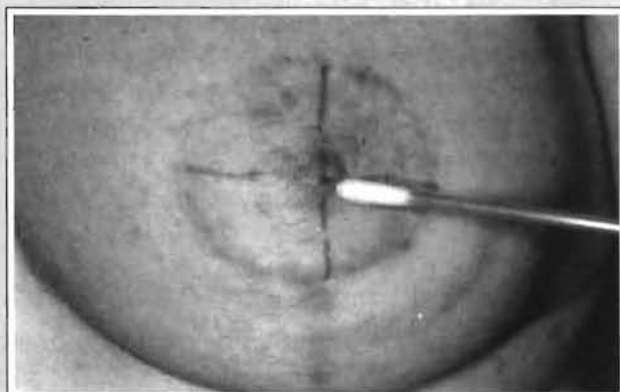


Fig. 2a - Light touch by cotton was used to evaluate either sensuality...

Fig. 2a - Toque suave com haste de algodão para avaliação tanto da sensualidade...

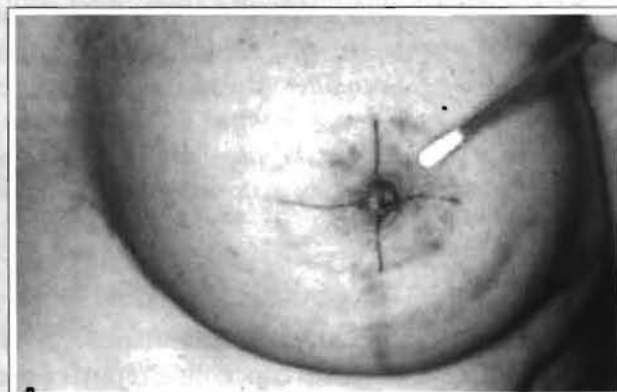


Fig. 2b - ... or sensation.

Fig. 2b - ... quanto da sensibilidade.

Table I

Age	Pregnancy	Areola diameter (cm)		Sensuality return (week)		Sensation return (month)		Tissue removal (gr)		NAC elevation (cm)		NAC compromise	
		before	after	right	left	right	left	right	left	right	left	right	left
56	+	6.5	5.0	3	3	4	6	738	650	11.0	12.0	+	+
26	-	5.0	4.5	1	1	2	2	390	316	5.0	5.0	-	-
41	+	5.5	4.5	1	2	2	3	252	385	2.0	4.5	-	-
24	-	5.0	4.5	1	2	2	2	463	425	6.0	7.5	-	-
43	+	4.5	4.5	2	2	3	4	328	270	3.0	3.5	-	-
56	+	6.0	5.0	3	2	6	3	944	685	9.0	6.5	-	-
31	+	6.5	4.5	2	2	3	3	385	412	6.0	7.0	-	-
38	+	6.0	4.5	2	2	3	3	397	363	7.0	7.0	-	-
40	+	5.5	4.5	2	3	4	5	291	314	5.0	6.0	-	-
41	+	5.5	4.5	1	1	2	2	497	566	6.0	6.0	-	-
41	+	6.0	4.5	2	1	4	3	318	332	6.5	5.0	-	-
30	+	5.0	4.5	1	1	1	1	297	305	3.0	4.5	+	-
43	+	6.5	5.0	2	2	3	3	506	387	10.0	8.0	-	-
51	+	7.0	4.5	1	2	3	3	619	530	7.0	7.0	-	-
43	+	4.5	4.5	2	2	3	3	270	295	4.0	5.5	-	-
41	+	7.0	4.5	2	3	3	4	703	880	7.5	10.0	-	-
37	+	6.5	5.0	2	2	4	3	939	821	9.0	7.0	-	-
22	-	5.5	4.5	3	2	4	3	430	416	5.5	5.0	-	-
26	+	5.0	4.5	2	1	3	3	383	315	4.0	4.0	-	-
26	+	6.5	5.0	3	2	6	6	883	625	11.0	9.0	-	+
44	+	6.0	5.0	1	2	3	3	530	619	7.0	7.0	-	-
31	+	5.5	4.5	2	2	2	3	295	312	4.0	4.5	-	-
49	+	4.5	4.5	2	1	2	2	280	276	5.0	6.0	-	-
36	+	5.0	4.5	1	1	2	2	312	316	3.0	3.0	-	-
39	+	5.5	5.0	3	3	4	5	508	531	9.0	10.0	-	-
43	+	6.0	5.0	2	3	4	7	973	890	12.0	11.0	-	-
36	+	5.0	4.5	1	1	2	2	339	251	2.0	2.5	-	-
51	+	6.5	5.0	2	2	4	5	675	690	9.0	9.5	-	-
38	-	5.5	4.5	1	1	1	2	317	325	4.0	5.0	-	+
37	-	5.5	5.0	2	2	3	4	533	551	5.0	5.5	-	-

Patient preoperative conditions and outcomes.

Table II

Sensation									
Month						Frequency			
1	2	3	4	5	6	SLQ	SMQ	ILQ	IMQ
A	A	A	A	A	A	-	-	-	-
A	A	A	A	A	P	-	-	4	-
A	A	A	A	P	P	1	-	3	2
A	A	A	P	P	P	-	1	7	6
A	A	P	P	P	P	4	4	18	21
A	P	P	P	P	P	6	15	20	20
P	P	P	P	P	P	49	40	8	19
Total						60	60	60	60

Sensation present (P) or absent (A) for each quadrant of the nipple-areola complex at monthly intervals. Cochran's test - p<0.001

Table III

Right Breast			Left Breast		
sensation return	tissue removed	NAC elevation	sensation return	tissue removed	NAC elevation
4	738	11.0	6	650	12.0
2	390	5.0	2	316	5.0
2	252	2.0	3	385	4.5
2	463	6.0	2	425	7.5
3	328	3.0	4	270	3.5
6	944	9.0	3	685	6.5
3	385	6.0	3	412	7.0
3	397	7.0	3	363	7.0
4	291	5.0	5	314	6.0
2	497	6.0	2	566	6.0
4	318	6.5	3	332	5.0
1	297	3.0	1	305	4.5
3	506	10.0	3	387	8.0
3	619	7.0	3	530	7.0
3	270	4.0	3	295	5.5
3	703	7.5	4	880	10.0
4	939	9.0	3	821	7.0
4	430	5.5	3	416	5.0
3	383	4.0	3	315	4.0
6	883	11.0	6	625	9.0
3	530	7.0	3	619	7.0
2	295	4.0	3	312	4.5
2	280	5.0	2	276	6.0
2	312	3.0	2	316	3.0
4	508	9.0	5	531	10.0
4	973	12.0	7	890	11.0
2	339	2.0	2	251	2.5
4	675	9.0	5	690	9.5
1	317	4.0	2	325	5.0
3	533	5.0	4	551	5.5

Return of the nipple-areola complex sensation (month) with relation to the amount of mammary tissue removed (gr), and the nipple-areola complex elevation (cm). McNemar's test - p<0.001.

plex (Fig. 1). It also defines the diameter and the new site of the nipple-areola complex, and the amount of mammary tissue to be removed. The superior pole of the breast was maintained intact. A test with fluorescein sodium 10% was used to determine vascular compromise of the nipple-areola complex. Light touch by cotton wool was applied to evaluate the nipple-areola complex sensibility, either to sensuality or to sensation (Fig. 2). Needle test was also applied to evaluate the nipple-areola complex sensibility, concerning areola sensation (Fig. 3). Sensuality was characterized by nipple erection, and sensation by areola contraction and the degree of pain related by the patient (Fig. 4). To give a better evaluation for the areola sensation, the nipple-areola complex was divided into four quadrants: SLQ - superior lateral quadrant, SMQ - superior medial quadrant, ILQ - inferior lateral quadrant, IMQ - inferior medial quadrant (Fig. 5). Sensation was reported as absent or present through the contraction of the areola in each quadrant of the nipple-areola complex. Sensation was also reported as present or absent in relation to the degree of pain reported by the patient in each quadrant of the nipple-areola complex. Data concerning areola sensation were provided through the areola contraction and the information mentioned by the patients every month after reduction mammoplasty, until sensibility was present in the four quadrants. Return of sensibility was analyzed and data compared with the amount of mammary tissue removed and nipple-areola complex elevation. Non parametric tests were applied for analysis of the results and the respective level of significance was established for each test.

RESULTS

Sixty nipple-areola complex of thirty female patients had its diameters reduced with a variation from 4.5 to 5.0 cm and sustained by a dermal flap with superior vertical pedicle. Table 1 summarizes preoperative conditions and outcomes. Even though the

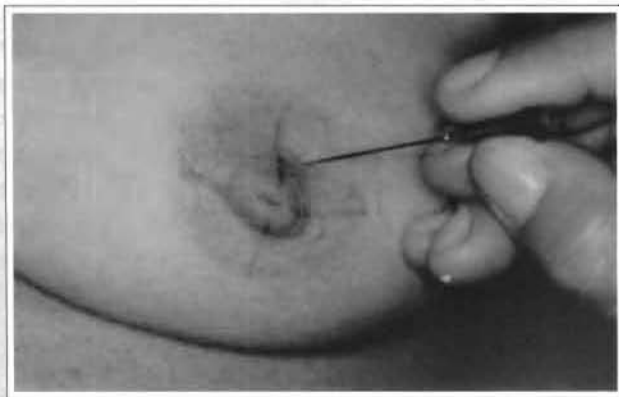


Fig. 3 - Needle test to evaluate areola sensation.

Fig. 3 - Teste com agulha para avaliar a sensibilidade da aréola.

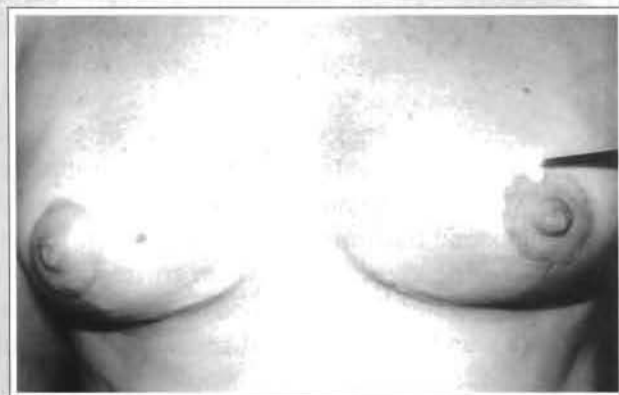


Fig. 4 - Light touch with cotton produces areola contraction on the left breast. No contraction is observed on the right breast.

Fig. 4 - Um toque suave com tecido de algodão produz contração da aréola esquerda. Não houve contração da aréola direita.

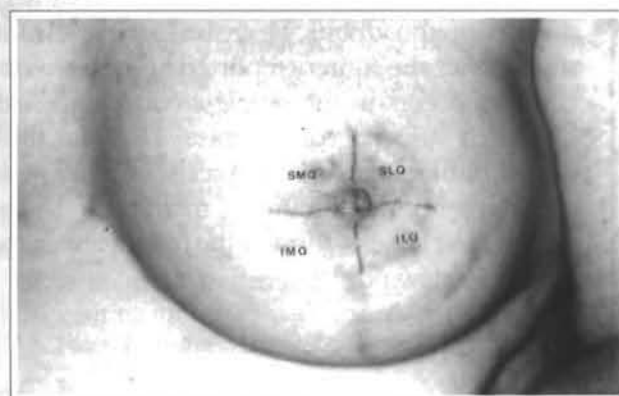


Fig. 5 - Nipple-areola complex divided into quadrants. SLQ - superior lateral quadrant. SMQ - superior medial quadrant. ILQ - inferior lateral quadrant. IMQ - inferior medial quadrant.

Fig. 5 - CAM dividido em quatro quadrantes. SLQ - quadrante lateral superior; SMQ - quadrante medial superior; ILQ - quadrante lateral inferior; IMQ - quadrante medial inferior.

test with fluorescein sodium does not reveal vascular compromise, five nipple-areola complex presented suffering, four in the inferior quadrants and one in the superior and inferior lateral quadrants. Reduction in the areola diameter did not affect the return of sensibility. Permanent loss of nipple erection or areola contraction was not found in this group of patients. Decrease in the level of sensibility after reduction mammoplasty regarding the level of sensibility before the surgery was reported in five nipple-areola complex of four patients. Nipple erection returned earlier than areola contraction and after 1 to 3 weeks from surgery (Fig. 6). Return of the nipple-areola complex sensation was more expressive (41/60) in the first 3 months after reduction mammoplasty (Fig. 7). Areola contraction and pain were recovered simultaneously on each quadrant of the nipple-areola complex, being present into the four quadrants until the sixth month after surgery. Only one nipple-areola complex recovered sensation seven months after reduction mammoplasty. Cochran's test ($p < 0.001$) was employed to determine the level of significance of the return of sensation to each quadrant of the nipple-areola complex at monthly intervals. Table 2 shows monthly progressive increase in the return of sensation to each nipple-areola complex quadrant. McNemar's test ($p < 0.001$) was applied to compare return of sensation between the quadrants of the nipple-areola complex. Return of sensation on the superior quadrants was significantly higher than on the inferior quadrants (Fig. 8). Sensation in the superior medial quadrant returned first. McNemar's test ($p < 0.001$) was also applied to compare return of the nipple-areola complex sensation between both right and left breasts. No significant difference was observed. Spearman's coefficient ($p < 0.003$) was used to analyze return of nipple-areola complex sensation, measured in months, with regard to the amount of mammary tissue removed, quantitated in grams, and with regard to the nipple-areola complex elevation to its new position, measured in centimeters. Table 3 shows positive and significant correlation between return of sensation, amount of mammary tissue removed and elevation of the nipple-areola complex. Return of nipple-areola complex sensation was more delayed, the more elevated it was, and the more mammary tissue was removed.

A representative case is described in details.

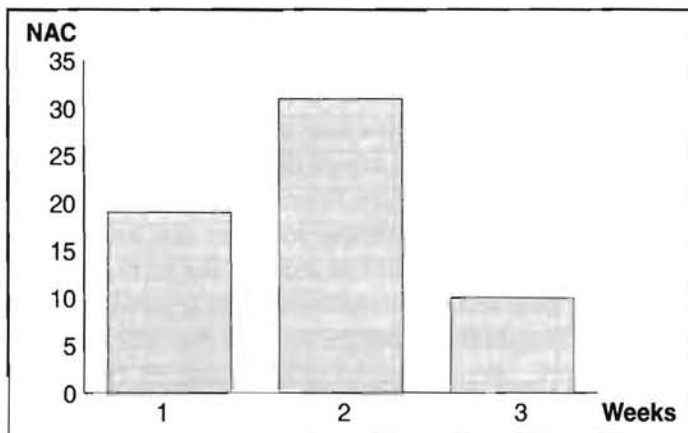


Fig. 6 - Return of nipple-areola complex sensuality.

Fig. 6 - Retorno da sensibilidade do CAM.

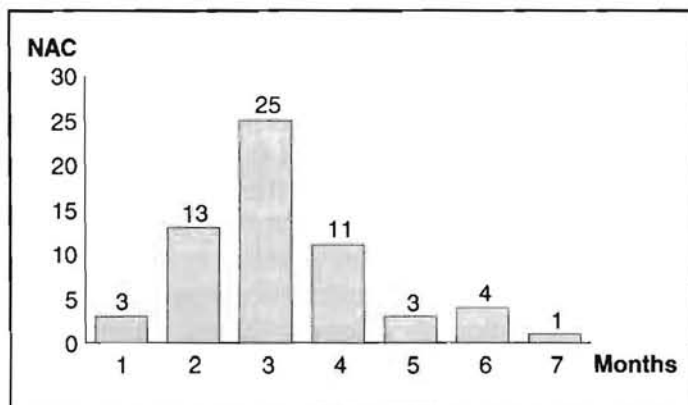


Fig. 7 - Return of nipple-areola complex sensation at monthly intervals.

Fig. 7 - Retorno da sensibilidade do CAM (intervalos mensais).

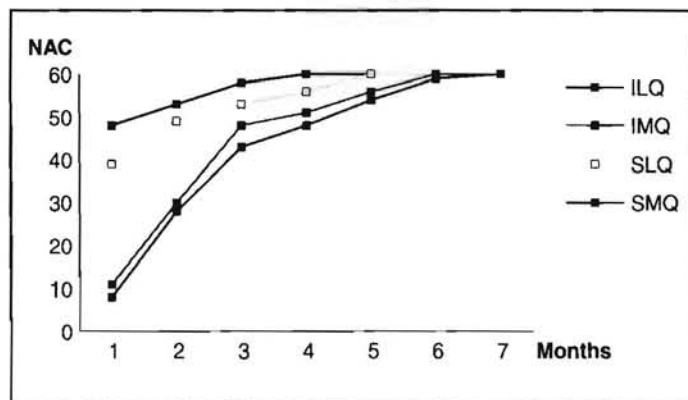


Fig. 8 - Return of sensation for each of the nipple-areola complex at monthly intervals.

Fig. 8 - Retorno da sensibilidade do CAM (intervalos mensais).

A 41 year-old female, two pregnancies, presented asymmetrical large heavy and pendulous breasts (Fig. 9a). She was submitted to reduction mammoplasty with a superior vertical dermal pedicle for the nipple-

areola complex with the diameter of the areola reduced from 7.0 to 4.5 cm. Sensation returned in the 3rd month on the right breast and in the 4th month on the left breast. The amount of mammary tissue removed was 703 g on the right breast and 880 g on the left one. Nipple-areola complex was elevated 7.5 cm on the right breast and 10.0 cm on the left breast. At the end of the first postoperative year the nipple-areola complex remains in its position (Fig. 9b).

DISCUSSION

The breast, operated or not, has an irregular pattern of sensation and is not completely understood⁽⁷⁾. Despite an anatomical correlation between both sensibility parameters, sensuality returned before sensation. Mechanical stimulation of the nipple initiates a neural transmission, which by a reflex arch through the intercostal nerve, induces smooth muscle contraction with earlier nipple erection. Mechanical stimulation of the areola starts the same neural transmission; however, delay in the return of the areola contraction in relation to the nipple erection probably occurs by the absence of a reflex arch in this neural transmission. Maintenance of the whole superior pole of the breast attached to the pectoral muscle preserves the cutaneous branches of the III and IV intercostal nerves. This assures nipple-areola complex sensibility through the dermal flap with superior vertical pedicle. Since the pedicle had a superior position, nipple-areola complex sensation returned earlier for the superior quadrants. Decrease in the level of sensibility after the surgery reported in 5 nipple-areola complex occurs in the nipple-areola complex that presented vascular compromise. Delay in the recovery of nipple-areola complex sensibility was associated with the amount of mammary tissue removed, and the elevation of the nipple-areola complex to its new position.

REFERENCES

1. Abramo AC. *Mamoplastia redutora com pedículo dérmico vertical superior*. Tese para obtenção do Título de Mestrado pela Escola Paulista de Medicina. 1988; 1-108.
2. _____. Pattern for Reduction Mammoplasty that Uses a Superior Vertical Dermal Pedicle. *Aesth. Plast. Surg.* 1991; 15:265-70.

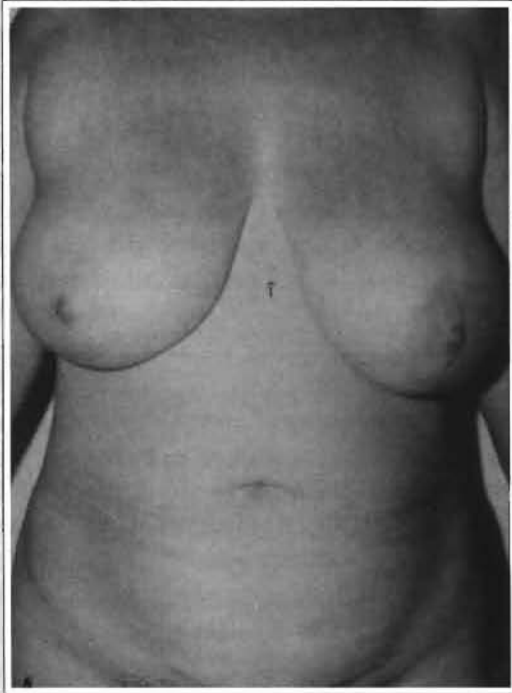


Fig. 9a - Preoperative frontal view of asymmetrical large heavy pendulous breasts.

Fig. 9a - Visão pré-operatória frontal de grandes mamas pendulares assimétricas.

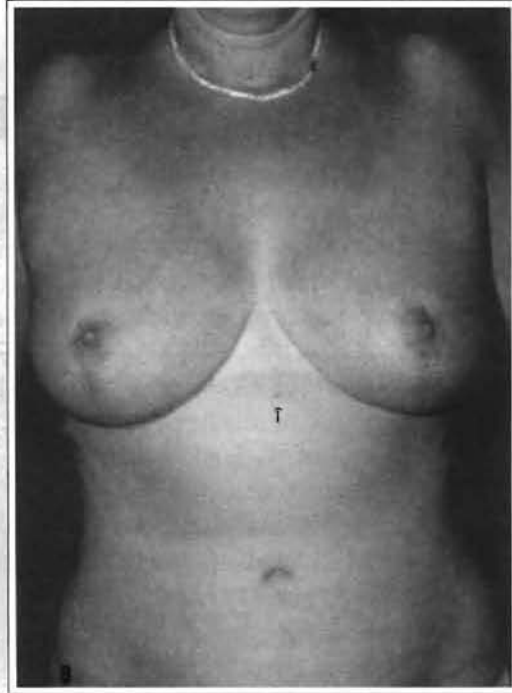


Fig. 9b - 1 year postoperative frontal view. Nipple-areola complex elevation can be evaluated comparing its location before and after surgery in relation to the natural sign pointed by the arrow.

Fig. 9b - Visão frontal de 1 ano pós-operatório. A elevação do CAM pode ser avaliada pela comparação de sua localização no pré e pós operatório em relação à seta indicada.

3. Abramo AC, Viola JC. Avaliação da Sensibilidade do Complexo Aréolo-mamilar após Mamoplastia Redutora. *An. Paul. Med. Cir.* 1993; 120:9-13.
4. Castro CC, Araujo MR. Avaliação dos Resultados Tardios em Mamoplastia. *Rev. Bras. Cir.* 1983; 73:21-5.
5. Courtiss EH, Goldwyn RM. Breast Sensation Before and After Plastic Surgery. *Plast. Reconstr. Surg.* 1976; 58:1-13.
6. _____. Reduction mammoplasty by the inferior technique. An alternative to free nipple and areola grafting for severe macromastia or extreme ptosis. *Plast. Reconstr. Surg.* 1977; 59:501-7.
7. Giebel GD, Jaeger K. Sensibilitätsmessungen vor und nach Mammareduktions-plastic zweier Konkurrierender Operationverfahren. *Langenbecks Arch. Chir.* 1986; 359:299-301.
8. Hagerty RC, Hagerty RF. Reduction Mammoplasty: Central Cone Technique for Maximal Preservation of Vascular and Nerve Supply. *South Med. J.* 1989; 82:183-6.
9. Lockhart RD, Hamilton GF, Fyfe FW. *Anatomy of the Human Body.* 1959; 2 ed, London, Faber and Faber. 274-81.
10. Rees TD. Plastic Surgery of the Breast. IN: Converse JM. *Reconstructive Plastic Surgery.* 1966; Philadelphia and London, WB Saunders Company. 1903-38.
11. Schwarzmann E. Die Technic der Mamoplastic. *Chirurgentagung.* 1930; 2:932-6.
12. Serafin D. Surgical Anatomy of the Breast. IN: Gerogiade NG. *Breast Reconstruction Following Mastectomy.* 1979; St. Louis, Toronto, London, The C.V. Mosby Company. 35-53.
13. Skoog T. A Technique of the Breast Reduction. *Acta Chir. Scand.* 1963; 126:453-7.
14. Weiner DL, Aiache AE, Silver L, Tittiranonda T. A Single Dermal Pedicle for Nipple Transposition in Subcutaneous Mastectomy or Mastopexia. *Plast. Reconstr. Surg.* 1973; 51: 115-20.