



Post-mammoplasty symmastia augmentation with silicone implants: treatment with quilting sutures

Simastia pós-mamoplastia de aumento com implantes de silicone: tratamento com suturas de adesão

MICHEL PAVELECINI^{1,2}

FELIPE BILHAR FASOLIN^{1,2,3*}

EDUARDO MADALOSSO ZANIN^{1,2,4}

BRUNO DELLA MEA GASPERIN^{1,2,3}

FLÁVIO MACIEL DE FREITAS NETO^{1,2}

LEONARDO MILANESI POSSAMAI^{1,2,4}

RONALDO SCHOLZE WEBSTER^{1,2,5}

PEDRO BINS ELY^{1,2,5}

Institution: Irmandade Santa Casa de Misericórdia de Porto Alegre, Porto Alegre, RS, Brazil.

Article received: October 9, 2017.
Article accepted: May 17, 2018.

Conflicts of interest: none.

DOI: 10.5935/2177-1235.2018RBCP0103

■ ABSTRACT

Introduction: Augmentation mammoplasty is the most commonly performed esthetic surgical procedure in the United States and second in Brazil. Symmastia is one of its possible complications. This is defined as incorrect medial positioning of the breast implants, which cross the midline, losing the intermammary sulcus. **Methods:** Work type, series of cases. Two patients underwent symmastia repair after breast augmentation. The access route used was the previous inframammary incision. The repair of the intermammary sulcus was performed by scarification of the anterior and posterior capsule surfaces, associated with adhesion suture with non-absorbable monofilament thread (4 lines with 6 points each, comprising a vertical band of approximately 4 cm wide in the presternal region). In one of the cases, the implant was immediately replaced, and in the other, the procedure was done 3 months later. **Results:** In both cases, we obtained a new satisfactory intermammary sulcus, with proper esthetic result. No recurrence was observed on follow-ups at 9 and 11 months. **Conclusions:** The approach with adhesion sutures to redefine the intermammary sulcus was effective in the treatment of symmastia after breast augmentation.

Keywords: Breast implants; Mammoplasty; Mammary diseases; Breast; Prostheses and implants.

¹ Universidade Federal de Ciências da Saúde de Porto Alegre, Porto Alegre, RS, Brazil.

² Santa Casa de Misericórdia de Porto Alegre, Porto Alegre, RS, Brazil.

³ Universidade de Passo Fundo, Passo Fundo, RS, Brazil.

⁴ Pontifícia Universidade Católica do Rio Grande do Sul, Porto Alegre, RS, Brazil.

⁵ Universidade Federal de São Paulo, São Paulo, SP, Brazil.

■ RESUMO

Introdução: A mamoplastia de aumento é o procedimento cirúrgico estético mais realizado nos EUA e o segundo no Brasil. Simastia é uma de suas possíveis complicações. Esta é definida como o mal posicionamento medial dos implantes mamários, que cruzam a linha média, com perda do sulco intermamário. **Métodos:** Trabalho tipo série de casos. Duas pacientes foram submetidas à correção de simastia pós-mamoplastia de aumento. A via de acesso utilizada foi a incisão inframamária prévia. A correção do sulco intermamário foi realizada por escarificação das superfícies anterior e posterior da cápsula, associada a pontos de adesão com fio monofilamentar não absorvível (4 linhas com 6 pontos cada, compreendendo uma faixa vertical de aproximadamente 4 cm de largura na região pré-esternal). Em um dos casos o implante foi recolocado imediatamente e, no outro, em procedimento realizado 3 meses após. **Resultados:** Obtivemos um novo sulco intermamário satisfatório, com adequado resultado estético em ambos os casos. Não se observou recorrência após 9 e 11 meses de observação. **Conclusões:** A abordagem com suturas de adesão para a redefinição do sulco intermamário foi efetiva para o tratamento da simastia pós-mamoplastia de aumento.

Descritores: Implantes de mama; Mamoplastia; Doenças mamárias; Mama; Próteses e implantes.

INTRODUCTION

Breast augmentation is the most commonly performed cosmetic surgery in the United States and second in Brazil and worldwide^{1,2}. Although symmastia might have rare congenital causes, it usually results from a complication of breast augmentation due to incorrect medial placement of implants, which approach too closely or cross the midline, causing intermammary sulcus loss³⁻⁵.

There are no reports in the literature regarding the incidence of iatrogenic symmastia⁵. The diagnosis is essentially clinical. It has a spectrum of intensity of symptoms, from mild cases that go unnoticed to severe cases presenting important psychosocial repercussions.

The main associated factors are excessive dissection of the implant plane toward the sternum, excessive division of the medial insertion of the pectoralis major muscle, use of implants with excessive diameter or volume, congenital symmastia, and presence of lateral anomalous bundles of the pectoralis minor muscle⁴. Some factors can generally be controlled by the surgeon, and iatrogenic symmastia can be prevented through subtle medial dissection, which thereby prevents excessive volume or very close positioning to the midline^{4,6}.

Complications such as seromas, hematomas, infections, or other factors that lead to an increase in the pressure of plane or even a tissue adhesion rupture in the medial region of the plane also increase the risk of symmastia.

OBJECTIVE

To describe the experience and approach for the surgical treatment of iatrogenic symmastia.

CASE REPORT

Work type: case series. Two patients underwent surgical symmastia repair after breast augmentation with implants.

Patient 1

A 28-year-old patient underwent breast augmentation performed by another surgeon with 280-mL high-profile silicone implants (retroglandular) in 2008, and symmastia occurred. In 2009, the same surgeon changed the plane to retromuscular, and the symmastia recurred (Figures 1 and 2).

In 2016, she underwent surgical symmastia repair performed by the senior author of this article. A vertical band on the sternum, approximately 4 cm wide, was drawn (Figure 3). The access route used was the inframammary sulcus, over a previous scar. The implants were removed (Figure 4), and the capsule on its anterior and posterior bands was scarified by electrocautery (power 40, cauterization mode, electrocautery brand Valleylab®).

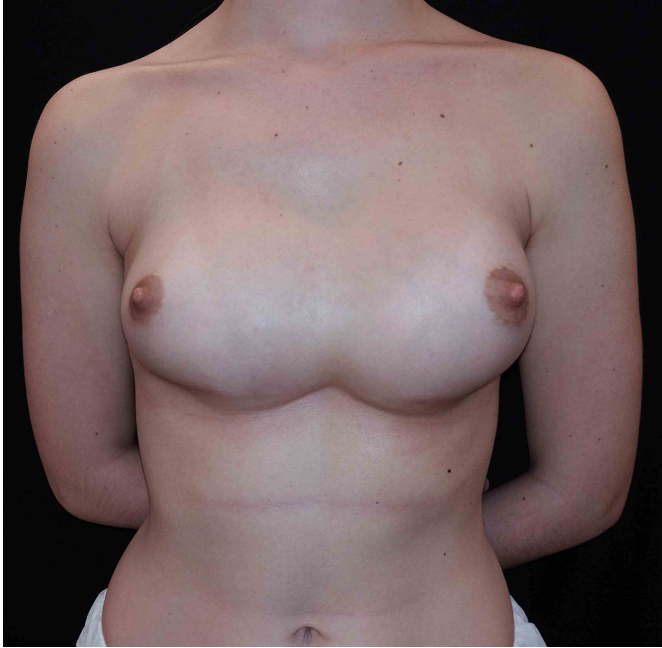

Figure 1. Patient with visible symmastia even in static situation.

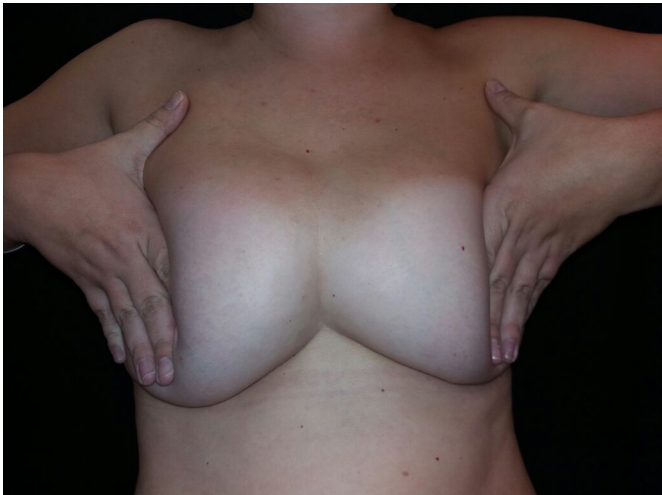


Figure 2. Total loss of the intermammary sulcus in a dynamic maneuver.

Adhesion sutures were made with 3-0 nylon thread between the anterior and posterior capsule surfaces (close to the sternum fascia) (Figure 5). Four lines with 6 sutures each were made, comprising a vertical band approximately 4 cm wide; 420-mL round, super-high-projection implants were inserted in the same plane (Figure 6). Delimitation and separation of the planes was obtained, with an improved positioning of the implants, 60 days post-operatively (Figure 7).

Patient 2

A 19-year-old patient underwent breast augmentation with 300-mL retromuscular, round, high-projection

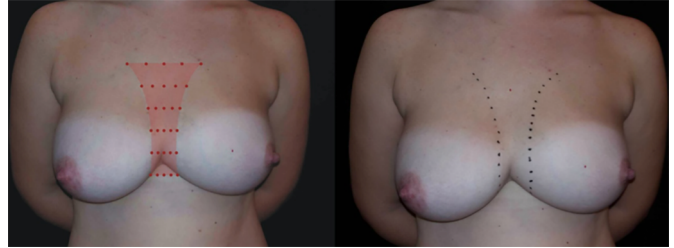

Figure 3. Marking of the region on the sternum.

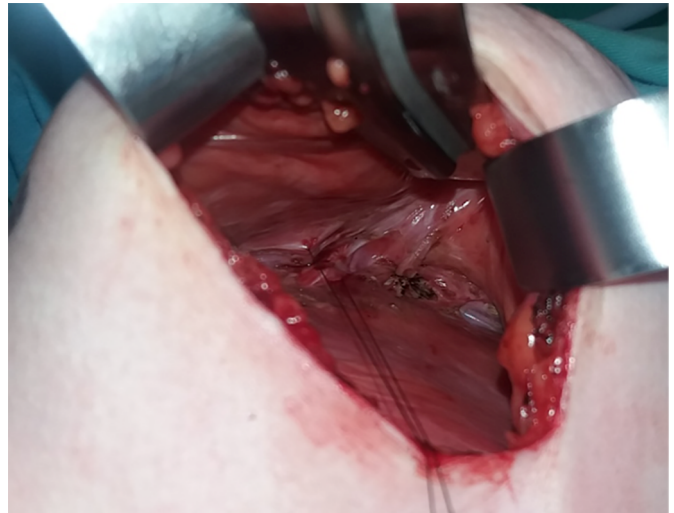

Figure 4. Implant removal, scarification of capsule surfaces, and beginning of adhesion points.

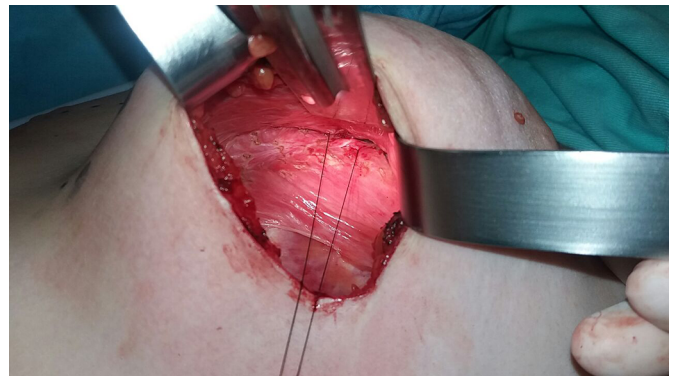


Figure 5. Total closure of the space between the 2 planes.

implants in January 2016. This procedure was performed by the senior author of the article. The patient developed seroma and infection of the surgical site, requiring the removal of the implants. Six months later, after she underwent new breast augmentation, with implants of the same volume and maintaining the retromuscular plane, symmastia occurred (Figure 8).

Computed tomographic examination showed total union of the planes and medialization of the implants (Figure 9). A 2-step approach was proposed: in the first procedure, the implants were removed, with the creation of a new medial sulcus using the same technique

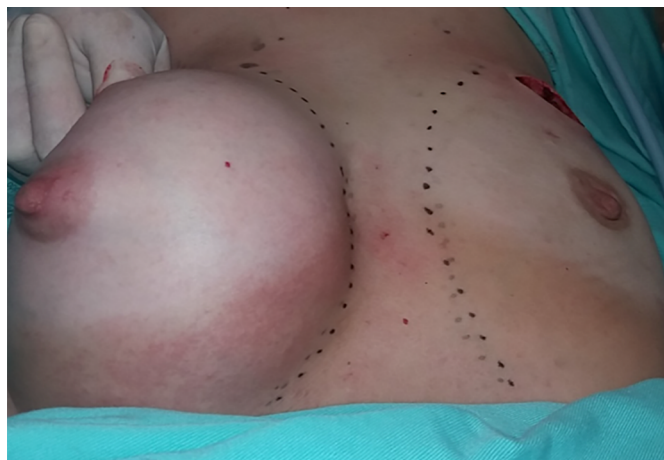

Figure 6. Post-implant placement on the left (superoinferior view). Delimitation of the left area is observed when lateralizing the implant.

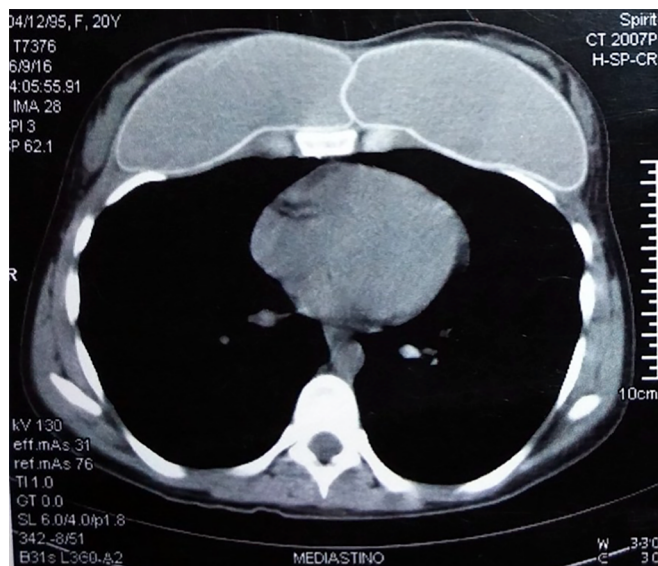


Figure 9. CT scan showing implant plane unification.

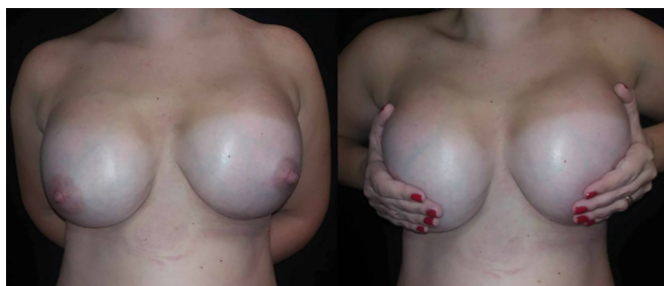

Figure 7. Sixty days after surgery. Properly lateralized implants, despite the maneuver to press them medially.

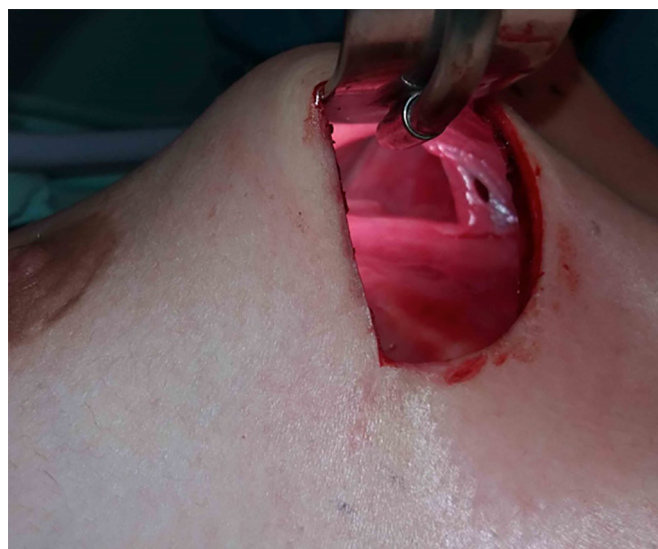

Figure 10. Transoperative. Complete loss of separation between planes.

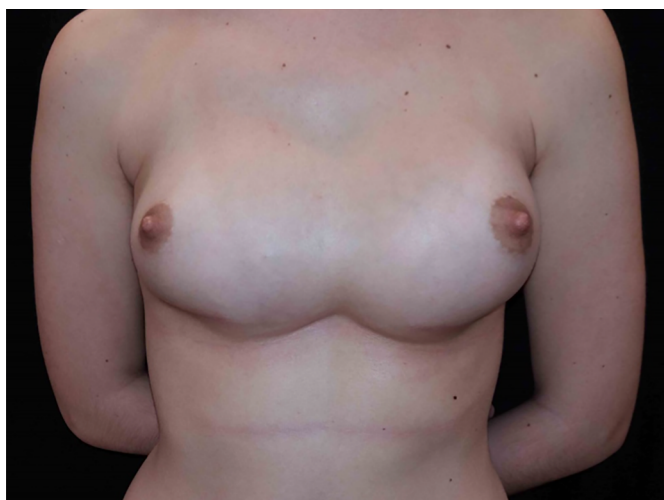

Figure 8. Total loss of the intermammary sulcus after augmentation mammoplasty with implants.

(scarification of the capsule surfaces, creation of a separation band approximately 4 cm between the planes, and creation of adhesion sutures with nylon 3-0 thread) (Figures 10 and 11). After 3 months, 280-mL round, super-high-projection breast implants were placed in the same plane, achieving symmastia repair and appropriate esthetic outcome (Figure 12).

For both patients, there was no recurrence during follow-ups at 9 and 11 months, respectively, for cases 1 and 2.

DISCUSSION

Identification of risk factors for preoperative symmastia and transoperative care are fundamental to avoid symmastia. Medial dissection should not exceed the horizontal distance of 1.5 to 3 cm from the midpoint between the sternum angle and the xiphoid process⁵.

Implants should not have dimensions that are extrapolated, as the literature shows that most symmastia cases are associated with implants with excessive diameter or volume^{4,5,7}. The defect causing symmastia is

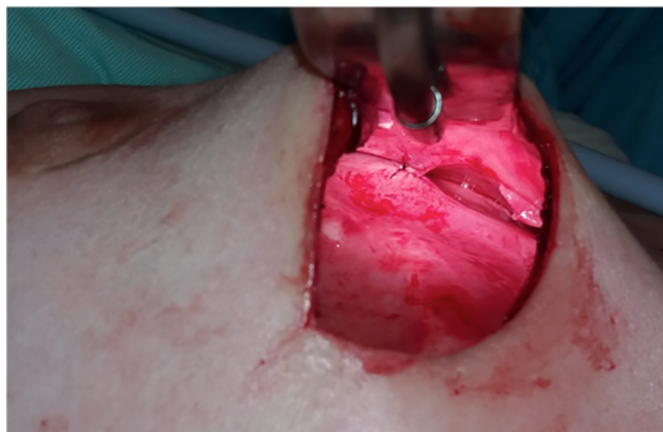


Figure 11. Adhesion points between capsules.

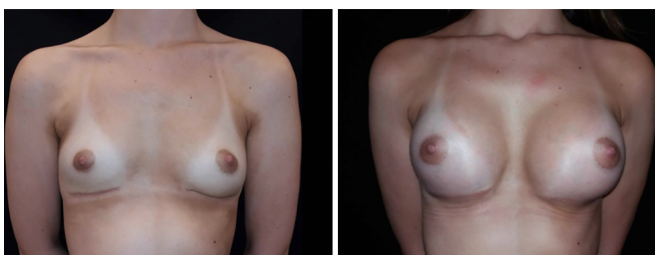


Figure 12. Left: Post-implant removal and generation of the intermammary sulcus. Right: Post-implant replacement (70 days after surgery).

usually found in the central part. Cases of symmastia in the upper and lower parts are rarer⁵.

The diagnosis, in most of the cases, is evident and well defined, within 6 months after the primary procedure. In milder cases, maneuvers such as application of lateral pressure to both implants emphasize their anterior projection in the presternal region^{4,5}. There are few studies in the literature on symmastia, and most of them are case series (Table 1).

Table 1. Articles found in the literature on symmastia.

Author	Year	Journal	Number of cases
Becker	2005	Plastic Reconstructive Surgery	5
Spear	2006	Plastic Reconstructive Surgery	20
Spear et al. ¹³	2009	Plastic Reconstructive Surgery	23
Moliver et al. ⁴	2015	Aesthetic Surgery Journal	18

These works proposed different surgical techniques for the treatment. There is some agreement that the approach should be performed in a periareolar or inframammary manner, depending on the previous

incision, for adequate operative field. Simple capsulorrhaphy may be effective and consists basically of a medial suture between the anterior and posterior edges of medial capsule, but despite its simplicity, its use is not very recommended due to the large number of recurrence cases reported^{7,8}.

Lateral and/or upper capsulotomy may be associated with decreased tension at the medial edge. Another simple surgical option is the use of presternal transcutaneous sutures. Their use is debatable, since the area is at high risk for keloid formation, especially in patients with darker skin tones, despite being recommended to minimize scars in the region.

More complex capsulorrhaphy techniques have been described to decrease the risk of recurrence. Instead of a simple suture, using anterior and posterior flaps that overlap on the medial breast edge, providing greater support, is possible. However, the execution depends on a well-defined and mature capsule^{8,9}. Another option for greater medial support is the use of a C-shaped acellular dermal matrix in the band, which is medially fixed. Such a technique is simple, but it adds cost to the procedure, despite its questionable benefits¹⁰.

Replacing the implant plan can be a treatment strategy. Retroglanular implants can be relocated to the retromuscular plane, providing better implant coverage^{11,12}. Retromuscular implants can be relocated to the retroglanular plane if there is enough subcutaneous coverage⁶.

When there is insufficient coverage, repositioning the implants in an intermediate plane can be attempted. Spear et al.¹³ described good esthetic results in their series of 23 patients with subpectoral implants, which they attributed to the creation of neo-subpectoral regions, a new anterior and posterior plane to the capsule to the pectoralis major muscle, with no cases of recurrence.

Our repair procedure proposal used sutures between the anterior and posterior capsules under the medial sulcus, which is associated with the scarification of their surfaces and results in a good adherence between planes. Since there are no transcutaneous sutures, we avoided the risk of keloid formation. We believe that promoting adhesion between capsule surfaces, i.e., their scarification, is important. Electrocauterization was used with the aim of promoting local inflammation and increasing the possibility of adhesions.

The patient in case 1, who had mammary ptosis, was evaluated for the need for simultaneous mastopexy. Because of the complexity of managing several variables and to prevent the risk of breast devascularization, we chose to correct only symmastia and proposed to perform mastopexy at another time, depending on the need.

We observed that skin adhesion to the presternal region in the medial portion of the breasts and the

creation of a new sulcus reduced excess skin, which we attribute to a mathematical explanation: the skin, in a situation of symmastia detected in a tomographic position (caudo-cranial), forms an almost straight line between the nipples. With symmastia repair, part of the excess skin is used when remaking the correct curvature of the medial poles of the breasts. We also observed a medialization of the areola-papillary complex. Such management proved to be successful and led to good esthetic results, with the patient being satisfied after the first surgery, with no need for a second intervention thus far.

Patient 2 presented with significant psychological impairment, due to 3 unsuccessful surgical interventions. Thus, the maintenance of a good doctor-patient relationship was fundamental for the therapeutic success of the case.

The literature suggests that in certain cases of difficult resolution of symmastia, the removal of the implants is primarily the best option, as it can immediately improve the esthetic aspect, giving the patient the closest semblance to the anatomy she had before breast augmentation¹³. When replacing the implants, we chose to use super-high-projection ones because they have a smaller base diameter, compared with high-projection implants, and thus occupy a smaller horizontal space.

CONCLUSION

Iatrogenic symmastia is a rare condition that has serious repercussions for the patient; hence, its prevention is fundamental. It is difficult to conclude which is the best technique for the correction of this condition because few studies were published, with only a small number of cases. Although our case series is modest, considering that this is a relatively rare condition, we believe the technique we described can be used in the treatment of this condition, which is complex and has a high rate of recurrence.

COLLABORATIONS

- MP** Analysis and/or interpretation of data; statistical analyses; final approval of the manuscript; conception and design of the study; completion of surgeries and/or experiments; writing the manuscript or critical review of its contents.
- FBF** Analysis and/or interpretation of data; statistical analyses; final approval of the manuscript; conception and design of the study; completion of surgeries and/or experiments; writing the manuscript or critical review of its contents.
- EMZ** Analysis and/or interpretation of data; statistical analyses; final approval of the manuscript; conception and design of the study; completion of surgeries and/or experiments; writing the manuscript or critical review of its contents.

- BDMG** Analysis and/or interpretation of data; statistical analyses; final approval of the manuscript; conception and design of the study; completion of surgeries and/or experiments; writing the manuscript or critical review of its contents.
- FMFN** Analysis and/or interpretation of data; statistical analyses; final approval of the manuscript; conception and design of the study; completion of surgeries and/or experiments; writing the manuscript or critical review of its contents.
- LMP** Analysis and/or interpretation of data; statistical analyses; final approval of the manuscript; conception and design of the study; completion of surgeries and/or experiments; writing the manuscript or critical review of its contents.
- RSW** Analysis and/or interpretation of data; statistical analyses; final approval of the manuscript; conception and design of the study; completion of surgeries and/or experiments; writing the manuscript or critical review of its contents.
- PBE** Analysis and/or interpretation of data; statistical analyses; final approval of the manuscript; conception and design of the study; completion of surgeries and/or experiments; writing the manuscript or critical review of its contents.

REFERENCES

1. American Society of Plastic Surgeons [Internet]. American Society of Plastic Surgeons. 2017 [cited 24 May 2017]. Available from: <https://www.plasticsurgery.org>
2. Surgery I. ISAPS - Sociedade Internacional de Cirurgia Plástica Estética (ISAPS) [Internet]. Isaps.org. 2017 [cited 24 May 2017]. Available from: <http://www.isaps.org/pt/>
3. Brown MH, Somogyi RB, Aggarwal S. Secondary Breast Augmentation. *Plast Reconstr Surg*. 2016;138(1):119e-35e. PMID: 27348674 DOI: <http://dx.doi.org/10.1097/PRS.0000000000002280>
4. Moliver CL, Sanchez ER, Kaltwasser K, Sanchez RJ. A Muscular Etiology for Medial Implant Malposition Following Subpectoral Augmentation. *Aesth Surg J*. 2015;35(7):NP203-10. DOI: <http://dx.doi.org/10.1093/asj/sjv072>
5. Selvaggi G, Giordano S, Ishak L. Synmastia: prevention and correction. *Ann Plast Surg*. 2010;65(5):455-61. DOI: <http://dx.doi.org/10.1097/SAP0b013e3181d37648>
6. Lesavoy MA, Trussler AP, Dickinson BP. Difficulties with subpectoral augmentation mammoplasty and its correction: the role of subglandular site change in revision aesthetic breast surgery. *Plast Reconstr Surg*. 2010;125(1):363-71. PMID: 20048627 DOI: <http://dx.doi.org/10.1097/PRS.0b013e3181c2a4b0>
7. Foustanos A, Zavrides H. Surgical reconstruction of iatrogenic symmastia. *Plast Reconstr Surg*. 2008;121(3):143e-144e. PMID: 18317108 DOI: <http://dx.doi.org/10.1097/01.prs.0000300199.69982.48>
8. Yoo G, Lee PK. Capsular flaps for the management of malpositioned implants after augmentation mammoplasty. *Aesth Surg J*. 2010;34(1):111-5. DOI: <http://dx.doi.org/10.1007/s00266-009-9456-3>
9. Parsa FD, Koehler SD, Parsa AA, Murariu D, Daher P. Symmastia after breast augmentation. *Plast Reconstr Surg*. 2011;127(3):63e-65e. PMID: 21364388 DOI: <http://dx.doi.org/10.1097/PRS.0b013e31820635b5>

10. Curtis MS, Mahmood F, Nguyen MD, Lee BT. Use of AlloDerm for correction of symmastia. *Plast Reconstr Surg.* 2010;126(4):192e-193e. DOI: <http://dx.doi.org/10.1097/PRS.0b013e3181ea92a3>
11. Harley OJ, Arnstein PM. Retrocapsular pocket to correct symmastia. *Plast Reconstr Surg.* 2011;128(1):329-31. PMID: 21701362 DOI: <http://dx.doi.org/10.1097/PRS.0b013e3182174661>
12. Parsa FD, Parsa AA, Koehler SM, Daniel M. Surgical correction of symmastia. *Plast Reconstr Surg.* 2010;125(5):1577-9. PMID: 20440189 DOI: <http://dx.doi.org/10.1097/PRS.0b013e3181d513f0>
13. Spear SL, Dayan JH, Bogue D, Clemens MW, Newman M, Teitelbaum S, et al. The "neosubpectoral" pocket for the correction of symmastia. *Plast Reconstr Surg.* 2009;124(3):695-703. PMID: 19363454 DOI: <http://dx.doi.org/10.1097/PRS.0b013e3181a8c89d>

Corresponding author:*Felipe Bilhar Fasolin**

Rua General Lima e Silva, 757, apto 1207 - Cidade Baixa - Porto Alegre, RS, Brazil

Zip Code 90050-101

E-mail: felipefasolin@hotmail.com