



# Evaluation of the effects of radiotherapy on breast reconstruction with a transverse rectus abdominis myocutaneous flap

## *Avaliação da influência da radioterapia nas reconstruções de mama com TRAM*

MARCELA CAETANO CAMMAROTA <sup>1,2</sup>  
MARINA DE SOUZA BORGATTO <sup>1,2\*</sup>  
JOÃO PEDRO PONTES CAMARA FILHO <sup>1,2</sup>  
DIOGO BORGES PEDROSO <sup>1</sup>  
RICARDO CINTRA JÚNIOR <sup>1</sup>  
BRUNO PEIXOTO ESTEVES <sup>1,2</sup>  
DHYEGO MOLINARI DE CASTRO  
CURADO <sup>1,2</sup>

Institution: Hospital Daher,  
Brasília, DF, Brazil.

Article received: March 31, 2013.  
Article accepted: May 17, 2018.

Conflicts of interest: none.

DOI: 10.5935/2177-1235.2018RBCP0090

### ■ ABSTRACT

**Introduction:** Radiation negatively influences the results of breast reconstruction using implants. However, the effects of radiation on breast reconstruction with autologous tissue is still unclear. The objective of this study was to evaluate the postoperative complications in patients who underwent immediate and late breast reconstruction with a transverse rectus abdominis myocutaneous (TRAM) flap and statistically correlate these complications with the use of radiotherapy (RT). **Methods:** A retrospective survey of the medical records of patients who underwent breast reconstruction was conducted. Of the patients, 126 underwent breast reconstruction with a TRAM flap between 2004 and 2011. The presence or absence of RT and postoperative complications in the immediate and late reconstructions was assessed. The patients were divided into 3 groups as follows: 1) without RT (TRAM alone group), 2) TRAM→RT group, and 3) RT→TRAM group. The patients in each group were evaluated for the presence and absence of minor and major complications, and results were statistically analyzed. **Results:** The groups were considered homogenous for age and body mass index. The incidence of major complications was higher in the groups with RT after TRAM (29.6%) than in the other groups, namely the groups without RT (23.4%) and with RT before TRAM flap reconstruction (5.6%). However, the differences among the groups were not statistically significant. No evidence of statistically significant differences in minor complications were found among the groups. **Conclusion:** In this study, adjuvant RT was not a potentiating factor of complications in the patients who underwent immediate reconstruction with a TRAM flap after mastectomy.

**Keywords:** Breast surgery; Breast cancer; Surgical flap; Radiotherapy.

<sup>1</sup> Sociedade Brasileira de Cirurgia Plástica, São Paulo, SP, Brazil.

<sup>2</sup> Hospital Daher, Brasília, DF, Brazil.

## ■ RESUMO

**Introdução:** A radiação influencia negativamente os resultados das reconstruções de mama que utilizam implantes. No entanto, os efeitos da radiação sobre as reconstruções de mama apenas com tecidos autólogos ainda não está clara. O objetivo do trabalho é avaliar as complicações pós-operatórias de pacientes submetidas à reconstrução de mama com retalho do músculo reto abdominal (TRAM) imediato e tardio e correlacionar estatisticamente essas complicações com a presença ou não da radioterapia (RT). **Métodos:** Levantamento retrospectivo de prontuários de pacientes submetidas à reconstrução mamária, das quais 126 pacientes realizaram reconstrução mamária com TRAM no período de 2004 a 2011. Foram analisadas a presença ou não de RT e as complicações pós-operatórias nas reconstruções imediatas e tardias. As pacientes foram divididas em 3 grupos: 1) sem RT (somente TRAM), 2) (TRAM→RT), 3) (RT→TRAM). Para cada grupo foi avaliada a presença e ausência de complicações menores e maiores e aplicados testes estatísticos. **Resultados:** Os grupos estudados foram considerados homogêneos quanto a idade e índice de massa corporal. Houve maior incidência de complicações maiores nos grupos com RT após o TRAM (29,6%) em relação aos demais grupos: sem RT (23,4%) e RT antes do TRAM (5,6%). Entretanto, a diferença entre os grupos não se mostra estatisticamente significativa. Para as Complicações Menores, também não há evidências de diferenças estatisticamente significativas entre os grupos. **Conclusão:** Nesse estudo a radioterapia adjuvante não se mostrou como fator potencializador de complicações nas pacientes submetidas à reconstrução imediata com TRAM pós-mastectomia.

**Descritores:** Mama/cirurgia; Câncer de mama; Retalhos cirúrgicos; Radioterapia.

## INTRODUCTION

Since Hartrampf introduced it for the first time, in 1982, the transverse rectus abdominis myocutaneous (TRAM) flap with a transverse skin island has become one of the most popular breast reconstruction techniques<sup>1</sup>.

The surgical options currently available for breast reconstruction involve the use of autologous tissue, alone and in combination with implants, or the use of prostheses and/or expanders only. The choice is based individually on the characteristics and preferences of patients, the indication of adjuvant therapies, and the experience of the physician<sup>2</sup>.

The use of radiotherapy (RT) in the treatment of breast cancer reduces the risk of locoregional recurrence and provides increased survival, and may be used in combination with surgery as an adjuvant postoperative treatment<sup>3,4</sup>.

Radiotherapy is an integral part of the multidisciplinary approach for breast cancer. The recent literature has highlighted the significant role of RT in high- and intermediate-risk patients. However, the combination

of RT with reconstruction in post-mastectomy patients continues to be a matter of controversy<sup>3,4</sup>.

It is generally well accepted that radiation negatively influences the results of breast reconstruction with implants. In the longer term, however, the effects of radiation on the outcome of breast reconstruction with autologous tissue are still unclear<sup>3</sup>.

## OBJECTIVE

The objective of this study was to evaluate the postoperative complications in patients who underwent breast reconstruction (immediate and late) with a TRAM flap and statistically correlate these complications with the presence or absence of RT.

## METHODS

A retrospective survey was conducted of the medical records of 424 patients who underwent breast reconstruction after mastectomy for the treatment of breast cancer. Of the patients, 126 underwent immediate

or late breast reconstruction with a TRAM flap between 2004 and 2011. We analyzed the presence or absence of RT and postoperative complications in the immediate and late reconstructions.

Complications were divided into minor (hematoma, seroma, epidermolysis, dehiscence, and localized infection that are not related to RT) and major (complete or partial flap necrosis and localized steatonecrosis, defined as fat calcifications that do not compromise the skin, measuring up to 3 cm on clinical examination). In this study, RT was considered related to the onset of major complications. Possible complications in the donor area were not accounted for in this survey.

The patients were divided into 3 groups as follows: 1) patients who underwent only immediate or late reconstruction with a TRAM flap without RT (TRAM alone group), 2) patients who underwent mastectomy with immediate breast reconstruction followed by RT (TRAM→RT group), and 3) patients who underwent mastectomy + RT and, subsequently, late breast reconstruction (RT→TRAM group). Each group was evaluated for the presence and absence of minor and major complications.

All the reconstructions were performed by a single plastic surgeon, always using the same surgical technique and accompanied during this period by the same surgeon. A vacuum drain was used in the breast and abdomen in all the patients. The medications and postoperative guidelines were all standardized. Closure of the abdomen was always performed with a Prolene mesh. Smokers and patients who had undergone the first phase of the reconstruction by other medical staff were excluded.

The chi-square and Games-Howel statistical tests were applied, and the results were considered significant when the *p* value was <0.05.

## RESULTS

Of the 126 patients whose medical records were evaluated, 92 who underwent breast reconstruction with the TRAM technique were selected for the study (after application of the exclusion criteria). The following 3 patient groups were analyzed: without radiation (*n* = 47), with radiation after TRAM flap reconstruction (*n* = 27), and with radiation before TRAM flap reconstruction (*n* = 18). The patients included in the study were between

35 and 80 years of age (mean [SD]: 55.81 [9.162] years). The body mass index (BMI) was between 23 and 35 kg/m<sup>2</sup> (mean [SD]: 28.16 [3.387] kg/m<sup>2</sup>). The groups were considered homogeneous regarding age (*p* = 0.123) and BMI (*p* = 0.775), as shown in table 1. The mean follow-up period of the patients was 20 months.

**Table 1.** Descriptive Statistics based on Age and BMI of Patients.

	Minimum	Maximum	Mean	Standard Deviation	Sig. ANOVA between Groups
BMI	23	35	28.16	3.387	0.123
Age	35	80	55.81	9.162	0.775

BMI: Body Mass Index; ANOVA: Analysis of Variance.

The surgical technique used was the ipsilateral reconstruction with a TRAM flap in 98.9% of the cases. One patient underwent contralateral reconstruction because the patient had a Kocher incision on the same side of the mastectomy (1.1%). Three patients underwent microsurgical free TRAM flap reconstruction.

For the analysis, the complications were divided into two types, minor (not related to RT) and major (may be related to RT). The incidences of these types of complications were determined to assess if the presence of RT and its effects before and after reconstruction influenced the incidence of minor and major complications, as shown in Table 2.

The incidence of major complications was higher in the groups with RT after TRAM flap reconstruction (29.6%) (Figure 1) than in the other groups (without RT, 23.4% (Figure 2) and with RT before TRAM flap reconstruction, 5.6%) (Figure 3). However, the differences among the groups were not statistically significant in the chi-square test. Multiple comparisons were made among the groups (Games-Howel test), and no significant difference was found at a significance level of 5%.

Similarly, we found no evidence of statistically significant differences among the groups for minor complications, although a higher incidence was observed among the patients with RT before TRAM flap reconstruction (38.9%) than among those who had no RT (21.3%) and had post-TRAM flap reconstruction RT (29.6%). The multiple comparisons with the Games-Howel

**Table 2.** Number of Patients with Bilateral Reconstruction per Group.

	Group						Sig. Kruskal-Wallis	
	Without Radiation		With Radiation after TRAM		With Radiation before TRAM			
	N	%	N	%	N	%		
Bilateral	Yes	6	12.8	4	14.8	0	0	0.250
	No	41	87.2	23	85.2	18	100	
	Total	47	100	27	100	18	100	

TRAM: Transverse Rectus Abdominis Myocutaneous.

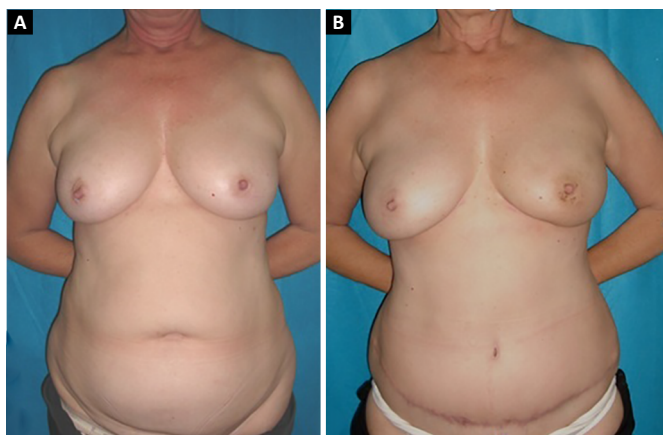


Figure 1. A: Preoperative image; B: Postoperative image of breast reconstruction with TRAM flap bilaterally followed by radiotherapy in the left breast.

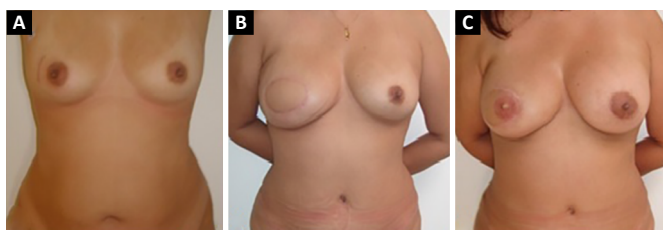


Figure 2. A: Preoperative image; B: Postoperative image of breast reconstruction with TRAM flap in the right breast; C: Postoperative image of the breast after the second reconstruction phase without radiotherapy.

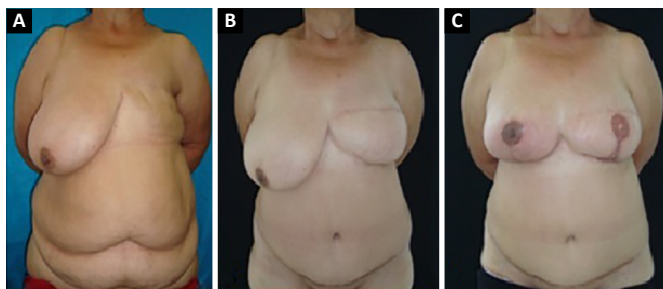


Figure 3. Late TRAM flap. A: Postoperative image after radiotherapy; B: Postoperative image of breast reconstruction with TRAM flap; C: Postoperative image of the breast after the second reconstruction phase.

test also showed no significant differences between the groups. Figures 4 and 5 illustrate these results.

### DISCUSSION

Adjuvant RT improves the prognosis of patients with advanced breast cancer, whose risk of locoregional recurrence is >25-30%<sup>2</sup>. The American Society for Therapeutic Radiology and Oncology and the American Society of Clinical Oncology recommend post-mastectomy RT for patients with advanced disease (T3 or T4 tumors) or patients who underwent levels I, II, and/or III axillary emptying and had at least four positive axillary lymph nodes.

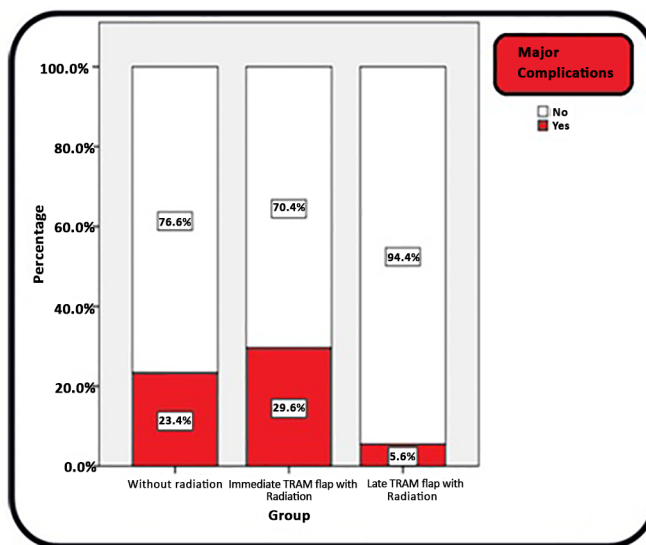


Figure 4. Incidence of major complications per group.

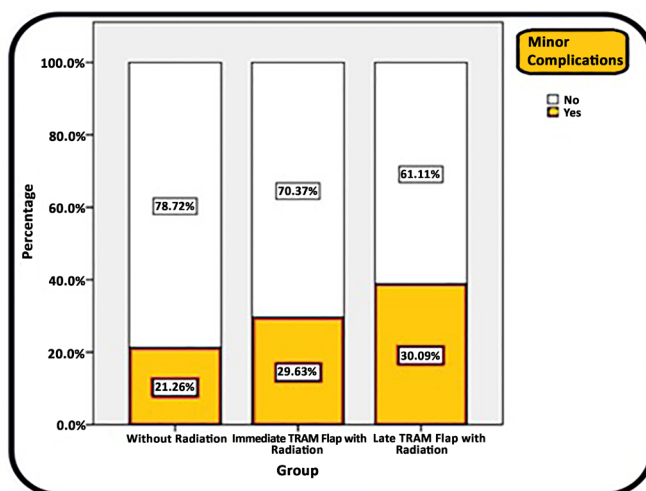


Figure 5. Incidence of minor complications per group.

However, the role of adjuvant radiotherapy in the treatment of patients with T1 or T2 tumors and 1-3 positive axillary lymph nodes is controversial<sup>2</sup>. Adjuvant RT in patients with locoregional disease is generally not recommended for women with tumors of <5 cm in diameter and negative axillary lymph nodes<sup>4,5</sup>.

Obesity and smoking are the most important factors that interfere with the final result with regard to complications<sup>6</sup>. In our study, smoking was an exclusion factor, and BMI was homogeneous among the 3 groups.

According to Jugenburg et al.<sup>5</sup>, RT administered before or after breast reconstruction has the potential to negatively affect the form, symmetry, and pigmentation, and to increase the incidence of contractures in reconstructed breasts. In our study, the breasts reconstructed with TRAM and irradiated before or after reconstruction were not adversely affected by RT.

Some authors reported that the association between reconstruction with a TRAM flap and RT, regardless of the sequence of these procedures, produced a similar rate of complications and aesthetic results<sup>7</sup>. Williams et al.<sup>8</sup> demonstrated no significant difference in the overall incidence of complications between the irradiated groups, either before or after reconstruction (31% vs. 25%,  $p = 0.749$ ). In our sample, similar results were observed. On the other hand, other authors reported a higher incidence of late complications in the immediate reconstruction group than in the late reconstruction group<sup>9,10</sup>.

In 2001, researchers from M. D. Anderson published a retrospective study that compared complication rates between patients who underwent immediate reconstruction with a TRAM flap before RT and those who underwent late reconstruction after RT. The incidence of early complications did not differ significantly between the two groups. However, the incidence of late complications (steatonecrosis, loss of flap volume, and flap contracture) was significantly higher in the immediate reconstruction group (87.5% vs. 8.6%;  $p < 0.001$ )<sup>3,11</sup>.

The present study shows that although late complications are more prevalent in the immediate reconstruction group, the difference between the groups is not statistically significant.

## CONCLUSION

In this study, adjuvant RT was not a potentiating factor of complications in the patients who underwent immediate reconstruction with a TRAM flap after mastectomy. Moreover, no statistically significant difference was found in the occurrence of minor and major complications among the different patient groups.

## COLLABORATIONS

- MCC** Analysis and/or interpretation of data; final approval of the manuscript; conception and design of the study; completion of surgeries and/or experiments; writing the manuscript or critical review of its contents.
- MSB** Analysis and/or interpretation of data; final approval of the manuscript; writing the manuscript or critical review of its contents.

- JPPCF** Analysis and/or interpretation of data; writing the manuscript or critical review of its contents.
- DBP** Statistical analyses; final approval of the manuscript.
- RCJ** Writing the manuscript or critical review of its contents.
- BPE** Writing the manuscript or critical review of its contents.
- DMCC** Writing the manuscript or critical review of its contents.

## REFERENCES

- Kim EK, Eom JS, Ahn SH, Son BH, Lee TJ. Evolution of the pedicled TRAM flap: a prospective study of 500 consecutive cases by a single surgeon in Asian patients. *Ann Plast Surg.* 2009;63(4):378-82.
- Leonardi MC, Garusi C, Santoro L, Dell'Acqua V, Rossetto F, Didier F, et al. Impact of medical discipline and observer gender on cosmetic outcome evaluation in breast reconstruction using transverse rectus abdominis myocutaneous (TRAM) flap and radiotherapy. *J Plast Reconstr Aesthet Surg.* 2010;63(12):2091-7.
- Kronowitz SJ, Robb GL. Radiation therapy and breast reconstruction: a critical review of the literature. *Plast Reconstr Surg.* 2009;124(2):395-408.
- Recht A, Edge SB, Solin LJ, Robinson DS, Estabrook A, Fine RE, et al. Postmastectomy radiotherapy: clinical practice guidelines of the American Society of Clinical Oncology. *J Clin Oncol.* 2001;19(5):1539-69.
- Jugenburg M, Disa JJ, Pusic AL, Cordeiro PG. Impact of radiotherapy on breast reconstruction. *Clin Plast Surg.* 2007;34(1):29-37.
- Mélega JM, Baroudi R. Radioterapia mamária. In: Mélega JM. *Cirurgia Plástica, Fundamentos e Arte.* Rio de Janeiro: Medsi; 2003. p. 92-5.
- Soong IS, Yau TK, Ho CM, Lim BH, Leung S, Yeung RM, et al. Post-mastectomy radiotherapy after immediate autologous breast reconstruction in primary treatment of breast cancers. *Clin Oncol (R Coll Radiol).* 2004;16(4):283-9.
- Williams JK, Bostwick J 3rd, Bried JT, Mackay G, Landry J, Benton J. TRAM flap breast reconstruction after radiation treatment. *Ann Surg.* 1995;221(6):756-64.
- Alderman AK, Wilkins EG, Kim HM, Lowery JC. Complications in postmastectomy breast reconstruction: two-year results of the Michigan Breast Reconstruction Outcome Study. *Plast Reconstr Surg.* 2002;109(7):2265-74.
- Spear SL, Ducic I, Low M, Cuoco F. The effect of radiation on pedicled TRAM flap breast reconstruction: outcomes and implications. *Plast Reconstr Surg.* 2005;115(1):84-95.
- Tran NV, Chang DW, Gupta A, Kroll SS, Robb GL. Comparison of immediate and delayed free TRAM flap breast reconstruction in patients receiving postmastectomy radiation therapy. *Plast Reconstr Surg.* 2001;108(1):78-82.

\*Corresponding author:

**Marina de Souza Borgatto**

SMHN Quadra 02, Bloco C, Edifício Dr. Crispim, Sala 1315 - Brasília, DF, Brazil

Zip Code: 70710-149

E-mail: mborgatto@yahoo.com.br