



Surgical treatment of 510 patients with highly active antiretroviral therapy-associated lipodystrophy

Tratamento cirúrgico de 510 pacientes portadores de lipodistrofias secundárias ao uso de antirretrovirais

GERALDO ANTONIO ESTANISLAU
SCOZZAFAVE^{1,2*}

CYNTHIA SOUZA MARTINS²

CAMILA MAYA KUNISAWA²

MARIA MANOELA CARDOSO DA SILVA
MEYER²

DALTO ANTÔNIO VIGANÓ PASTRO²

RICARDO MARTIM BIANCO^{1,2}

JORGE LUIZ ABEL^{1,2}

JUVÊNCIO JOSÉ DUAILIBE FURTADO²

Institution: Study performed at the Hospital
Heliópolis, São Paulo, SP, Brazil.

Article received: March 24, 2014.
Article accepted: December 13, 2014.

DOI:10.5935/2177-1235.2015RBCP0112

■ ABSTRACT

Introduction: The treatment of acquired immunodeficiency syndrome has undergone important advances since the introduction of highly active antiretroviral therapy (HAART). This treatment led to the elimination of the virus in the bloodstream and increased survival; however, metabolic and structural changes became evident. One of these changes is lipodystrophy, the redistribution of body fat. With one of the largest samples worldwide, the aim of this work was to present some of the various surgical alternatives as well as the results obtained for minimizing the impact of lipodystrophy. **Method:** From July 2005 to July 2013, 510 patients with HAART-associated lipodystrophy underwent surgery in the Clinic of Plastic Surgery, Heliópolis Hospital. All patients submitted to prior clinical and immunological assessments made with the aid of the infectious diseases team. The present study was approved by the Research Ethics Committee of the ABC Foundation. **Results:** The 510 patients included 335 women and 175 men with an age range of 16-74 years. Liposuction of the cervicodorsal fat pad (buffalo hump) was predominant (199 cases). With regard to the response stimulated through a subjective questionnaire, a high degree of satisfaction was observed with a significant increase in self-esteem and greater adherence to antiretroviral treatment. **Conclusion:** The surgical correction of body lipodystrophy demonstrably improves the aesthetics of patients using HAART; however, its psychological and social effects are even more important since self-esteem increases and stigma decreases, which leads to better adherence to antiretroviral treatment.

Keywords: Lipodystrophy; HIV infections; Serodiagnosis of AIDS; Lipectomy; Body composition.

¹ Serviço de Cirurgia Plástica “Dr. Wilson Andreoni”, São Paulo, SP, Brazil.

² Hospital Heliópolis, São Paulo, SP, Brazil.

■ RESUMO

Introdução: O tratamento da Síndrome da Imunodeficiência Adquirida vem sofrendo importantes avanços desde a introdução da terapia antirretroviral altamente ativa, conhecida como HAART (*high active antirretroviral therapy*). Este tratamento levou à eliminação do vírus na corrente sanguínea e ao aumento na sobrevida, entretanto alterações metabólicas e estruturais tornaram-se evidentes. Uma dessas alterações é a redistribuição de gordura corpórea, também denominada lipodistrofia. Com uma das maiores casuísticas mundiais, o objetivo deste trabalho é demonstrar algumas das alternativas cirúrgicas, bem como os resultados obtidos na tentativa de minimizar o impacto da lipodistrofia. **Método:** No período de julho de 2005 a julho de 2013, 510 pacientes portadores de lipodistrofia secundária ao uso de HAART foram operados pela Clínica de Cirurgia Plástica do Hospital Heliópolis. Todos esses pacientes foram submetidos à prévia avaliação clínica e imunológica, sob auxílio da equipe de Infectologia. O presente trabalho foi aprovado pelo Comitê de Ética em Pesquisa da Fundação do ABC. **Resultado:** Dentre os 510 pacientes, 335 eram do sexo feminino e 175 do sexo masculino, com idades variando entre 16 e 74 anos. Quanto aos procedimentos, destacou-se lipoaspiração da giba e dorso, com 199 casos. Quanto à resposta estimulada através de questionário subjetivo, observou-se elevado grau de satisfação, aumento significativo da autoestima e maior adesão ao tratamento antirretroviral. **Conclusão:** A correção cirúrgica da lipodistrofia corporal comprovadamente melhora o aspecto estético do paciente que faz uso da HAART; porém, o efeito psicológico e social é ainda mais importante, elevando a autoestima, com diminuição dos estigmas, e proporcionando uma maior adesão ao tratamento antirretroviral.

Descritores: Lipodistrofia; Infecções por HIV; Sorodiagnóstico da AIDS; Lipectomia; Composição corporal.

INTRODUCTION

Acquired immunodeficiency syndrome (AIDS) has undergone major epidemiological and clinical changes, since its initial description in 1981, mainly because of the introduction of highly active antiretroviral therapy (HAART), in 1998. This new therapeutic arsenal was responsible for a significant reduction in morbidity and mortality of individuals infected with the human immunodeficiency virus (HIV), drastically changing the natural evolution of the disease observed to that point. This therapy led to a significant and sustained viral load reduction as well as improved quality of life and survival rates; however, metabolic and physical changes also occur that can lead to acquired body deformities that were otherwise irrelevant¹⁻³.

Lipodystrophy, a change in body fat distribution, causes the accumulation of fat in the back, cervical, and intra-abdominal regions as well as a reduction in adipose tissue in other regions such as the face, limbs, and buttocks¹.

To minimize the psychological and social consequences of lipodystrophy, pharmaceutical and surgical treatments have been proposed, the latter of which have proven more effective to date⁴.

OBJECTIVE

With one of the largest samples worldwide, this study presents some of the various surgical alternatives as well as the results obtained in an attempt to minimize the impact of HAART-associated lipodystrophy.

METHOD

All patients were studied according to the principles of the Declaration of Helsinki and the Nuremberg Code in compliance with the Standards for Research Involving Human Beings (Res. CNS 196/96) of the National Health Council after project approval was granted by the Heliópolis Hospital and the Committee

for Ethics in Research of the Universidade Federal do ABC.

Retrospective and cohort study. From July 2005 to July 2013, 510 patients with HAART-associated lipodystrophy underwent surgery in the Plastic Surgery Clinic, Heliópolis Hospital. All patients underwent prior clinical and immunological evaluation with the assistance of the Infectious Diseases team of Heliópolis Hospital.

All patients were retrospectively evaluated. As part of the routine, all patients who underwent any surgical procedure signed the Free and Informed Consent statement (Appendix 1) for surgery, which included aspects regarding participation in scientific studies.

Any clinically balanced patient who was unhappy with his or her body image due to HAART-associated lipodystrophy for at least 12 months was included in this study. Clinical and/or immunologically decompensated patients were excluded and directed to the services of origin to be compensated. Immunologically, the patients needed to present with CD4 levels >350 cells/mm³, a viral load $<10,000$ copies/mL, and stability for 6 months in accordance with the Ministry of Health services⁵.

Surgical treatment was chosen in accordance with the clinical manifestations and the patient's main complaint. In certain cases, imaging methods such as computed tomography aided in the diagnosis and surgical planning process.

The correction of facial atrophy was performed with polymethylmethacrylate (Metacrill®)-based filling. This treatment was not considered surgical; therefore, it was not the objective of this study.

Lipoaccumulation was treated mainly with the manual assisted liposuction technique using a vacuum liposuction aspirator or vibro-assisted liposuction since the fat is thicker than that in non-infected individuals, especially in the dorsal region (cervicodorsal and lumbodorsal regions). It was occasionally necessary to resect the excess skin, mainly in the abdomen and arms (Figure 1).

In cases of abdominal lipodystrophy with significant adipose accumulation (Figure 2), abdominal dermolipectomy was indicated and generally associated with liposuction of the upper portion of the abdomen according to the techniques of Callia⁶ and Saldanha et al.⁷. A computed tomography scan of the abdomen was performed to exclude intra-abdominal lipoaccumulation; in such cases, surgery was not indicated because the result would be unsatisfactory.

The correction of buttock hypotrophy was accomplished using specific prostheses for the region provided by Silimed devices (®) using the XYZ of Gonzalez technique (Figure 3). In some cases, with less hypotrophy, liposuction of the back and flank was indicated along with fat grafting in the buttocks^{8,9}.

Surgical corrections involving the face and cervical region were performed with techniques used in the middle and lower thirds of facial lifting and resection of the excess pre- and infra-auricular skin with ladder

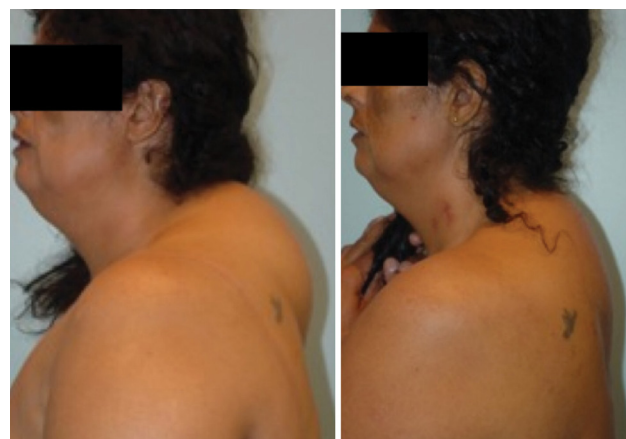

Figure 1. E.P., a 54-year-old woman. Pre- and post-operative liposuction of the cervicodorsal fat pad.

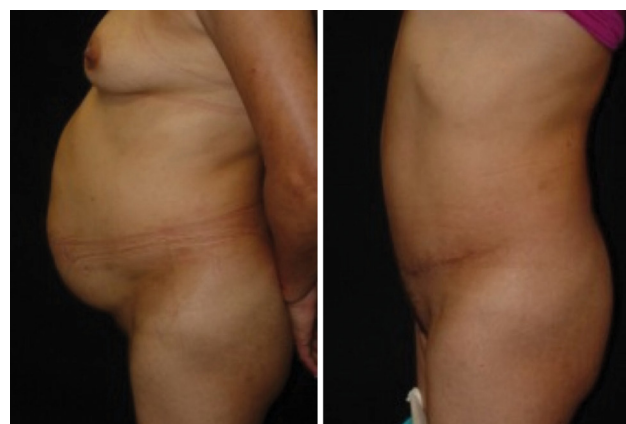


Figure 2. A.R.S., a 43-year-old woman. Pre- and post-operative dermolipectomy with abdominal liposuction.

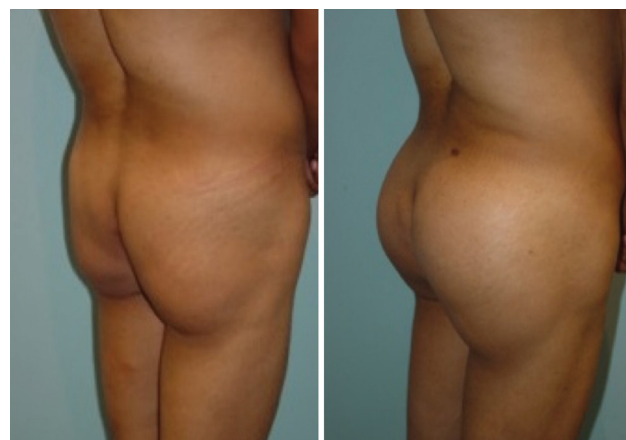

Figure 3. A.A.O., a 38-year-old woman. Pre- and post-operative view of the buttocks (including an implant).

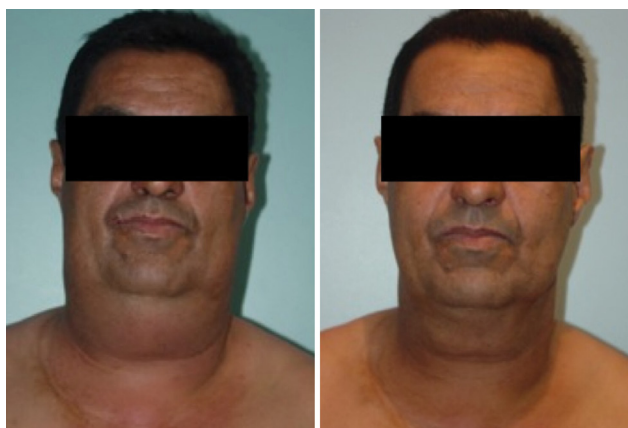

Figure 4. A. M. S., a XX-year-old man. Pre and post-operative liposuction of the chin associated with a facelift of the middle and lower thirds of the face.

plication of the superficial musculoaponeurotic system (Figure 4). Special attention was given to the lower cervical region, in which fat accumulation and accentuated flaccidity were important patient complaints. The correction in this region was performed with liposuction, followed by median platysmal plication¹⁰.

A questionnaire was used (Appendix 2) with each patient to quantify the degree of satisfaction with therapy.

RESULTS

Among the 510 patients evaluated, 335 were women and 175 were men 16-74 years of age (Table 1). Liposuction of the cervicodorsal fat pad (buffalo hump) was predominant (199 cases), followed by the inclusion of gluteal prosthesis (88 cases) and abdominal dermolipectomy (60 cases) (Table 2).

Regarding the response obtained through a subjective questionnaire (Appendix 2), we observed a high degree of satisfaction with the results obtained with the surgeries as well as a significant increase in self-esteem and a greater adherence to antiretroviral treatment.

DISCUSSION

Although highly efficient, HAART plus HIV leading to the appearance of toxicity in the long term that was not previously observed has become one of the most important problems in the treatment of AIDS^{1,4}.

Some of the changes found include impaired metabolism (hypertriglyceridemia, hypercholesterolemia, increased insulin resistance); increased cardiovascular risk; psychological and sexual disorders; kidney diseases; bone changes; and body lipodystrophy^{2,4}.

Table 1. Sex and age (years).

Total number of patients	Women		Men	
510	335		175	
Age (mean)	16-30	31-40	41-50	51-74
	22	153	213	122

Table 2. Type of surgical procedure performed.

Surgery performed	Total	Male	Female
Liposuction of cervicodorsal fat pad	199	85	114
Inclusion of gluteal prosthesis	88	42	46
Liposuction + abdominal dermolipectomy	60	05	55
Abdominal liposuction	36	08	28
Liposuction of chin/face	32	13	19
Correction of gynecomastia	20	20	-
Liposuction of flanks	13	01	12
Reduction mastoplasty	10	-	10
Rhytidoplasty/ cervicoplasty	09	05	04
Liposuction of the torso/chest	08	03	05
Liposuction of the arms	07	-	07
Breast prostheses	02	-	02
Inclusion of prostheses in the thighs	01	-	01
Other procedures	25		
Total	510	175	335

The incidence of HAART-associated lipodystrophy is 25-50% but may reach 84%¹.

The role of various drugs used in HAART in relation to the development of lipodystrophy is not yet fully clarified. Several studies indicate that nucleoside analogue reverse transcriptase inhibitors have a major role in the genesis of peripheral lipodystrophy, while the IPs act on the accumulation of visceral fat and the changes related to metabolic syndrome. More recent studies, however, have also demonstrated a correlation with lipodystrophy in patients using non-nucleoside reverse transcriptase inhibitors. HIV itself may also contribute to this syndrome^{1,4}.

The main complaints were facial hypertrophy and the accumulation of fat in certain areas of the body, more frequently the cervicodorsal region, which causes the greatest stigma in patients and leads to greater social exclusion and lower self-esteem.

Liposuction alone was the most commonly performed procedure due to body lipoaccumulation. Compared to liposuction in uninfected patients, those with HIV exhibit quite dense fatty tissue, indicating a need for greater physical strength and, therefore, more caution in regions susceptible to injuries to internal organs. There is also the risk of residual lipoaccumulation due to technical difficulties in this procedure, which requires more surgical steps in addition to the inherent possibility of recurrence since the causal relationship is continuous (chronic use of antiretroviral therapy).

Regarding the complaint of gluteal hypotrophy, unfortunately only partial correction is possible. The techniques used (fat grafting and implant) aim to obtain functional improvement for clothing support (pants) and a more pronounced gluteal projection. However, it is not possible to improve the support and pressure on the ischial regions characterized by sitting. This report is more common in men and in cases of accentuated gluteus lipoatrophy. The layer of fat that protects the bony projections is very small or even non-existent in some cases.

Atrophy of the inner thighs can be corrected with fat grafts; however, as the deformities are accentuated and a portion of the fat is reabsorbed, this correction has unsatisfactory results. There was one case of implant placement in this location with an aesthetically favorable outcome.

In the treatment of the abdominal region, liposuction was performed with abdominal dermolipectomy. In the interim, it should be emphasized that patients with intra-abdominal fat accumulation diagnosed using computed tomography were excluded. Liposuction is necessary in the hypogastric regions and flanks for better body contour as well as abdominoplasty with median plicatures, although the diastasis of the abdominal rectus muscle is not the main cause of the deformity. Based on the patients' responses to the questionnaire, it was possible to observe that the acceptance of surgical treatment is high, while some underwent different procedures in different body regions.

It is not difficult to imagine that a disease that significantly changes one's body image affects an individual's personal and social life, leading to a higher rate of depression and anxiety than in those who are not affected by the syndrome. Because of these changes, these patients have a higher perception of body change, greater social isolation, and a lower level of satisfaction with antiretroviral treatment. This situation would lead to a reduction in adherence to the anti-HIV drug treatment. Thus, reconstructive plastic surgery in these subjects is used as mechanism among other benefits to aid in drug therapy maintenance.

CONCLUSION

The surgical correction of body lipodystrophy demonstrably improves the aesthetic appearance of patients on HAART; however, its psychological and social effects are even more important since they increase self-esteem, decrease stigma, and result in greater adherence to antiretroviral treatment.

ACKNOWLEDGMENTS

We thank the patients who consented to the reporting of their post-operative results and personal satisfaction. We are grateful for Heliópolis Hospital, which provided the infrastructure for our work. We thank Dr. Wilson Andreoni, regent of this service, for the stimulus to continue studying and acquire new knowledge. We emphasize that the work of our esteemed Secretary Rosana Brum is of fundamental importance since it makes our ambulatory procedures more organized and effective.

REFERENCES

1. Furtado JJD, Zambrini H, Jordão D NO, Scozzafave GA, Brasileiro RF. Ambulatório de lipodistrofia do Hospital Heliópolis: uma experiência com as correções cirúrgicas em dois anos de atendimento. *Prát Hosp*. 2007;58(28):28-32.
2. Nelson L, Stewart KJ. Psychological morbidity and facial volume in HIV lipodystrophy: quantification of treatment outcome. *J Plast Reconstr Aesthet Surg*. 2012;65(4):439-47. <http://dx.doi.org/10.1016/j.bjps.2011.11.024>. PMID:22153841.
3. Singhanian R, Kotler DP. Lipodystrophy in HIV patients: its challenges and management approaches. *HIV AIDS (Auckl)*. 2011;3:135-43. PMID:22267946.
4. Kosmiski L, Kuritzkes D, Hamilton J, Sharp T, Lichtenstien K, Hill J, et al. Fat distribution is altered in HIV-infected men without clinical evidence of the HIV lipodystrophy syndrome. *HIV Med*. 2003;4(3):235-40. <http://dx.doi.org/10.1046/j.1468-1293.2003.00151.x>. PMID:12859322.
5. Brasil. Ministério da Saúde. Portaria conjunta nº 2 de 27 de março de 2007. Anexo IV. Legislações conjunta. Diretrizes de indicação para tratamento de lipodistrofia em portadores HIV/ Aids [Internet]. 2007 [acesso em 2014 Março 24]. Disponível em: <http://www.brasilsus.com.br/legislacoes/conjuntas/9005-2.html>
6. Callia WEP. Contribuição para o estudo da correção cirúrgica do abdome em pendulo e globoso: técnica original [Tese]. São Paulo: Universidade de São Paulo, Faculdade de Medicina; 1965.
7. Saldanha OR, De Souza Pinto EB, Mattos WN JR, Pazetti CE, Lopes Bello EM, Rojas Y, et al. Lipoabdominoplasty with selective and safe undermining. *Aesthetic Plast Surg*. 2003;27(4):322-7. <http://dx.doi.org/10.1007/s00266-003-3016-z>. PMID:15058559.
8. Gonzalez R. Augmentation gluteoplasty: the XYZ method. *Aesthetic Plast Surg*. 2004;28(6):417-25. <http://dx.doi.org/10.1007/s00266-004-3130-6>. PMID:15633021.

9. Gonzalez R. Buttocks reshaping: posterior contour surgery. A step-by-step approach. Rio de Janeiro: Indexa; 2006.

10. Stuzin JM. MOC-PSSM CME article: face lifting. *Plast Reconstr Surg.* 2008;121(1 Supl):1-19. <http://dx.doi.org/10.1097/01.prs.0000294656.92618.2b>. PMID:18182954.

***Corresponding author:**

Geraldo Antonio Estanislau Scozzafave

Avenida Engenheiro Luís Gomes Cardim Sangirardi, 607 – São Paulo, SP, Brazil

Zip Code 04112-080

E-mail: scozza@uol.com.br

Appendix 1. FREE AND INFORMED CONSENT FORM.

PROJECT TITLE: SURGICAL TREATMENT OF PATIENTS WITH HIGHLY ACTIVE ANTIRETROVIRAL THERAPY-ASSOCIATED LIPODYSTROPHY

Responsible Researcher: Dr. Geraldo Antônio Estanislau Scozzafave

Dear participant:

You have been selected to participate in the study entitled “**Surgical treatment of patients with highly active antiretroviral therapy-associated lipodystrophy.**” This project will be performed in the Heliópolis Hospital Complex in Sao Paulo (SP) by physicians of this service and aims to demonstrate some of the various surgical alternatives as well as the results obtained in an attempt to minimize the impact of lipodystrophy in patients who are chronically using highly active antiretroviral therapy.

The stored database will be a source for studies, research, and publications for scientific meetings and scientific journals with the objective of analyzing the efficacy and reproducibility of the performed treatments. The treatments performed by the Clinic of Plastic Surgery, Heliópolis Hospital, are based on and supported by the literature and current clinical practice. The following procedures will be performed: collection and storage of data in the medical records and surgical reports as well as photos of the pre-, intra-, and post-operative periods.

During the execution of the project, these data will remain under the care of the Clinic of Plastic Surgery, Heliópolis Hospital, and confidentiality and ethical care will be maintained according to the code of medical ethics.

The risks that could be involved in this study – if the personal data of the participants in the study were not preserved – would be moral damage that leads to stigma. To prevent these risks, no data will be published that would allow patient identification. The benefit of this project would be its evaluation of the effectiveness of surgical treatment for the well-being of patients with HAART-associated lipodystrophy.

Participant (or guardian, if under 18 years)

Responsible researcher

If you have doubts or questions about this study, please contact Dr. Geraldo Antônio Estanislau Scozzafave at Rua Cônego Xavier, 276 Sacomã, São Paulo-SP, or by phone at (11) 2274-7600. If you have any doubts or questions about your rights as a participant in this study or are dissatisfied with the way in which the study is being conducted, please contact the Ethics Committee in Research of the Faculdade de Medicina do ABC, Avenida Príncipe de Gales, 821, 1º Andar - Prédio CEPES, Santo André-SP, or by phone at (11) 4993-5453. The Ethics Committee is responsible for evaluating and monitoring the ethical aspects of all research involving human beings to ensure the protection, dignity, rights, safety, and well-being of the research subjects.

After reading and receiving explanations about the research, I, the patient, will be entitled to:

1. Receive answers to any question and clarifications about the procedures, risks, benefits, and other study-related aspects.
2. Withdraw my consent at any time and cease participating in the study.
3. Not be identified and be assured that my privacy will be maintained.

Continue...

Continuation...

I declare that, after being properly informed by the researcher and understanding what was explained to me, I consent to participate in this research project and authorize the publication of photos that respect my identity and privacy.

Sao Paulo, _____ of _____ of _____

Name of the participant (or guardian, if under 18 years):

RG: _____ Sex: _____ Date of birth: _____

Address: _____ Phone: _____

Signature: _____

I, _____ (name of Researcher), declare that I provided all of the information related to the project to the participant (and guardian, as applicable).

Date: ____/____/____

Appendix 2. Questionnaire.

Surgical results	Good	Reasonable	Bad		
Would you undergo another surgical procedure?	Yes	No			
Do you want to continue with the HIV treatment?	Yes	No			
From 1 to 5 (poor to excellent), how do you grade the surgery?	1	2	3	4	5