



Rupture of a silicone breast implant after firearm injury

Perfuração de prótese de silicone de mama por projétil de arma de fogo

Leandro Vicentino Fregadolli¹
 Ricardo Sestito Proto²
 Rafael De Souza Moraes²
 Decio Luiz Portella²
 Hamilton Aleardo Gonella³

ABSTRACT

The rupture of silicone implants for injury due gunshot is rare with only two cases reported, and only one implant was done with gel high-cohesive. A male patient, 25 years transsexual with breast implants silicone, was the victim of gunshot wound. The bullet penetrated the posterior chest and get off at the anterior-medial chest which transfixated the prosthesis. During digital exploration of the wound, still at the surgical emergency, it was found the rupture of the implant, taking place however only the simple suture of the skin. It was performed ultrasonography, computed tomography and magnetic resonance imaging exam, the results showed no perforation of the prosthesis and silicone leakage. Faced with the assertion of the general surgeon that had perforation of the implant, it was indicated the immediate removal of the prosthesis, but the patient refused to be operated by evading the hospital. After two months he had hyperemia and the silicone leaked out of the wound. Then he looked for a particular service to exchange the prosthesis. We can conclude that despite of the high specificity of current imaging studies, the artificial high-density silicone may be presented without modification to examinations and their removal is the treatment of choice.

Keywords: Prosthesis. Breast. Silicones. Rupture. Wounds, gunshot.

RESUMO

A ruptura do implante de silicone devido à ferimento por arma de fogo é um evento raro, com apenas dois casos descritos na literatura, sendo que somente em um deles o implante era feito com gel de alta coesão. Paciente masculino, 25 anos, transexual, com prótese mamária de silicone, vítima de ferimento por arma de fogo, sendo que o projétil entrou na região dorsal e saiu através da região antero-medial direita do tórax, transfixando a prótese. Durante a exploração digital do ferimento da mama, ainda no centro cirúrgico da emergência, foi constatada a ruptura do implante, realizando-se, no entanto, somente a sutura simples da pele. Realizadas ultrassonografia, tomografia computadorizada e ressonância

Work performed in Pontifícia Universidade Católica (PUC-SP), Campus Sorocaba. Sorocaba, SP, Brasil.

Article received: 23/02/2011
 Article accepted: 23/03/2011

1. Aspiring member of the SBCP – Resident of Plastic Surgery of PUC-SP, Campus Sorocaba, Department of Plastic Surgery Linneu Mattos Silveira .
2. Aspiring member of the SBCP – Plastic Surgery Trainee at PUC-SP. Campus Sorocaba, Department of Plastic Surgery Linneu Mattos Silveira .
3. Full member of SBCP – Head of the Plastic Surgery Service, PUC-SP, Department of Plastic Surgery Linneu Silveira Mattos.

magnética; nenhum exame demonstrou perfuração da prótese e extravasamento do silicone. Diante da afirmação do cirurgião geral que havia perfuração do implante, foi indicada ao paciente a remoção imediata da prótese, no entanto, o paciente recusou ser operado, deixando o hospital. Após dois meses, evoluiu com hiperemia e saída de silicone pela ferida da mama, quando procurou serviço particular para troca da prótese. Podemos concluir que, apesar da alta especificidade dos atuais exames de imagem, as próteses de alta densidade de silicone podem apresentar-se sem alteração aos exames e sua remoção é o tratamento de escolha.

Descritores: Prótese. Mama. Silicone. Ruptura. Ferimentos por arma de fogo.

CASE REPORT

A 25-year-old transsexual man with silicone breast implants presented with a firearm injury. The bullet had entered the dorsal region and exited through the right anteromedial region of the thorax, transfixing the prosthesis. The patient underwent emergent surgery in the emergency department that was performed by a general surgeon because of the involvement of other organs consisting of lesions of the right kidney, liver, diaphragm, and right lung. Digital assessment of the breast injury in the operating room indicated implant rupture; however, only a simple skin suture was performed (Figure 1).

The plastic surgery team assessed the case the next day, at which time imaging studies were requested. Ultrasonography, computed tomography, and MRI showed no perforation of the prosthesis or silicone leakage (Figure 2).

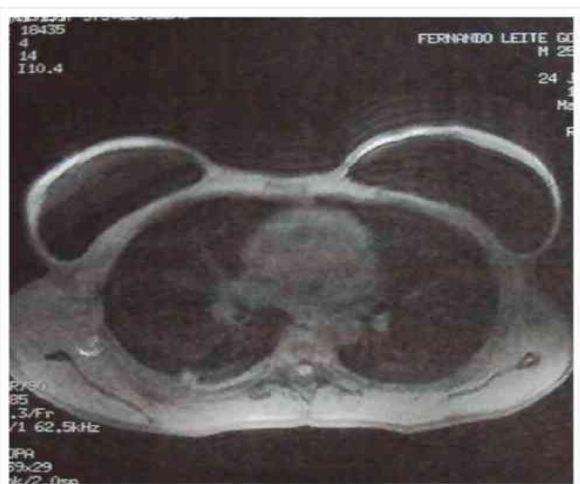

Figure 1 - Image of the bullet wound in the right breast .

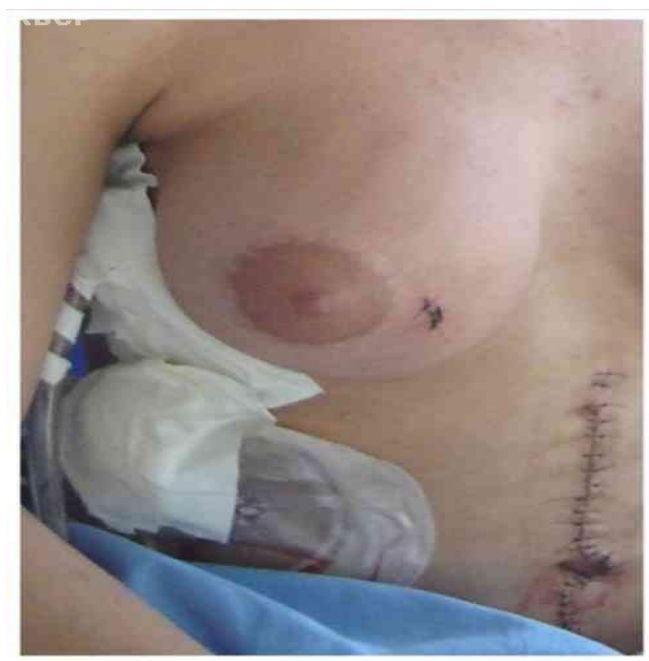


Figure 2 - Cross-sectional magnetic resonance image showing no perforation of the silicone prosthesis.

Since the general surgeon stated that there had been an implant perforation, immediate removal of the prosthesis was recommended to the patient. However, the patient refused to undergo surgery and left the hospital. Two months later, he developed hyperemia and presented with silicone leakage through the breast wound when searching for a private service for prosthesis replacement.

DISCUSSION

Silicone gel implants are used for breast reconstruction after mastectomy and to increase breast size or remodel breast shape for aesthetic reasons⁵. Although rupture is a well-known complication of breast implant surgery, little is known about rupture adaptation and frequency⁶.

The major complication of a silicone pros-

thesis rupture is leakage of the gel and its effects on the body⁷. Migration, fibrosis, granulation, and ulceration can be caused by silicone leakage⁸. The use of cohesive gel prostheses has reduced the frequency of gel extravasation due to rupture⁹. In two reports described in the literature, the implant was removed immediately with washing, drainage of the implant pocket, and delayed breast reconstruction, which prevented the consequences of silicone gel migration. Delayed breast reconstruction is important to treat the potentially contaminated injury with greater safety if one opts for a new prosthesis³.

MRI has been established as the technique with the highest specificity and sensitivity (>90%) to detect silicone implant rupture^{4,8}. Silicone implant rupture may be divided into intracapsular and extracapsular (80–90%). In traumatic ruptures, extracapsular tearing occurs because the fibrous capsule surrounding the implant ruptures⁴. The main feature of extracapsular disruption is macroscopic leakage of silicone that is easily visualized with MRI⁴. In the case reported here, we did not observe silicone leakage or rupture of the fibrous capsule as reported in the literature⁴.

Extracapsular rupture of third-generation implants is characterized by the absence of silicone extravasation beyond the fibrous capsule, which can be difficult to observe on imaging studies as demonstrated with our patient. Nevertheless, even with these prostheses, after traumatic rupture, gel extrusion and leakage may occur as evidenced in this case.

We conclude that despite the high specificity of current imaging methods, ruptured high-density silicone prostheses can appear normal and without alterations. Because of the potential complications, even without silicone leakage, prosthesis removal is the treatment of choice after rupture^{1,2,5}.

CONCLUSION

Podemos concluir que, apesar da alta especificidade dos atuais exames de imagem, as próteses de alta densidade de silicone podem apresentar-se sem alteração aos exames. Devido as possíveis complicações, mesmo sem o extravasamento do silicone, a remoção da prótese é o tratamento de escolha nas rupturas^{1,2,5}.

**Leandro Vicentino Fregadolli,
Rua André Rodrigues Benavides, 101/104,
Campolim
CEP 18048-050 Sorocaba, SP, Brazil**

REFERENCES

- 1- Graf R, Auersvald A, Biggs T. Mamoplastias de aumento: problemas e soluções. In: Mélega JM, Baroudi R, eds. Cirurgia plástica - fundamentos e arte: cirurgia estética. São Paulo: Medsi; 2003. p.591-607.
- 2- LaTrenta GS. Breast augmentation. In: Rees TD, LaTrenta GS, eds. Aesthetic plastic surgery. Philadelphia: WB Saunders; 1994. p.1003-49.
- 3- Pereira LH, Sterodimas A. Rupture of high-cohesive silicone implant after gunshot injury. *Ann Plast Surg.* 2007;58(2):228-9.
- 4- Gorczyca DP, Gorczyca SM, Gorczyca KL. The diagnosis of silicone breast implant rupture. *Plast Reconstr Surg.* 2007;120(7 Suppl 1):49S-61S.
- 5- Silverman BG, Brown SL, Bright RA, Kaczmarek RG, Arrowsmith-Lowe JB, Kessler DA. Reported complications of silicone gel breast implants: an epidemiologic review. *Ann Intern Med.* 1996;124(8):744-56.
- 6- Brown SL, Silverman BG, Berg WA. Rupture of silicone-gel breast implants: causes, sequelae, and diagnosis. *Lancet.* 1997;350(9090):1531-7.
- 7- Phillips JW, de Camara DL, Lockwood MD, Grebner WC. Strength of silicone breast implants. *Plast Reconstr Surg.* 1996;97(6):1215-25.
- 8- Kubota J, Fujino T, Sugimoto C, Abe T. Long term complications caused by injected silicone gel and paraffin oil. *Keio J Med.* 1984;33(3):127-36.
- 9- Brown MH, Shenker R, Silver SA. Cohesive silicone gel breast implants in aesthetic and reconstructive breast surgery. *Plast Reconstr Surg.* 2005;116(3):768-79.