

Assessing patient satisfaction after breast reconstruction

Avaliação do grau de satisfação de pacientes submetidas a reconstrução mamária

FELIPE GAMA E COLOMBO¹

ABSTRACT

Background: Detection of breast cancer coupled with mastectomy negatively affects patients' emotional state. The psychosocial effect is a distortion of body image, including decreased femininity, sexuality, and quality of life. Breast reconstruction can be performed at different times using different techniques, improving the comfort and quality of life of these patients. **Method:** This was a retrospective study of 16 female patients who underwent breast reconstruction between October 2008 and October 2011. The following parameters were analyzed: age, complications, techniques, time of reconstruction, adjuvant therapies (i.e., chemotherapy and radiotherapy), and satisfaction with reconstruction. Data were collected through chart reviews, and patient satisfaction with the procedure was measured using a specific questionnaire. **Results:** Among the 16 patients, 15 (93.75%) reported being very satisfied, and the remaining 1 patient (6.25%) was somewhat satisfied; no patient reported dissatisfaction after reconstruction; the 1 patient who reported being somewhat dissatisfied had not completed all stages of breast reconstruction. **Conclusions:** Despite the small sample size, the results indicate that reconstruction positively affected the quality of life of patients undergoing mastectomy, regardless of the technique or time chosen for reconstruction, resulting in a high degree of satisfaction with a change in body contouring.

Keywords: Breast neoplasms. Mastectomy. Mammoplasty. Tissue expansion devices. Myocutaneous flap.

RESUMO

Introdução: A descoberta do câncer de mama, aliada à mastectomia, impacta negativamente no estado emocional da paciente, cujo efeito psicossocial é uma distorção da imagem corporal, com piora na feminilidade, sexualidade e qualidade de vida. A reconstrução mamária pode ser realizada em diferentes tempos e por meio de diversas técnicas, trazendo conforto e melhora da qualidade de vida dessas pacientes. **Método:** Foi realizado estudo retrospectivo de 16 pacientes do gênero feminino submetidas a reconstrução de mama no período entre outubro de 2008 e outubro de 2011. Foram observados os seguintes parâmetros: idade, presença de complicações, técnicas, tempo de reconstrução, terapias adjuvantes (quimioterapia e radioterapia) e grau de satisfação com a reconstrução. Os dados foram levantados por meio de revisão de prontuário e da satisfação das pacientes com o procedimento mensurada por questionário específico. **Resultados:** As pacientes muito satisfeitas representaram 93,75% dos casos (15 pacientes) e as 6,25% restantes (1 paciente) apresentaram-se pouco satisfeitas. Nenhuma paciente relatou insatisfação após a reconstrução. A paciente que relatou estar pouco satisfeita ainda não concluiu todos os estágios da reconstrução mamária. **Conclusões:** Apesar da pequena amostra de pacientes, a reconstrução impacta positivamente na qualidade de vida das pacientes submetidas a mastectomia, independentemente da técnica e do tempo escolhido para essa reconstrução, trazendo elevado grau de satisfação com a alteração do contorno corporal.

Descritores: Neoplasias da mama. Mastectomia. Mamoplastia. Dispositivos para expansão de tecidos. Retalho miocutâneo.

Work performed at the Santa Casa de Misericórdia de Vitória, Vitória, ES, Brazil.

Submitted to SGP (Sistema de Gestão de Publicações/Manager Publications System) of RBCP (Revista Brasileira de Cirurgia Plástica/Brazilian Journal of Plastic Surgery).

Article received: 24/7/2012
Article accepted: 4/2/2013

1. Member of the Brazilian Society of Plastic Surgery, plastic surgeon, Santa Casa de Misericórdia de Vitória, Vitória, ES, Brazil.

INTRODUCTION

Breast cancer is the most common cancer and leading cause of cancer-related death in women. According to the WHO, there are more than 1,050,000 new cases of breast cancer per year worldwide. Since 1990, the incidence of this cancer has increased in developed countries including the United States, Canada, and the UK; however, this has been associated with reduced mortality due to early detection through appropriate screening programs. Meanwhile, in developing countries such as Brazil, both the incidence and mortality of breast cancer are increasing as a result of delayed diagnosis and implementation of appropriate therapy^{1,2}.

The treatment of breast cancer is highly dependent upon the clinical stage and histological type. Surgical intervention is the mainstay of treatment and may be accompanied by axillary lymphadenectomy and adjuvant therapies (i.e., chemotherapy and radiotherapy). Surgical treatment includes conservative modalities such as quadrantectomy and skin-sparing mastectomy as well as other non-conservative modalities, mainly modified radical mastectomy³.

Both the time of reconstruction and the technique used should be individualized with respect to age, stage, proposed cancer treatment, body type, and preferences of the patient and surgeon^{4,5}.

The technique selected for reconstruction should be discussed with the patient, including all the advantages and disadvantages. The most commonly used techniques are reconstructions using autologous tissues (i.e., myocutaneous or microsurgical flaps) and alloplastic materials.

There are 3 standard techniques discussed in the literature: transverse rectus abdominis muscle (TRAM) flap, latissimus dorsi flap, and reconstruction with alloplastic materials (i.e., expanders or implants). All 3 methods usually provide good results and have a low incidence of reoperation if the choice meets the abovementioned criteria and is discussed with the patient⁵.

According to Ananthakrishnan et al.⁶, the main factor that influences the choice of the time of reconstruction is the need for radiotherapy. Patients with confirmed or suspected indications for radiation therapy in the postoperative period benefit from delayed reconstruction owing to the increased rate of complications such as capsular contracture and extrusion when alloplastic material is used and volume reduction with flap retraction when autologous tissue is used^{6,7}.

Thus, breast reconstruction is another chapter in the life of patients with breast cancer, who in addition to living with their diagnosis, which by itself has psychosocial consequences, must also endure mastectomy—a body-mutilating procedure. In this traumatic scenario, increasing survival is not the sole purpose of treatment; breast reconstruction helps patients recover their body image and improves vitality, femininity, sexuality, well-being, and the quality of life⁸.

METHOD

This single-center retrospective study was conducted between October 2008 and October 2011.

The study was approved by the Ethics and Research Committee Santa Casa de Misericórdia de Vitória, Vitória, ES, Brazil.

Sixteen female patients aged between 30 and 55 years underwent modified radical mastectomy and reconstruction in the aforementioned period. All patients had invasive ductal carcinoma; 8 patients each (50%) were diagnosed with cancer in the right and left breasts.

The patients underwent breast reconstruction using TRAM flap, latissimus dorsi muscle flap associated with the inclusion of silicone implants, and expanders with subsequent replacement with silicone implants. Fourteen (87.5%) reconstructions were delayed, and 2 (12.5%) were immediate.

All patients who underwent breast reconstruction with TRAM flap underwent the monopedicled technique with contralateral rectus abdominis muscle with abdominal wall closure using Marlex[®] mesh (Figure 1).

Patients undergoing breast reconstruction with latissimus dorsi flap had their donor site closed with adhesion stitches and vacuum drainage using textured silicone implants (Figures 2–4).

The reconstructions using expanders were performed via a pocket created with the pectoralis major serratus anterior. The size of the expander used in all patients in this series was 500 mL. The expansion started after 1 month of inclusion, and the exchange for the corresponding implant was scheduled for 2 weeks after the last expansion.

The technique was selected according to the following criteria: biotype, radiation therapy, comorbidities, and the

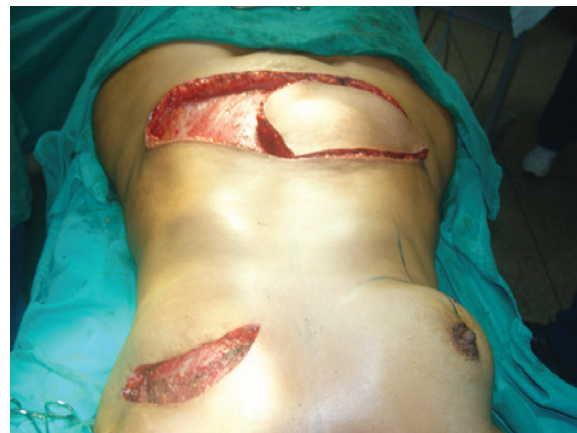

Figure 1 - Intraoperative appearance of breast reconstruction with monopedicled transverse rectus abdominis muscle flap showing the dissected flap ready to be rotated.

patient's desire. Thus, patients with abdominal donor sites, few or no comorbidities, and the desire for reconstruction with TRAM flap were operated on after guidance about the advantages and disadvantages of the technique. Patients without abdominal donor site, those who did not want reconstruction with use of the rectus abdominis, or those with 2 or more comorbidities underwent breast reconstruction with latissimus dorsi muscle flap or expanders depending on the presence or absence of radiation therapy, respectively.

Assessment of Satisfaction

One year after breast reconstruction, patients were evaluated for the presence of postoperative complications and the degree of satisfaction after reconstruction. Satisfaction was classified as "very satisfied," "somewhat satisfied," or "dissatisfied." The concept of satisfaction was directed toward the patients' physical and psychosocial well-being.

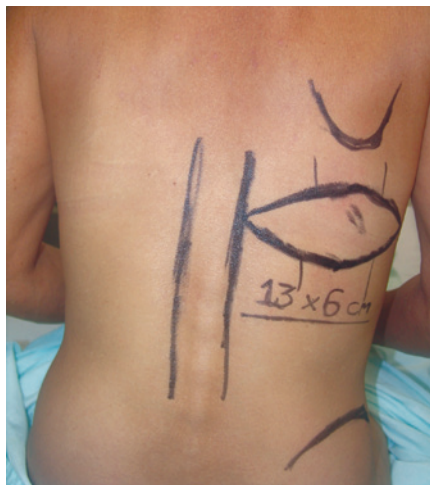

Figure 2 - Preoperative marking of the latissimus dorsi muscle flap.

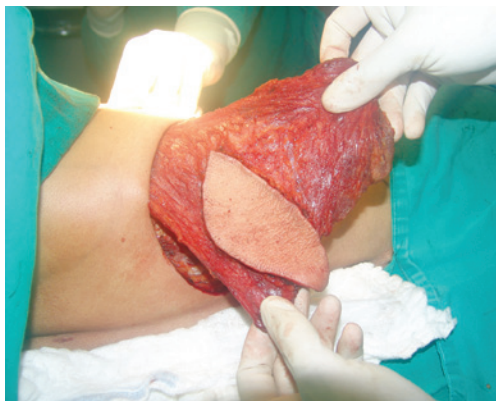

Figure 3 - Dissected latissimus dorsi flap.

RESULTS

Among all breast reconstructions in this series, 10 (62.5%), 2 (12.5%), and 4 (25%) were performed using TRAM flap, latissimus dorsi muscle flap with silicone implant, and the cutaneous breast expander procedure with subsequent replacement by a permanent implant (Figure 5).

The body mass index of the patients ranged between 17.7 and 34.7, with a mean of 25.2. Only 1 (6.25%) patient reported being a smoker.

Regarding comorbidities, 3 (18.75%) patients had systemic hypertension and 1 (6.25%) had diabetes mellitus; all of them had comorbid drug control during breast reconstruction.

Among all 16 patients, 15 (93.75%) underwent a second breast reconstruction procedure; 87.5% underwent symmetrization of the contralateral breast. Meanwhile, 31.25% of patients underwent a third procedure, mainly nipple-areola complex reconstruction.

Ten complications were observed in the studied patients; complications occurring up to and after postoperative day 30 were defined as early and late complications, respectively.

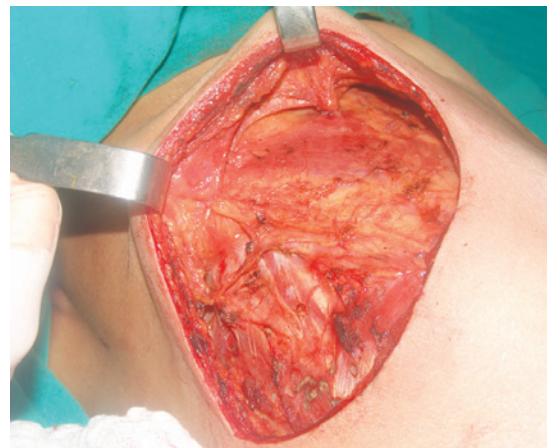


Figure 4 - Points of adhesion in the donor area.

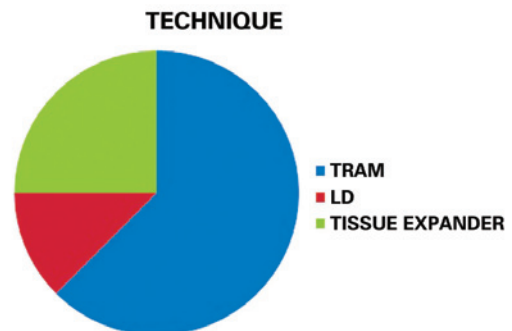


Figure 5 - Techniques used for breast reconstruction. LD = latissimus dorsi flap;

TRAM = transverse rectus abdominis myocutaneous flap.

Figure 6 presents the main complications in the present patient series.

The majority (80%) of these complications occurred in patients undergoing TRAM flap reconstruction. Abdominal hematoma occurred in 1 case on day 7 postoperatively that necessitated surgical intervention with appropriate treatment; this patient had hypertension, which was controlled with antihypertensive medication at the time. Necrosis was partial and subjected to resection with primary suturing. Steatonecrosis-related complications were treated with tissue resection in the subsequent surgical procedure. The other 2 complications that prompted complaints about unsightly scarring occurred in patients who underwent breast reconstruction with latissimus dorsi muscle flap. No complications interfered with the end results after treatment.

Regarding satisfaction, 15 of 16 patients (93.75%) reported being very satisfied with the postoperative results as well as improved quality of life and social interaction. One patient (6.25%) was somewhat satisfied; this partial satisfaction was clarified as a result of the failure to complete the reconstruction, as she did not undergo nipple–areola complex reconstruction.

Figures 7–13 illustrate some cases in the present series.

DISCUSSION

Breast reconstruction restores the self-esteem, femininity, and sexuality of patients undergoing mastectomy while minimizing psychosocial damage and trauma related to body image. Although many techniques are applicable, this report focuses on breast reconstruction with TRAM flap, latissimus dorsi flap with implant, and the use of tissue expanders with subsequent replacement with silicone implant.

These 3 techniques are well established and have been compared in many studies with respect to the degree of satisfaction after breast reconstruction. Kalaaji & Bruheim⁹ report no differences among these 3 techniques with respect to the improvement in the quality of life. Moreover, the

majority of patients recommended the surgery they had undergone at the end of treatment.

Craft et al.¹⁰ found similar complication rates between unilateral and bilateral reconstructions; however, for unilateral reconstructions, the greatest satisfaction was obtained

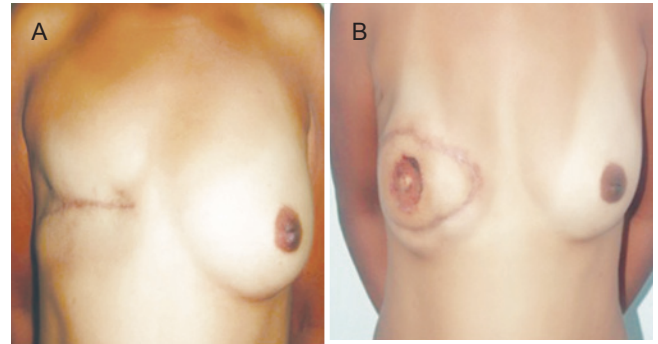


Figure 7 - In A, Preoperative appearance of transverse rectus abdominis muscle flap (TRAM) reconstruction. In B, Postoperative appearance of TRAM flap reconstruction.

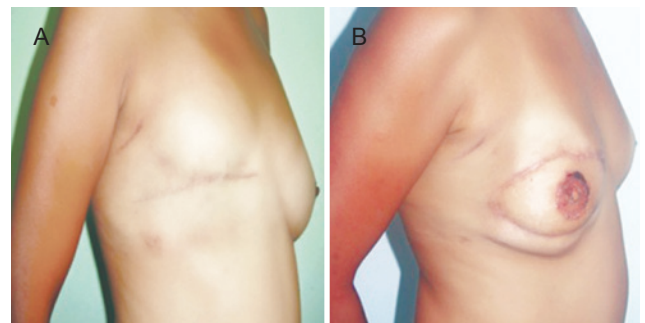


Figure 8 - In A, Preoperative appearance of transverse rectus abdominis muscle (TRAM) flap reconstruction. In B, Postoperative appearance of TRAM flap reconstruction.

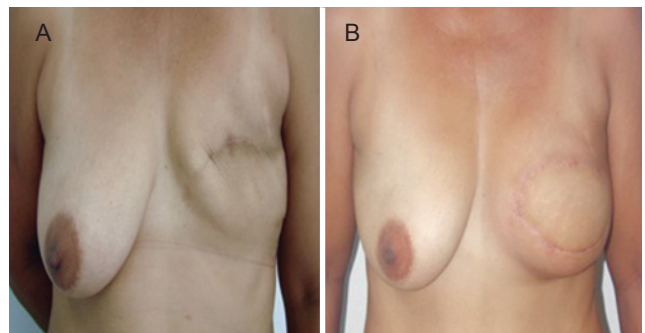


Figure 9 - In A, Preoperative appearance of transverse rectus abdominis muscle (TRAM) flap reconstruction. In B, Postoperative appearance of TRAM flap reconstruction.

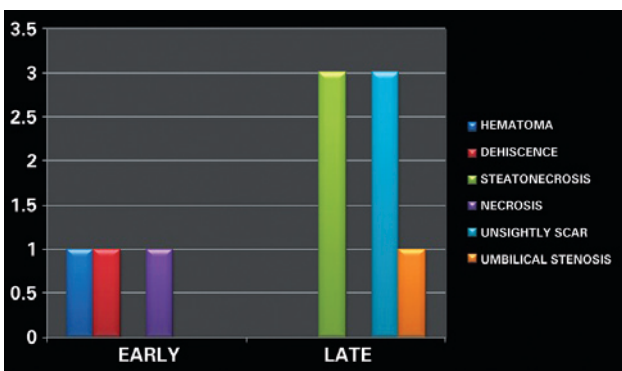


Figure 6 - Complications.

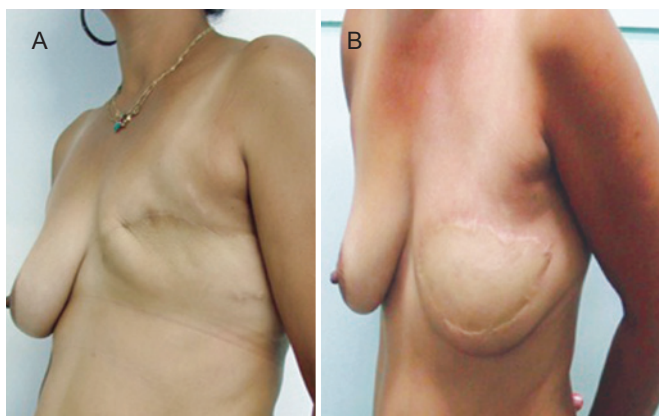


Figure 10 - In *A*, Preoperative appearance of transverse rectus abdominis muscle (TRAM) flap reconstruction. In *B*, Postoperative appearance of TRAM flap reconstruction.

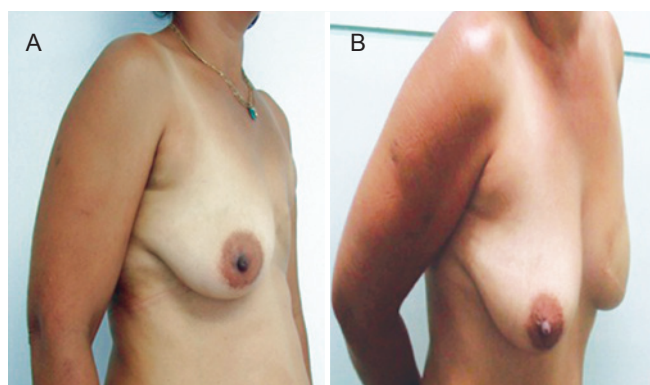


Figure 11 - In *A*, Preoperative appearance of transverse rectus abdominis muscle (TRAM) flap reconstruction. In *B*, Postoperative appearance of TRAM flap reconstruction.

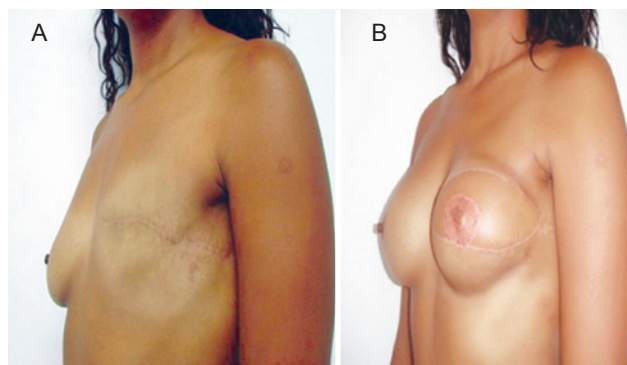


Figure 12 - In *A*, Preoperative appearance of reconstruction with latissimus dorsi flap and symmetrization with implant. In *B*, Postoperative appearance of reconstruction with latissimus dorsi flap and symmetrization with implant.

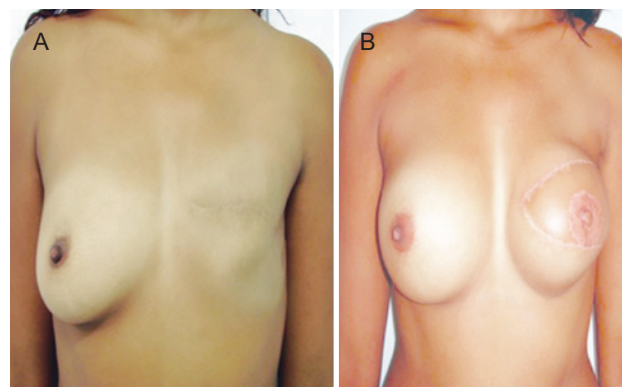


Figure 13 - In *A*, Preoperative appearance of reconstruction with latissimus dorsi flap and symmetrization with implant. In *B*, Postoperative appearance of reconstruction with latissimus dorsi flap and symmetrization with implant.

using autologous flap, whereas the satisfaction scores among the 3 techniques were similar for bilateral reconstructions.

It should be clarified that this study did not aim to compare the results, quality of reconstruction, or complications of the 3 techniques, as only 16 patients were analyzed; instead, this study aimed to verify the importance of breast reconstruction and its positive effects on body awareness, quality of life, and social reintegration of patients.

CONCLUSIONS

Despite the small sample size, we conclude that TRAM flap, latissimus dorsi flap with implant, and the use of tissue expanders with subsequent replacement with silicone implant are effective, with 93.75% and 6.25% of the patients reporting being very and somewhat satisfied with the results, respectively, independent of the technique used, which is consistent with most related literature. Moreover, no serious

complications related to breast reconstructions occurred, which is also in agreement with the literature.

REFERENCES

1. Brasil. Instituto Nacional do Câncer. Controle do câncer de mama: documento de consenso. Rio de Janeiro: INCA; 2004.
2. Brasil. Instituto Nacional do Câncer. Detecção precoce do câncer de mama. Rio de Janeiro: INCA; 2011.
3. Zurrída S, Bassi F, Arnone P, Martella S, Del Castillo A, Ribeiro Martini R, et al. The changing face of mastectomy (from mutilation to aid to breast reconstruction). *Int J Surg Oncol*. 2011;2011:980158.
4. Djohan R, Gage E, Bernard S. Breast reconstruction options following mastectomy. *Cleve Clin J Med*. 2008;75 Suppl 1:S17-23.
5. Andjelkov K, Sforza M, Granic M, Ivanov D, Colic M. Breast reconstruction: correlation between different procedures, reconstruction timing and complications. *Srp Arh Celok Lek*. 2011;139(7-8):470-5.
6. Ananthakrishnan P, Lucas A. Options and considerations in the timing of breast reconstruction after mastectomy. *Cleve Clin J Med*. 2008;75 Suppl 1:S30-3.

7. Veronesi P, Ballardini B, De Lorenzi F, Magnoni F, Lissidini G, Caldarella P, et al. Immediate breast reconstruction after mastectomy. *Breast*. 2011;20 Suppl 3:S104-7.
8. Cordeiro PG. Breast reconstruction after surgery for breast cancer. *N Engl J Med*. 2008;359(15):1590-601.
9. Kalaaji A, Bruheim M. Quality of life after breast reconstruction: comparison of three methods. *Scand J Plast Reconstr Surg Hand Surg*. 2010;44(3):140-5.
10. Craft RO, Colakoglu S, Curtis MS, Yueh JH, Lee BS, Tobias AM, et al. Patient satisfaction in unilateral and bilateral breast reconstruction. *Plast Reconstr Surg*. 2011;127(4):1417-24.

Correspondence to:

Felipe Gama e Colombo
Rua Des. Carlos Xavier Paes Barreto, 35 – ap. 801 – Mata da Praia – Vitória, ES, Brazil – CEP 29065-330
E-mail: fgcol@hotmail.com